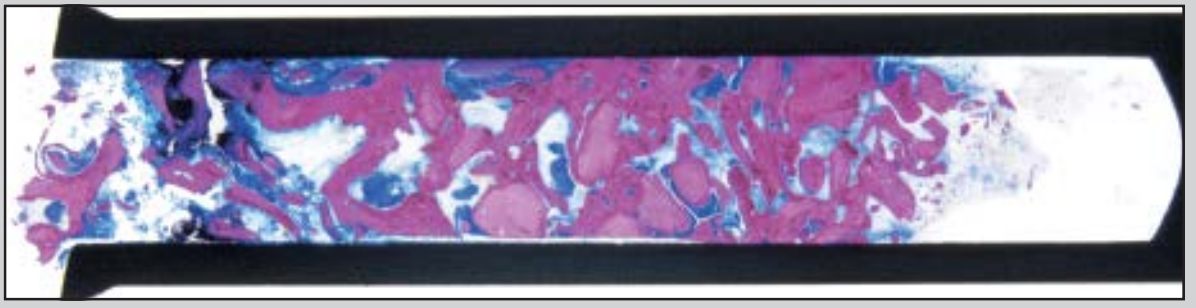

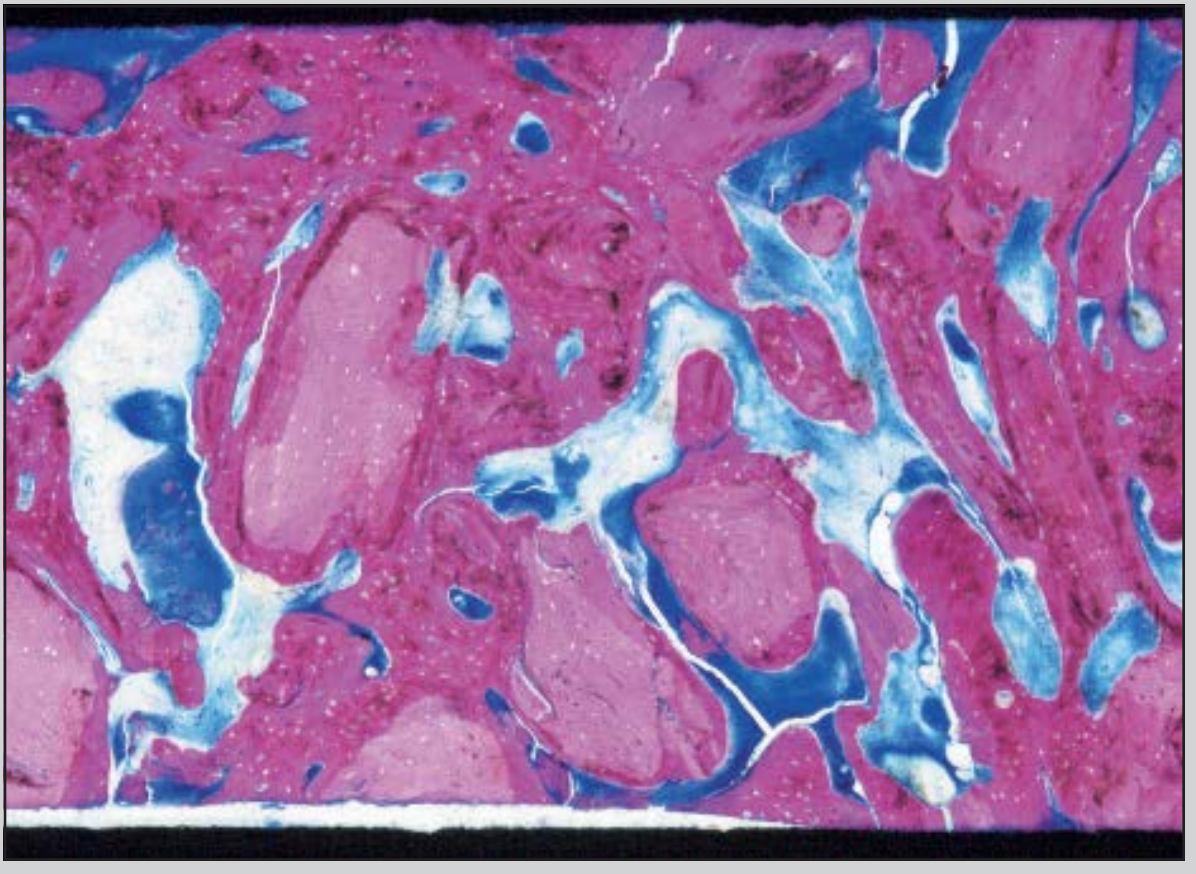

© 2014 BY QUINTESSENCE PUBLISHING CO, INC. PRINTING OF THIS DOCUMENT IS RESTRICTED TO PERSONAL USE ONLY.
NO PART MAY BE REPRODUCED OR TRANSMITTED IN ANY FORM WITHOUT WRITTEN PERMISSION FROM THE PUBLISHER.

The Efficacy of Mineralized Allograft Cortical and Cancellous Chips in Maxillary Sinus Augmentations



Myron Nevins, DDS[1]/Stefano Parma-Benfenati, MD, DDS, DMSc[2]
Ulrich W. Janke, DDS[3]/Aimé Kleyer, DDS, CAGS[4]
Giulio Rasperini, DDS[5]/Carlo Tinti, MD, DDS[6]
Peter Schupbach, PhD[7]/David M. Kim, DDS, DMSc[8]

A mixture of mineralized allograft cortical and cancellous chips was used to augment the maxillary sinuses of 10 patients. Eleven sinus augmentation procedures were performed, and 19 bone cores were obtained at reentry after 6 to 7 months. Computed tomography at 6 months postaugmentation demonstrated bone formation in all sites. Light microscopic and histomorphometric evaluation confirmed bone formation at the treatment site that would receive osseointegrated implants to replace the missing maxillary posterior teeth. These encouraging results support the use of a mixture of mineralized allograft cortical and cancellous chips for sinus augmentation.
(Int J Periodontics Restorative Dent 2014;34:789–793. doi: 10.11607/prd.1720)

[1]Associate Clinical Professor; Division of Periodontology; Department of Oral Medicine, Infection, and Immunity; Harvard School of Dental Medicine; Boston, Massachusetts, USA.
[2]Teaching Professor, Master Program in Periodontology, University of Turin, Turin, Italy.
[3]Private Practice, Hamburg, Germany.
[4]Private Practice, Nice, France.
[5]Aggregate Professor, Unit of Periodontology, Department of Biomedical, Surgical and Dental Sciences, Foundation IRCCS Ca' Granda Polyclinic, University of Milan, Milan, Italy.
[6]Visiting Professor, University of Turin, Turin, Italy.
[7]Associate Professor; Division of Periodontology; Department of Oral Medicine, Infection, and Immunity; Harvard School of Dental Medicine; Boston, Massachusetts, USA.
[8]Schupbach Ltd, Service and Research for Histology, Microscopy, and Imaging; Horgen, Switzerland.

Correspondence to: David M. Kim, Harvard School of Dental Medicine, 188 Longwood Avenue, Boston, MA 02115; fax: 617-432-1897; email: dkim@hsdm.harvard.edu.

©2014 by Quintessence Publishing Co Inc.

Alveolar ridge resorption and sinus pneumatization may occur following extraction of posterior teeth, leading to insufficient bone height and width to place dental implants. Thus, maxillary sinus augmentation procedures allow investigators to test the osteogenic potential of bone graft substitutes to form vital bone in a nonnatural bone-forming area. Several bone graft substitutes as well as modifications of the original sinus elevation technique have been proposed for this procedure to enhance the surgical outcome.[1–3] The transition from autogenous blocks toward allogeneic and xenogeneic particulate bone grafts has resulted in significant success without additional donor site morbidity and complications.[1–3] A review of the literature demonstrates their capabilities to form sufficient bone quality and quantity to accept osseointegrated implants that are capable of withstanding occlusal loading.[1–3]

This investigation evaluated the use of a mixture of mineralized allograft cortical and cancellous chips (50% cortical and 50% cancellous; MinerOss, BioHorizons)

© 2014 BY QUINTESSENCE PUBLISHING CO, INC. PRINTING OF THIS DOCUMENT IS RESTRICTED TO PERSONAL USE ONLY.
NO PART MAY BE REPRODUCED OR TRANSMITTED IN ANY FORM WITHOUT WRITTEN PERMISSION FROM THE PUBLISHER.



Fig 1 *Scanning electron microscopy view of MinerOss graft particles.*

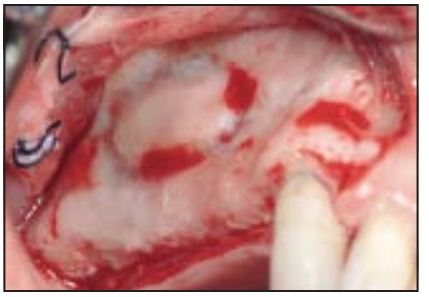

Fig 2 *An oval osteotomy was created on the lateral wall of the sinus. The sinus membrane was gently elevated from the osseous walls of the sinus with hand instrumentation extending to the medial wall of the sinus.*



Fig 3 *The newly created sinus cavity was filled with a mixture of mineralized allograft cortical and cancellous chips until the bone graft was flush with the margins of the osteotomy.*

to augment the atrophic posterior maxillary alveolar process so that dental implants can be placed to restore posterior dentitions. This allogeneic product can serve as an osteoconductive scaffold to provide bone volume enhancement as well as effective site development to receive implants (Fig 1).[4–6] The slower-resorbing cortical component provides structural integrity and space-maintaining capability, while the cancellous chips' porous architecture promotes faster resorption and revascularization, allowing ingrowth of bone-forming cells. The objective of this multicenter clinical trial was to provide evidence of new bone formation and degradability of a mixture of mineralized allograft cortical and cancellous bone chips in maxillary sinus augmentation sites by means of clinical, radiographic, histologic, and histomorphometric analyses.

Method and materials

The study was conducted at five clinical centers for 10 patients (five men and five women, ages 41 to 65 years) in need of 11 sinus enhancement procedures prior to receiving dental implants. No patient presented with any health issues that would contraindicate the proposed buccal lateral window sinus augmentation procedure. The informed consent was reviewed with each patient at a separate consultation appointment, and they signed a consent form based on the Helsinki Declaration of 1975, as revised in 2000, and understood that they had a choice of withdrawing from the procedure at any time. Presurgical periapical radiographs and computed tomography (CT) scans of the maxilla revealed insignificant native alveolar bone height to place implants (less than 6 mm in height). Nine patients required unilateral sinus augmentation procedures, while one patient required a bilateral sinus augmentation procedure.

The osteogenic procedure was carried out under local anesthesia (2% lidocaine with 1:100,000 epinephrine). A mucoperiosteal flap was elevated to expose the buccal wall over the maxillary sinus. An oval osteotomy was performed with a combination of a piezoelectrical device (Piezosurgery, Mectron) together with an electric handpiece and a diamond bur without compromising the sinus membrane (Fig 2). The membrane was then gently elevated from the osseous walls of the sinus with hand instrumentation extending to the medial wall of the sinus. The pouch that was created was then filled with a mixture of mineralized allograft cortical and cancellous chips (MinerOss, 600 to 1,250 μm) that was hydrated with sterile saline for 15 minutes until the bone graft was flush with the margins of the osteotomy (Fig 3). The surgical site was then covered with an absorbable type I collagen membrane (Mem-Lok, BioHorizons) and primary flap closure was obtained with expanded polytetrafluoroethylene sutures (Gore-Tex, W. L. Gore). An antibiotic regimen was implemented (500 mg amoxicillin three times daily for 5 days or 300 mg clindamycin three times daily for 5 days) along with analgesics (800 mg ibuprofen three times daily for 5 days). The patients rinsed twice daily with 0.12% chlorhexidine digluconate

© 2014 BY QUINTESSENCE PUBLISHING CO, INC. PRINTING OF THIS DOCUMENT IS RESTRICTED TO PERSONAL USE ONLY.
NO PART MAY BE REPRODUCED OR TRANSMITTED IN ANY FORM WITHOUT WRITTEN PERMISSION FROM THE PUBLISHER.

solution for 1 week. Appropriate postsurgical instructions were given, and the patients were advised to return in 7 to 10 days for suture removal and wound assessment. They were monitored monthly for the next 6 months.

A postsurgical CT scan was made at 6 months to evaluate the change in bone volume in the sinus (Fig 4). Sinus core biopsy specimens were obtained using a 3-mm trephine bur 6 to 7 months after sinus augmentation, ie, at the time of the implant placement. The bone-loaded trephines were placed in formalin, and the retrieved bone core samples were transferred to a histologist for light microscopy and histomorphometric analysis. All augmented sinus sites received appropriately sized dental implants (Laser-Lok dental implants, BioHorizons).

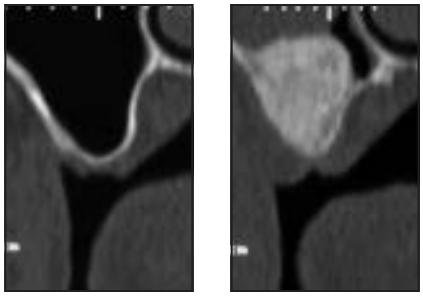

Fig 4 *CT scans obtained prior to augmentation* (left) *and 6 months following sinus augmentation* (right) *demonstrated an increase in radiopaque volume in the sinus.*

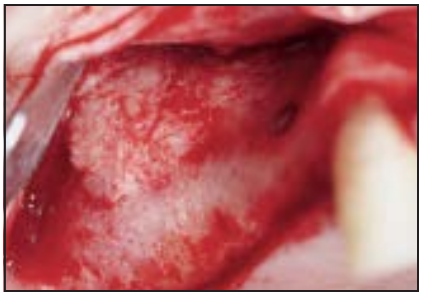

Fig 5 *Mucoperiosteal flap reflection provided evidence of bone fill and formation at the buccal surface osteotomy at 6 to 7 months that was indistinguishable from the neighboring native bone.*



Fig 6a (above) *The grafted sites appeared to be clinically dense.*



Fig 6b (right) *An intact bone core was harvested for light microscope and histomorphometric analysis.*

Light microscopy and histomorphometric analysis

The cores were embedded following complete dehydration in ascending grades of ethanol in a light-curing one-component composite resin (Technovit 7200 VLC, Heraeus Kulzer). Polymerized blocks were initially ground to bring the tissue components closer to the cutting surface. A 100-µm-thick section attached to the second slide was sawed with a diamond blade and 50 to 100 g of pressure. The final thickness of 40 µm was achieved by grinding and final polishing with 1,200-, 2,400-, and 4,000-grit sandpaper. Sections from each block were used for Sanderson rapid bone staining and acid fuchsin counterstaining. Light microscopic overview images of the cores were taken digitally with a Leica M16 stereomicroscope (Leica Microsystems). The percentages of new bone, bone marrow, and graft particles were analyzed using software (ImageAccess, Imagic).

Results

Clinical and CT evaluations

Eleven sinus augmentations were performed for 10 patients. Primary wound closure was obtained in all surgical sites, and no adverse events were observed during the surgical procedures or the healing period. The 6-month postsurgical CT scan demonstrated an increase in density in the radiopaque volume (see Fig 4). Mucoperiosteal flap reflection provided evidence of bone fill and formation at the site of the buccal surface that was indistinguishable from the neighboring native bone (Fig 5). The grafted sites appeared to be clinically dense as they were not penetrable with a periodontal probe (Fig 6a). Nineteen bone cores were obtained

© 2014 BY QUINTESSENCE PUBLISHING CO, INC. PRINTING OF THIS DOCUMENT IS RESTRICTED TO PERSONAL USE ONLY.
NO PART MAY BE REPRODUCED OR TRANSMITTED IN ANY FORM WITHOUT WRITTEN PERMISSION FROM THE PUBLISHER.

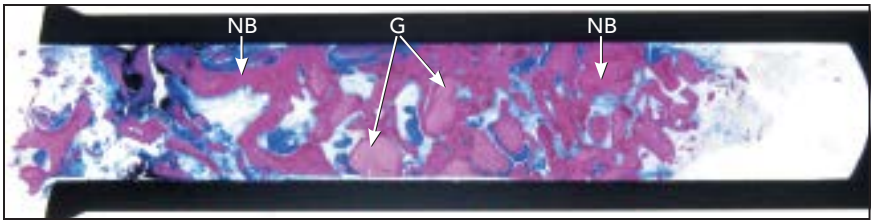

Fig 7 *Ground section of 6-month specimen showing new bone* (NB)*, remaining graft particles* (G)*, and marrow space.*

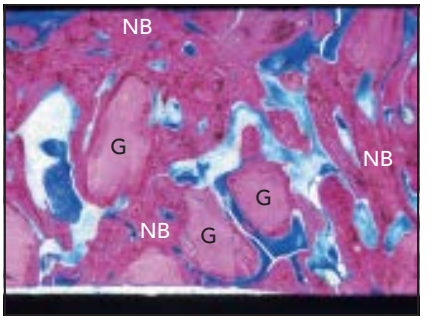

Fig 8 *The biopsy specimens demonstrated a majority of cortical and cancellous chips directly connected with the newly formed bone* (NB) *with very few graft particles* (G) *totally surrounded by the fibrous tissue.*

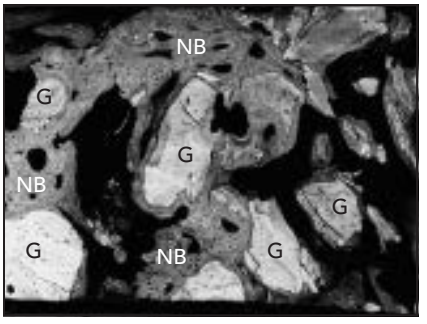

Fig 9 *Backscatter scanning electron microscopy confirming high density of newly formed bone* (NB) *throughout the specimen. G = graft particle.*

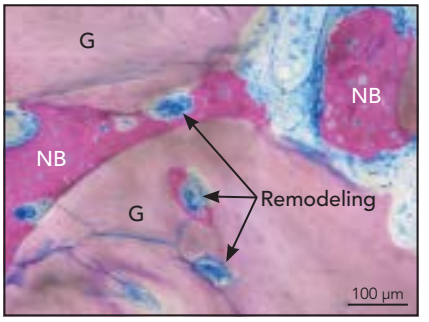

Fig 10 *Physiologic bone remodeling was observed in both newly formed bone* (NB) *and graft particles* (G).

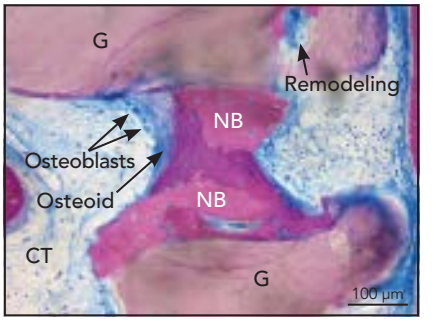

Fig 11 *Osteoblasts seaming an osteoid along newly formed bone* (NB) *indicated ongoing bone formation. CT = connective tissue, G = graft.*

from the grafted site (Fig 6b), and 22 dental implants were placed in bone that was sufficiently dense to withstand osteotomy drilling sequences and were subsequently restored.

Light microscopy and histomorphometric analysis

All specimens showed signs of active bone formation without the presence of inflammatory infiltrates. Very little qualitative difference could be found among biopsy specimens. The host bone displayed more uniform bony structure, whereas the grafted bone had more heterogenous hard tissues.[4] The biopsy specimens demonstrated that the majority of cortical and cancellous chips were directly connected with the newly formed bone; very few graft particles were totally surrounded by the fibrous tissue (Figs 7 to 10). Osteoblasts were present along with newly formed bone around the graft particles (Fig 11).

The measurement of new bone, remaining graft particles, and marrow space/connective tissue was performed. Remaining graft particles were identified by the presence of empty lacunae. The histomorphometric results revealed a mean of 20.83% ± 4.92% new bone formation (range: 15.1% to 26.9%).

Discussion

Various maxillary sinus augmentation techniques as well as bone graft substitutes have been used for osteogenic increases of bone volume in the floor of the maxillary sinus, and the majority of them have demonstrated satisfactory outcomes.[1–3] Nonetheless, long-term clinical success relies on successful graft incorporation, as well as functional remodeling and progressive

© 2014 BY QUINTESSENCE PUBLISHING CO, INC. PRINTING OF THIS DOCUMENT IS RESTRICTED TO PERSONAL USE ONLY.
NO PART MAY BE REPRODUCED OR TRANSMITTED IN ANY FORM WITHOUT WRITTEN PERMISSION FROM THE PUBLISHER.

resorption and replacement of the grafting material by vital bone.[7] Which bone graft substitute is most suitable for sinus augmentation remains a subject of debate.[7]

This study was conducted to find out whether a mixture of mineralized allograft cortical and cancellous chips can serve as a scaffold for the ingrowth of bone-forming cells, allowing replacement and ultimately remodeling of the graft into the host bone. The use of this human allograft for maxillary sinus augmentation was ideal because of its thorough donor screening and unique mechanical and chemical processing that allow preservation of biologic and mechanical properties.

Eleven sinus augmentation procedures were performed on 10 patients. Surgical reentry at 6 to 7 months revealed dense and firm bone resistant enough to receive osteotomy preparation and implant placement. The presence of dense and hard bone at the lateral window sinus osteotomy site indicated mature bone formation that was indistinguishable from neighboring bone. The light microscopy of biopsied specimens demonstrated the majority of cortical and cancellous chips in direct connection with the newly formed bone with very few particles that were totally surrounded by fibrous tissue. Histomorphometric analysis revealed that the quantity of new bone formed appears to be comparable to other sinus augmentation studies using the mixture of mineralized allograft cortical and cancellous chips.[4–6,8–10] For example, an investigation using a mixture of 80/20 cortical and cancellous mineralized allograft in sinus augmentation reported 21% to 31% vital bone formation 6 to 9 months after the sinus augmentation procedures.[8]

The use of a barrier membrane over the grafted area has been advocated because it has been associated with higher implant survival rates.[11] The type I collagen membrane has a predictable resorption time of 26 to 38 weeks and has the macromolecular pore size to allow vital nutrient transfer while the cell occlusive membrane prevents soft tissue ingrowth. This unique property may have prevented the soft tissue invasion into the sinus and enhanced vital bone formation.[1]

Conclusions

A mixture of allograft mineralized cortical and cancellous chips was proven to be a safe and biocompatible material to promote new bone formation for sinus augmentation procedures. This composite graft material was easy to handle and clinically resulted in bone formation that was sufficiently dense to withstand the osteotomy drilling sequences. In addition, light microscopy and histomorphometric evaluation confirmed its osteoconductive properties.

Acknowledgments

This study was sponsored by a grant from Biohorizons. The authors reported no conflicts of interest related to this study.

References

1. Wallace SS, Froum SJ. Effect of maxillary sinus augmentation on the survival of endosseous dental implants. A systematic review. Ann Periodontol 2003;8:328–343.
2. Del Fabbro M, Testori T, Francetti L, Weinstein R. Systematic review of survival rates for implants placed in the grafted maxillary sinus. Int J Periodontics Restorative Dent 2004;24:565–577.
3. Pjetursson BE, Tan WC, Zwahlen M, Lang NP. A systematic review of the success of sinus floor elevation and survival of implants inserted in combination with sinus floor elevation. J Clin Periodontol 2008; 35:216–240.
4. Gapski R, Misch C, Stapleton D, et al. Histological, histomorphometric, and radiographic evaluation of a sinus augmentation with a new bone allograft: A clinical case report. Implant Dent 2008; 17:430–438.
5. Avila G, Neiva R, Misch CE, et al. Clinical and histologic outcomes after the use of a novel allograft for maxillary sinus augmentation: A case series. Implant Dent 2010;19:330–341.
6. Avila G, Wang HL, Galindo-Moreno P, et al. The influence of the bucco-palatal distance on sinus augmentation outcomes. J Periodontol 2010;81:1041–1050.
7. Watzek G, Fürst G, Gruber R. Biologic basis of sinus grafting. In: Jensen OT, ed. The Sinus Bone Graft. 2nd ed. Chicago, IL: Quintessence; 2006:13–26.
8. Maria Soardi C, Spinato S, Zaffe D, Wang HL. Atrophic maxillary floor sinus augmentation by mineralized human bone allograft in sinuses of different size: An histologic and histomorphometric analysis. Clin Oral Implants Res 2011;22: 560–566.
9. Annibali S, Cristalli MP, La Monaca G, et al. Human maxillary sinuses augmented with mineralized, solvent-dehydrated bone allograft: A longitudinal case series. Implant Dent 2011;20:445–454.
10. Kim DM, Nevins ML, Camelo M, et al. The efficacy of demineralized bone matrix and cancellous bone chips for maxillary sinus augmentation. Int J Periodontics Restorative Dent 2009;29:415–423.
11. Tarnow DP, Wallace SS, Froum SJ, Rohrer MD, Cho SC. Histologic and clinical comparison of bilateral sinus floor elevations with and without barrier membrane placement in 12 patients: Part 3 of an ongoing prospective study. Int J Periodontics Restorative Dent 2000;20:117–125.

© 2014 BY QUINTESSENCE PUBLISHING CO, INC. PRINTING OF THIS DOCUMENT IS RESTRICTED TO PERSONAL USE ONLY.
NO PART MAY BE REPRODUCED OR TRANSMITTED IN ANY FORM WITHOUT WRITTEN PERMISSION FROM THE PUBLISHER.