ResearchGate

See discussions, stats, and author profiles for this publication at: https://www.researchgate.net/publication/277087220

GBR using cross-linked collagen membrane and a new highly purified bovine xenograft (Laddec) in horizontal ridge augmentation: Case report of clinical and histomorphometric analysi...

Article *in* Quintessence international (Berlin, Germany: 1985) · May 2015

DOI: 10.3290/j.qi.a34178 · Source: PubMed

CITATION
1

READS
228

3 authors, including:



Renzo Guarnieri
Sapienza University of Rome
45 PUBLICATIONS **277** CITATIONS

SEE PROFILE

All content following this page was uploaded by Renzo Guarnieri on 24 August 2016.

The user has requested enhancement of the downloaded file.

copyright by
All rights reserved



Renzo Guarnieri

GBR using cross-linked collagen membrane and a new highly purified bovine xenograft (Laddec) in horizontal ridge augmentation: Case report of clinical and histomorphometric analysis

Renzo Guarnieri, MD, DDS[1]/Patricia DeVilliers, DDS, MS[2]/Fabrizio Belleggia, MD, DDS[3]

This case report presents the clinical and histologic evaluation of the application of a cross-linked collagen membrane and a new highly purified bovine xenograft with type 1 collagen fiber preservation (Laddec) in mandibular horizontal ridge augmentation on a 50-year-old woman. Significant bone volume was achieved to restore severe bone defect in order to place two implants. Histomorphometric analysis of a bone core at the augmented site, at 6 months, showed new bone formation with bone substitute particles integrated to new viable bone. *(doi: 10.3290/j.qi.a34178)*

Key words: bovine bone-derived biomaterial, cross-linked collagen membrane, horizontal bone augmentation

In recent years, a growing amount of data has reported the effectiveness and predictability of guided bone regeneration (GBR) in promoting vertical and horizontal bone augmentation of ridge deficiencies.[1-10] GBR's principle is based on the application of barrier membranes, excluding epithelial and connective tissues, to enable bone progenitor cell proliferation and differentiation into the affected area.[11,12] Both resorbable and nonresorbable barrier membranes have proven clinical effectiveness.[13] Nonresorbable membranes, mostly made of polytetrafluoroethylene (PTFE), require a second surgical procedure for their retrieval. Therefore, bioresorbable membranes have become a suitable alternative in bone regeneration.[13,14] Several studies have shown that GBR models result in significant regeneration of bone volume without using bone graft materials.[15-17] However, since the space under the barrier must be maintained throughout the healing process, and this space should be of reasonable volume, the use of bone graft material can be beneficial in most clinical scenarios. Graft material acts as a physical support for the barrier preventing its collapse, and it can enhance the quality and quantity of new bone generated by means of osteogenesis, osteoinduction, and/or osteoconduction, depending on the properties of the material used.[18]

Although autografts remain the gold standard for bone grafting applications, technological evolution and better understanding of bone-healing biology has resulted in the development of numerous bone substitutes that offer less potential morbidity. A good alternative for the use of autologous bone is xenogenic bone

[1] Private Implant Periodontal Practice, Rome, Italy; and Freelance Researcher, SCS Scientific Consulting Services, Rome, Italy.

[2] Private Practice, Oral and Maxillofacial Pathology, Pathology Associates of Alabama, Birmingham, AL, USA.

[3] Private Implant Periodontal Practice, Rome, Italy.

Correspondence: Dr Renzo Guarnieri, Private Implant and Periodontics Practice, Via Deserto di Gobi 85 A 2, Rome 00144, Italy.
Email: renzoguarnieri@gmail.com

copyright by
all rights reserved
Quintes



Fig 1 Vestibular view of the right posterior mandibular area showing a thin bone crest.

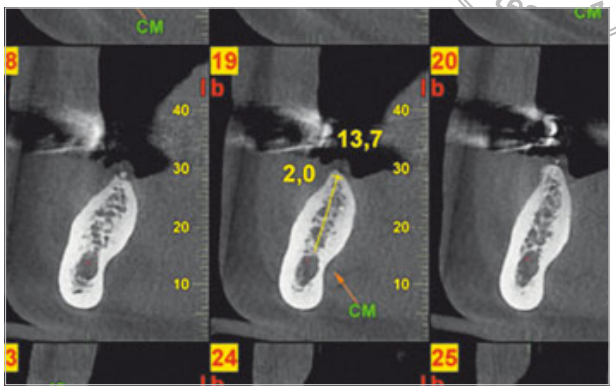

Fig 2 Computed tomograph (CT) scan shows a horizontal, largely resorbed posterior mandibular ridge.

graft.[19] This consists of deproteinized bone that is harvested from one species and transferred to the recipient site of another species. Bovine-derived bone is commonly used, as well as porcine or murine bone.[20-22] Recently, a new highly purified bovine bone graft material characterized by the preservation of type I collagen matrix, associated with spindle-shaped hydroxyapatite crystals (Laddec, BioHorizons) has been brought to the attention of clinicians.[23-25] Unlike other bovine-derived biomaterials commercially available, in which all the organic phase is chemically removed using ethylenediamine treatment and heating, followed by extensive washing and heating below 600°C (US patent 5,167,961), Laddec is obtained from bovine bone after extensive washing with distilled water and phosphate buffer 0.4 mol/L, pH 7.4, followed by defatting at a temperature < 50°C with ethanol/dichloromethane and proteoglycan removal by urea and mercaptoethanol (International patent PCT/WO/91/07194). This process has previously been shown to preserve the mineralized collagen matrix.[20] In addition, high-performance liquid chromatographic (HPLC) analysis has shown that, using this type of process, an amino acids concentration equal to 31% of the sample weight (in particular, glycine, 7.9%; proline, 4%; hydroxyproline, 4.4%; alanine, 3.6%) is maintained. HPLC analysis shows the concentration of the same amino acids (glycine, proline, hydroxyproline, and alanine) in bovine-derived xenograft treated with ethylenediamine and high heating is instead less than 4% of the sample weight.[26,27] The results of the first preclinical studies have suggested that the presence of type I collagen fibers in the matrix of xenografts is crucial to determine cell attachment, as well as spreading and orientation of osteoblasts, as type I collagen can bind osteoblasts via specific cell surface receptors, the integrins.[28-30] The aim of the present study was to perform a histomorphometric analysis in a case of mandibular horizontal bone reconstruction by using cross-linked collagen membrane and Laddec.

CASE PRESENTATION

A 50-year-old woman presented for clinical consultation and treatment, concerning rehabilitation with implant-supported fixed prosthetics, in the posterior right mandible, where the molar teeth were missing (Fig 1). The patient was overall a healthy non-smoker with good oral hygiene habits. She reported that the teeth were extracted several years previously due to pain and mobility. The clinical examination showed severe horizontal ridge defect, which significantly compromised the site regarding implant rehabilitation. Radiographic examination revealed that the bone width in this area was insufficient for standard implant placement (Fig 2). Since the patient preferred a fixed prosthesis rehabilitation with implants, the treatment plan included regeneration of the alveolar defect to ideally restore form, function, and esthetics.

Since this study involves a patient treated as part of routine care using accepted therapy for her specific

doi: 10.3290/j.qi.a34178

copyright by
all rights reserved
Quintessenz

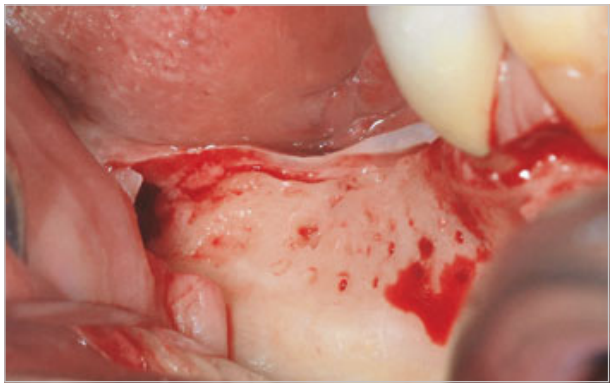

Fig 3 The recipient bone bed has been prepared with multiple decortication holes.

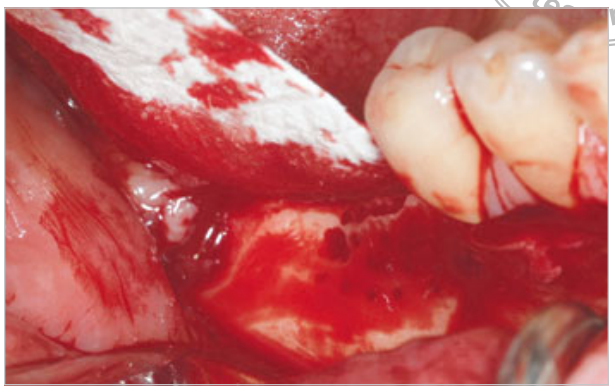

Fig 4 The cross-linked collagen membrane is positioned.

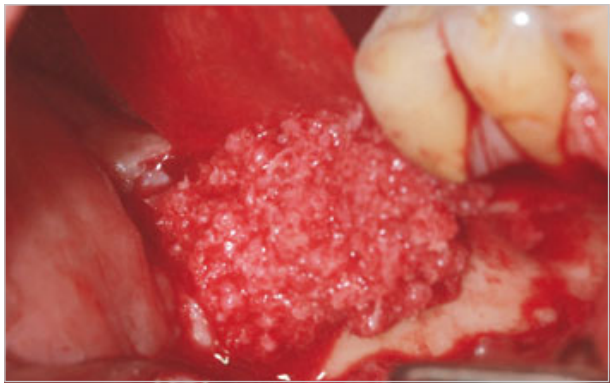

Fig 5 Application of mixture of autogenous particulate bone and Laddec granules.

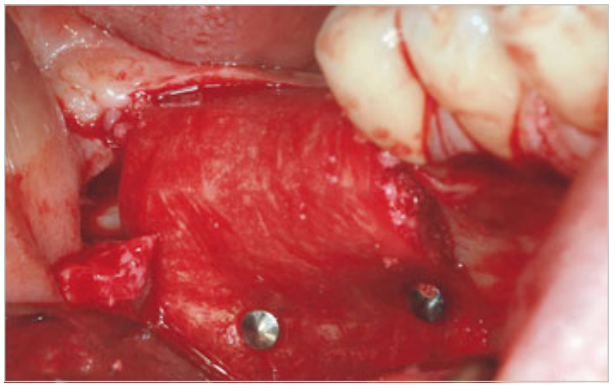

Fig 6 The cross-linked collagen membrane has been secured over the graft with titanium pins.

clinical needs, it did not require approval by an institutional ethics board or committee. Written informed consent was obtained and the study was conducted according to the principles of the Declaration of Helsinki on experimentation involving human subjects.

The surgical technique selection was made in accordance to the protocol established by Urban et al.[10] The patient was prescribed an analgesic (ibuprofen 600 mg immediately after the surgical intervention and after 8 hours), a systemic antibiotic (amoxicillin plus clavulanic acid 1 g twice daily for 7 days), and a chlorhexidine digluconate solution 0.12% rinse (twice daily for 1 minute). Before surgery, the skin surrounding the surgical site was disinfected and a sterile surgical drape was applied. Under local anesthesia (2% lidocaine with 1:80,000 epinephrine), the flap was designed to provide a clear view of the surgical area, and to ensure primary tension-free closure (one midcrestal incision and two divergent vertical releasing incisions). A full-thickness flap was reflected to expose the bone defect, and the recipient site was prepared in order to make it suitable for receiving the graft. After debridement of the connective tissue, numerous perforations were performed in the cortical bone to expose medullar spaces and enhance bleeding (Fig 3). A cross-linked collagen membrane (Mem-Lok, BioHorizons) was shaped so as to allow the complete coverage of the provided volume of the graft, taking care to avoid contact with the edges of the adjacent tooth (Fig 4). Autogenous bone was then harvested from the right ascending ramus and particulated in a bone mill. The autogenous bone was mixed with a new highly purified bovine bone (Laddec, BioHorizons) to form a composite bone graft (Fig 5). The membrane was placed into the defect, folded over, and completely secured (Fig 6). Once the bone graft was immobilized, a flap was positioned to permit tension-

copyright by
all rights reserved
Quinte

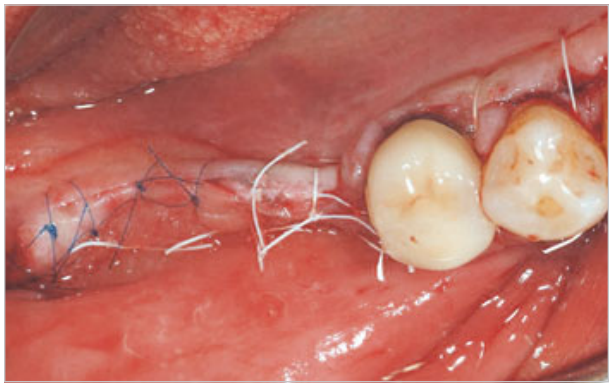

Fig 7 Occlusal view of sutured flaps ensuring primary tension-free wound closure.



Fig 8 Vestibular view 6 months post-surgery.

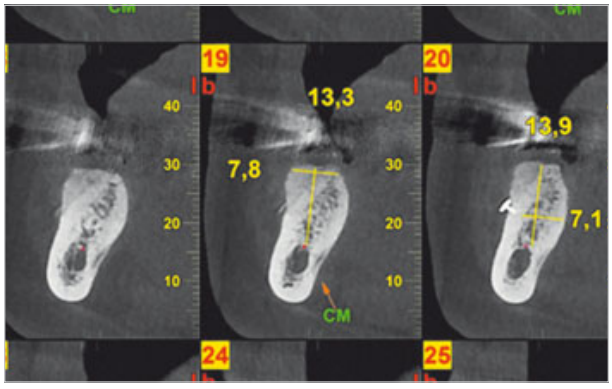

Fig 9 CT scan after 6 months post-surgery showing significant bone volume achieved.

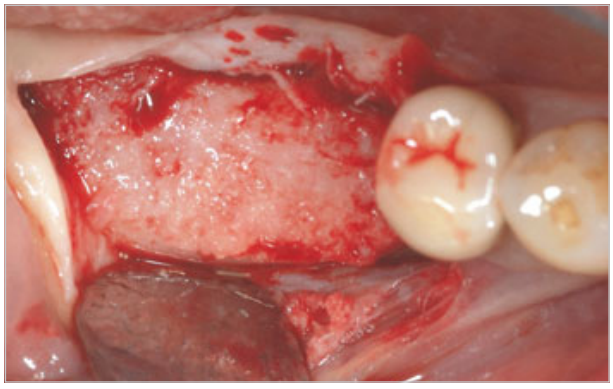

Fig 10 Occlusal view of the regenerated bone.

free primary closure. A periosteal releasing incision connecting the two vertical incisions was performed to achieve elasticity of the flap, and it was then sutured (Fig 7). The sutures were removed 14 days post-surgery.

After 6 months of uneventful healing (Fig 8), the area was surgically explored using the same full-thickness flap design; it showed a healthy periosteal layer between the soft tissue and the bone, and no remnants of the membrane were observed. A complete 5-mm horizontal augmentation was observed (Figs 9 and 10). The two titanium pins were removed and two tapered Laser-Lok BioHorizons implants were placed (Fig 11). At the time of the implant surgery, a bone core was harvested using a 3.5 ×10-mm diameter trephine under cold, sterile saline solution irrigation (Fig 12). The bone specimen was immediately fixed in 10% buffered formalin and processed to be embedded in a glycol methacrylate resin. After polymerization, the specimen was sectioned along its longitudinal axis to a thickness of 7 µm (Leica plastic Microtome, RM 2265). Slides were stained with trichrome (Fig 13), methylene blue (Fig 14), and von Kossa (Fig 15). Slides were examined in an Olympus B51 microscope. The histomorphometry was performed using Bioquant image analysis software (R&M Biometrics) and images were captured with Q-Imaging camera 32-0013B-157, RETIGA, Color 12-bit.

No postoperative complications were present after the grafting procedure and at the time of implant surgery. After 6 months, the radiographic examination showed the presence of bone in the augmented mandibular area (Fig 9). Microscopic examination of the processed bone core specimen showed newly formed bone, in close contact with the xenogenic graft particles. No gaps were found at the bone-graft interface. Most of the graft particles were surrounded by newly formed bone, and in some areas, the graft particles

doi: 10.3290/j.qi.a34178

copyright by
all rights reserved
Quintessenz

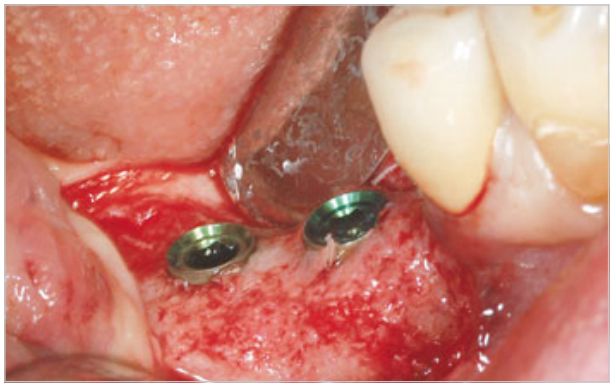

Fig 11 Implant placement.

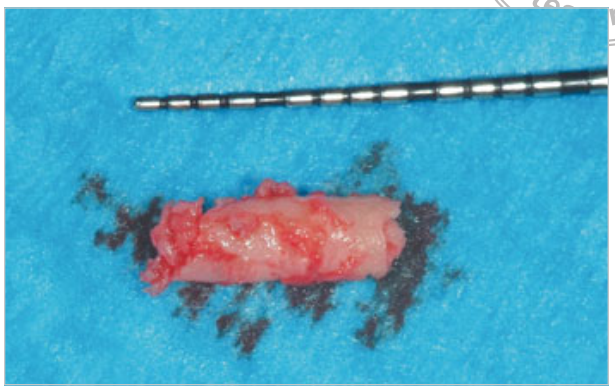

Fig 12 Bone core harvested during the implant bed preparation.

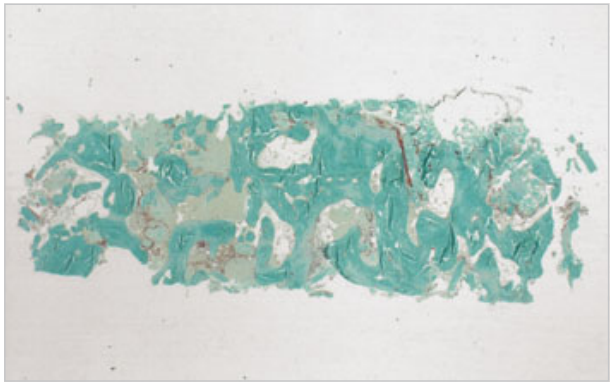

Fig 13 Histologic overview of the non-decalcified bone core (magnification × 12.5, trichrome stain).

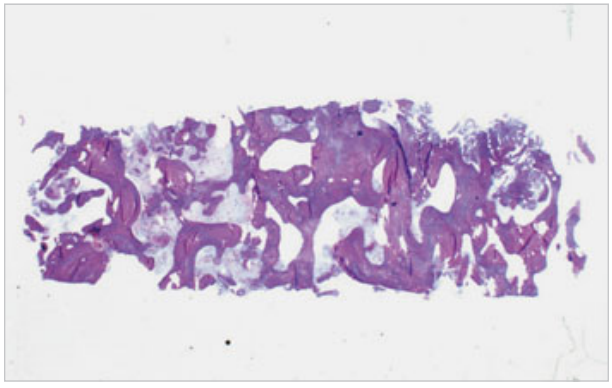

Fig 14 Histologic overview of the non-decalcified bone core (magnification × 12.5, methylene blue and basic fuschin stain).

were in contact with marrow spaces. Also observed was the presence of non-mineralized matrix (osteoid seam) at the interface with the xenographic graft, which was strongly stained by Von Kossa; the osteoid was surfaced by a rim of osteoblasts. The newly formed bone abutting the graft particles showed well-organized lamellae, and numerous lacunae with osteocytes. No acute inflammatory infiltrate or foreign body granulomatous tissue was evident. Histomorphometric data are reported in Table 1.

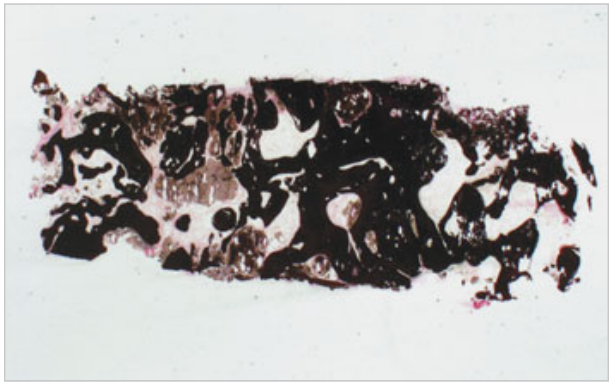

Fig 15 Histologic overview of the non-decalcified bone core (magnification × 12.5, Von Kossa stain).

DISCUSSION

In the reported case, a horizontal bone height increase of about 5.0 mm, 6 months post-surgery, was found. This suggests that Laddec, the highly purified bovine graft material, can be used for bone regeneration in the jaw bones. In addition, histologic examination showed no evidence of acute inflammatory infiltrate, or foreign body granulomatous tissue. This indicates that the processing methodology of Laddec is safe, as the biomaterial does not induce adverse immunologic response. For a graft material to be suitable as a bone

copyright by
all rights reserved
Quintessenz

Table 1	Histomorphometric analysis
Bone/total tissue area (%)	**62.01**
Graft/total tissue area (%)	19.14
Total osteoid area (mm^2)	0.011
Total connective tissue area (mm^2)	0.871
Total bone marrow area (mm^2)	1.265
Total bone surface (mm^2)	82.95
Total osteoid surface (mm^2)	1.711
Osteoid/total bone surface (%)	2.06
Trabecular thickness (μm)	170.3
Trabecular number (mm^{-1})	3.642
Trabecular space (μm)	104.3
Inflammatory cells/total tissue area (%)	1.00

substitute it not only should be biocompatible, non-infectious, and non-antigenic,[31,32] but also should not inhibit the normal activity of bone remodeling.[31] In the present case report, histologic evaluation of the regenerated bone has shown that Laddec is mostly reabsorbed after 6 months, replaced by vital bone, and the residual xenogenic graft particles are integrated to vital bone. Preclinical studies have already shown the capacity of Laddec to stimulate osteoblastic activity,[30,33] facilitating the formation of multiple cell layers,[34] and to increase the expression of alkaline phosphatase in mesenchymal cell cultures.[30]

The importance of preserving collagen matrix in the xenogenic graft material has been previously investigated,[28] comparing two different types of xenogenic bovine bone graft materials, with similar architectural organization, morphologic surface topography and roughness index, but with different chemical composition of their matrices. The first one (Laddec) is characterized by preservation of the mineralized collagen matrix, and the second (Bio-Oss, Geistlich) by complete deproteinization which only preserves the mineral phase. Data reported have demonstrated that osteoblast-like cells cultured at the surface of the two bone xenogenic biomaterials have their orientation mainly influenced by the chemical nature of the underlying surface. At the surface of the collagen-containing matrix, cells exhibited an elongated shape and oriented axis parallel to the underlying collagen bundles. In contrast, at the surface of the single mineral matrix, cells were round shaped with random disposition. Therefore, the presence of collagen fibers in the matrix of a bone xenogenic biomaterial appears to be the major element in determining early cell disposition and perhaps further cell functions such as orientation of new matrix deposition. It is known that type I collagen can influence the adhesion, proliferation, migration, and differentiation of cells at the surface grafted materials, as these activities are related to the ability of membrane receptors to bind molecules of the extracellular matrix.[34] Among the adhesion molecules, integrins are transmembrane αβ heterodimer receptors known to play a key role in these processes.[35-37] In bone, the β1-integrin subunit is known to be shared by several integrins in osteoblast.[38-41] The β1-subunit is involved in adhesion of osteoblast to collagen type I. In the comparative study previously referenced,[28] the β1-integrin subunit was detected and localized with an immunogold method at the transmission electron microscopic level. Results showed that β1-integrin subunit was localized at the outer surface of cells, in close association with mineralized collagen matrix and at the contact points between cells and biomaterials. In contrast, at the surface of the single mineral matrix, cells were round-shaped with random disposition and without association with deproteinized matrix.

In the present case report, a resorbable cross-linked collagen barrier (Mem-Lok), with resorption time of approximately 6 months, was applied over the graft material. The rationale for this application is that the use of a cross-linked collagen membrane results in a barrier of increased area and thickness, compared with the application of a single layer collagen membrane.[42] Cross-linked collagen membranes can reduce bone graft resorption, as membrane degradation starts shortly after implantation.[43] The advantage of using slowly resorbable collagen barrier membranes in GBR techniques is still not clear. However, it has been suggested that a 1-month barrier function time for each millimeter of bone regeneration is needed.[44] Accord-

doi: 10.3290/j.qi.a34178

copyright by
all rights reserved
Quintessenz

ingly, a 5- to 6-month barrier function time should be required for large defects, as treated in the present case report.

CONCLUSION

Analyzing the biocompatible properties of a new highly purified bovine xenograft (Laddec), the clinical and histologic results of the present case report suggest that it could represent a reliable option in oral and maxillofacial surgery. However, further studies or case series are necessary to assess the long-term effectiveness of Laddec and Mem-Lok association in the treatment of horizontal ridge mandibular deficiencies.

ACKNOWLEDGMENT

This work was partially supported by Classimplant, Rome, Italy, and by BioHorizons, Birmingham, AL, USA.

REFERENCES

1. Tinti C, Parma-Benfenati S. Vertical ridge augmentation: surgical protocol and retrospective evaluation of 48 consecutively inserted implants. Int J Periodontics Restorative Dent 1998;18:434–443.
2. Simion M, Jovanovic SA, Tinti C, et al. Long-term evaluation of osseointegrated implants inserted at the time or after vertical ridge augmentation. A retrospective study on 123 implants with 1–5 year follow-up. Clin Oral Implants Res 2001;12:35–45.
3. Merli M, Migani M, Esposito M. Vertical ridge augmentation with autogenous bone grafts: resorbable barriers supported by osteosynthesis plates versus titanium-reinforced barriers. A preliminary report of a blinded, randomized controlled clinical trial. Int J Oral Maxillofac Implants 2007;22:373–382.
4. Donos N, Mardas N, Chadha V. Clinical outcomes of implants following lateral bone augmentation: systematic assessment of available options (barrier membranes, bone grafts, split osteotomy). J Clin Periodontol 2008;35:173–202.
5. Langer B, Langer L, Sullivan RM. Vertical ridge augmentation procedure using guided bone regeneration, demineralized freeze-dried bone allograft, and miniscrews: 4- to 13-year observations on loaded implants. Int J Periodontics Restorative Dent 2010;30:227–235.
6. Beitlitum I, Artzi Z, Nemcovsky CE. Clinical evaluation of particulate allogeneic with and without autogenous bone grafts and resorbable collagen membranes for bone augmentation of atrophic alveolar ridges. Clin Oral Implants Res 2010;21:1242–1250.
7. Kuchler U, von Arx T. Horizontal ridge augmentation in conjunction with or prior to implant placement in the anterior maxilla: a systematic review. Int J Oral Maxillofac Implants 2014;29(Suppl):14–24.
8. Hämmerle CH, Jung RE, Yaman D, Lang NP. Ridge augmentation by applying bioresorbable membranes and deproteinized bovine bone mineral: a report of twelve consecutive cases. Clin Oral Implants Res 2008;19:19–25.
9. Urban IA, Nagursky H, Lozada JL, Nagy K. Horizontal ridge augmentation with a collagen membrane and a combination of particulated autogenous bone and anorganic bovine bone-derived mineral: a prospective case series in 25 patients. Int J Periodontics Restorative Dent 2013;33:299–307.
10. Urban IA, Nagursky H, Lozada JL. Horizontal ridge augmentation with a resorbable membrane and particulated autogenous bone with or without anorganic bovine bone-derived mineral: a prospective case series in 22 patients. Int J Oral Maxillofac Implants 2011;26:404–414.
11. Nyman S, Gottlow J, Lindhe J, Karring T, Wennstrom J. New attachment formation by guided tissue regeneration J Periodontal Res 1987;22:252–254.
12. Dahlin C, Sennerby L, Lekholm U, Linde A, Nyman S. Generation of new bone around titanium implants using a membrane technique: an experimental study in rabbits. Int J Oral Maxillofac Implants 1989;4:19–25.
13. Moses O, Pitaru S, Artzi Z, Nemcovsky CE. Healing of dehiscence-type defects in implants placed together with different barrier membranes: a comparative clinical study. Clin Oral Implants Res 2005;16:210–219.
14. Simion M, Masitano U, Salvato A. Treatment of dehiscences and fenestration around dental implants using resorbable and non-resorbable membranes associated with bone autografts: a comparative clinical study. Int J Oral Maxillofac Implants 1997;12:159–167.
15. Stavropoulos A, Kostopoulos L, Mardas N, Nyengaard JR, Karring T. Deproteinized bovine bone used as an adjunct to guided bone augmentation: an experimental study in the rat. Clin Implant Dent Relat Res 2001;3:156–165.
16. Stavropoulos A, Kostopoulos L, Nyengaard JR, Karring T. Deproteinized bovine bone (Bio-Oss) and bioactive glass (Biogran) arrest bone formation when used as an adjunct to guided tissue regeneration (GTR): an experimental study in the rat. J Clin Periodontol 2003;30:636–643.
17. Pinholt EM, Bang G, Haanaes HR. Alveolar ridge augmentation in rats by Bio-Oss. Scand J Dent Res 1991;99:154–161.
18. Simion M, Baldoni M, Rossi P, Zaffe D. A comparative study of the effectiveness of e-PTFE membranes with and without early exposure during the healing period. Int J Periodontics Restorative Dent 1994;14:166–180.
19. Hammer C, Linke R, Wagner F, Diefenbeck M. Organs from animals for man. Int Arch Allergy Immunol 1998;116:5–21.
20. Block JE, Poser J. Does xenogeneic demineralized bone matrix have clinical utility as a bone graft substitute? Med Hypotheses 1995;45:27–32.
21. Jensen SS, Aaboe M, Pinholt EM, Hjorting-Hansen E, Melsen F, Ruyter IE. Tissue reaction and material characteristics of four bone substitutes. Int J Oral Maxillofac Implants 1996;11:55–66.
22. LeGeros RZ. Properties of osteoconductive biomaterials: calcium phosphates. Clin Orthop Relat Res 2002;395:81–98.
23. Hofman S, Sidqui M, Abensur D, Valentini P, Missika P. Effects of Laddec on the formation of calcified bone matrix in rat calvariae cells culture. Biomaterials 1999;20:1155–1166.
24. Chappard D, Zhioua A, Grizon F, Basle MF, Rebel A. Biomaterials for bone filling: comparisons between autograft, hydroxyapatite and one highly purified bovine xenograft. Bull Assoc Anat (Nancy) 1993;77(239):59–65.
25. Poumarat G, Squire P. Comparison of mechanical properties of human, bovine bone and a new processed bone xenograft. Biomaterials 1993;14:337–340.
26. Holmes RE, Bucholz RW, Mooney V. Porous hydroxyapatite as a bone graft substitute in diaphyseal defects: A histometric study. J Orthop Res 1987;5:114–121.
27. Chappard D, Fressonnet C, Genty C, Baslé MF, Rebel A. Fat in bone xenografts: importance of the purification procedures on cleanliness, wettability and biocompatibility. Biomaterials 1993;14:507–512.
28. Baslè MF Grizon F, Pascaretti C, Lesourd M, Chappard D. Shape and orientation of osteoblast-like cells (Saos-2) are influenced by collagen fibers in xenogenic bone biomaterial. J Biomed Mater Res 1998;40:350–357.
29. Baslé MF, Lesourd M, Grizon F, Pascaretti C, Chappard D. Type I collagen in xenogenic bone material regulates attachment and spreading of osteoblasts over the beta1 integrin subunit. Orthopade 1998;27:136–142.
30. Pappalardo S, Guarnieri R. In vitro osteogenic differentiation of mesenchymal stem cells on an highly purified bovine xenograft (Laddec®). J Biomater Tissue Eng 2013;3:1–5.
31. Yamada S, Heymann D, Bouler JM, Daculsi G. Osteoclastic resoprtion of calcium phosphate ceramics with different hydroxyapatite/tricalcium phosphate ratios. Biomaterials 1997;18:1037–1041.

copyright by
all rights reserved
Quintessenz

32. Taylor JC, Cuff SE, Leger JP, Morra A, Anderson GI. In vitro osteoclast resorption of bone substitute biomaterials used for implant site augmentation: a pilot study. Int J Oral Maxillofac Implants 2002;17:321–330.
33. Barbanti BG, Mazzoni E, Tognon M, Griffoni C, Manfrini M. Human mesenchymal stem cells and biomaterials interaction: a promising synergy to improve spine fusion. Eur Spine J 2012;21:S3.
34. Legeros RZ, Craig RG. Strategies to affect bone remodeling: osteointegration. J Bone Miner Res 1993;8:S583–S596.
35. Hemler ME. Integrins. In: Kreis T, Vale R (eds). Extracellular Matrix and Adhesion Proteins. Oxford: Oxford University Press, 1993:143–145.
36. Hynes RO. Integrins: A family of cell surface receptors. Cell 1987;48:549–554.
37. Ruoslahti E. Integrins. J Clin Investig 1991;87:1–5.
38. Clover J, Dodds RA, Gowen M. Integrin subunit expression by human osteoblasts and osteoclasts in situ and in culture. J Cell Sci 1992;103:267–271.
39. Gohel AR, Hand AR, Gronowicz GA. Immunogold localization of b1-integrin in bone: Effect of glucocorticoids and insulin-like growth factor I on integrins and osteocyte formation. J Histochem Cytochem 1995;43:1089–1096.
40. Hughes DE, Salter DM, Dehdar S, Simpson R. Integrin expression in human bone. J Bone Miner Res 1993;8:527–533.
41. Zambonin-Zallone A, Teti A, Grano M, et al. Immunocytochemical distribution of extracellular matrix receptors in human osteoclasts: αβ integrin is colocalized with vinculin and talin in the podosome of osteoclastoma giant cells. Exp Cell Res 1989;182:645–652.
42. Kozlovsky A, Aboodi G, Moses O, et al. Bio-degradation of a resorbable collagen membrane (Bio-Gides) applied in a double-layer technique in rats. Clin Oral Implants Res 2009;20:1116–1123.
43. von Arx T, Broggini N, Storgärd Jensen S, Bornstein MM, Schenk RK, Buser D. Membrane durability and tissue response of different bioresorbable barrier membranes: a histologic study in the rabbit calvarium. Int J Oral Maxillofac Implants 2005;20:843–853.
44. Smiler D, Soltan M. The bone-grafting decision tree: a systematic methodology for achieving new bone. Implant Dent 2006;15:122–128.

doi: 10.3290/j.qi.a34178

View publication stats