Received: 23 June 2018 | Accepted: 5 October 2018

DOI: 10.1111/cid.12693

WILEY

ORIGINAL ARTICLE

# Influence of restorative margins position on one-stage laser-microgrooved implants-supported single screwed crowns: A clinical, biochemical, and microbiological analysis

**Renzo Guarnieri MD, DDS** | **Dario Di Nardo DDS, PhD** | **Gianfranco Gaimari DDS, PhD** | **Gabriele Miccoli DDS, PhD** | **Luca Testarelli DDS, PhD**

Department of Dental and Maxillofacial Sciences, School of Dentistry, University La Sapienza, Rome, Italy

**Correspondence**
Renzo Guarnieri, Department of Dental and Maxillofacial Sciences, School of Dentistry, University La Sapient, Roma. Private Practice, via L. Cattarin 3D Treviso, Italy.
Email: renzoguarnieri@gmail.com

**Funding information**
BioHorizons

## Abstract

**Aim:** To clinically, biochemically, and microbiologically evaluate the influence of crown margins position on one-stage laser-microgrooved implants.

**Materials and Methods:** Twenty-one-stage titanium implants with a laser-microgrooved collar surface, supporting screwed, single crown restorations, were placed in 20 partially edentulous patients and evaluated. Clinical parameters included modified plaque index, modified gingival index, peri-implant probing pocket depth, bleeding on probing, and distance between implant shoulder and mucosal margin. The parameters were recorded at baseline (crowns delivery) and at every 6-month recall visit, until the end of the 3 years follow-up period. At the same time intervals, radiographic marginal bone levels were assessed at the mesial and distal aspect of the implant sites. For biochemical analysis, the volume of the peri-implant sulcus fluid, and its levels of interleukin-1beta (IL-1β), interleukin-6 (IL-6), and of tumor necrosis factor-α, were utilized to evaluate the peri-implant health conditions at the end of the 3-year follow-up period. At the same time, microbiological analysis, including the concentration of five putative periodontal pathogens (*Aggregatibacter actinomycetemcomitans*, *Porphyromonas gingivalis*, *Prevotella intermedia*, *Treponema denticola*, and *Tannerella forsythensis*), were assessed. The crown margins positions were classified into four groups (A = intracrevicular position >2 mm, B = intracrevicular position ≤2 mm/<1 mm, C = intracrevicular position ≤1 mm/<0 mm, and D = extracrevicular position), and the biochemical, and microbiological parameters were evaluated at 3 years.

**Results:** No statistical differences of clinical and biochemical parameters were found between the four groups. In group A, compared to groups B, C, and D, a statistically significant higher concentration of putative periodontal pathogens was found.

**Conclusions:** Results showed that the intracrevicular deeper position of the restoration margin does not influence the clinical and biochemical peri-implant parameters. The deeper position of the crown margin is associated with a greater amount of putative periodontal pathogenic microflora colonization.

KEYWORDS

crown margins position, laser-microgrooves collar surface, one-stage implant

## 1 | INTRODUCTION

In addition to the functional outcome, the esthetic outcome is an equally important key of success of the modern dental implant therapy. From the esthetic point of view, the success is not only bound to the long-term peri-implant soft tissue stability, involving the presence of papilla, and the alignment of the gingival margin in harmony with the implants crown, but, especially in frontal areas, implant-supported restorations should not even be distinguished from the natural dentition.[1]

 © 2018 Wiley Periodicals, Inc. 

One of current clinical recommendations for esthetic implant-supported crown restorations indicates that the one-stage implant shoulder should be positioned 1-2 mm more apically to the labial cement-enamel junction of the adjacent teeth.[2,3] This allows to hide the abutment-crown interface, achieve more natural emergence profile, and accommodate possible peri-implant tissue recession with time. However, as the implant shoulder does not match the scalloped cement-enamel junction design of adjacent teeth, the interproximal crown margins are often located several millimeters submucosally, and are thus difficult to reach during the patient's routine oral hygiene efforts.[4] There is general agreement that, around natural teeth, the maintenance of a healthy periodontium is related to the position of restorative margins' position.[5] Several studies have shown that restorative margins placed subgingivally risk invading the attachment apparatus.[5–12] Moreover, subgingival crown margins were found to be associated with more spirochetes, fusiforms, rods, and filamentous bacteria, and with an increased plaque and gingival index scores, and probing depths.[13]

Despite the mentioned risks, some factors including esthetic needs, increased retention form, refinement of preexisting margins, root caries, cervical abrasion, and root sensitivity, may direct the clinician to place the restoration subgingivally. However, if none of these factors is present, it is more prudent to place the restorative margins supragingivally.[5]

A combination of clinical and radiographic parameters are commonly used for the diagnostic assessment of peri-implant tissue health. They are indicative of a well-established peri-implant tissue inflammatory response but do not provide sufficient information to locate the inflammation progression site.[14] Likewise, the gingival crevicular fluid (GCF), the peri-implant sulcus fluid (PISF) is an osmotically mediated transudate/exudate, which tends to increase during the inflammatory process.[15] Several reports suggested that the volume of PISF and levels biomarkers such as, the interleukin-1beta (IL-1β), the interleukin-6 (IL-6), and the tumor necrosis factor (TNF)-α, could be relevant for the early diagnosis of peri-implant tissue inflammation.[16,17]

The specific plaque hypothesis suggests that certain oral bacteria play critical roles in the initiation and progression of both periodontal,[18] and peri-implant inflammation.[19] Despite the fact that recent studies indicated that peri-implant and periodontal microbiomes represent microbiologically distinct ecosystems,[20–22] and that the host response plays a crucial role in initiation/progression of the inflammation process,[23] the assessment of the levels of periodontitis-associated bacteria may, however, determine whether the deeper location of restoration margins is a predisposing condition of colonization by such bacteria, and therefore, in the susceptible host, is a condition of higher risk to develop a peri-implant inflammation.

To the authors' knowledge, only few data have been published about the influence of restorative crown margins location on the maintenance of peri-implant health conditions.[23–25] Therefore, the present study was designed to evaluate the influence of the crown margins position on the peri-implant tissue health status around one-stage implants supporting screw retained single restorations. For this purpose, in addition to clinical and radiographic parameters, the following biochemical and microbiological parameters were used: volume of PISF, PISF levels of IL-1β, IL-6, and TNF-α, and concentration in PISF of *A. actinomycetemcomitans*, *Porphyromonas gingivalis*, *Prevotella intermedia*, *Treponema denticola*, and *Tannerella forsythensis*.

## 2 | MATERIALS AND METHODS

### 2.1 | Patients

Twenty partially edentulous patients (10 males and 10 females, mean age 44.6 years), requiring implant therapy for a prosthetic rehabilitation participated to this study. Patients were included if they were 18 years or older, in good general health, and with sufficient amount of bone available to place a standard implant (3.8 mm diameter and 9 mm length) detectable by means of CBCT evaluation. None of the recruited patients had received antibiotics in the last 4 months prior to the 3-year examination. Exclusion criteria were: natural teeth adjacent to surgical area affected by untreated periodontal or endodontic infections, peri-implant bone defects requiring bone augmentation, absence of opposing occlusion, full-mouth plaque score ≥25%; full-mouth bleeding score ≥25% recorded at the time of implant placement, para-functional habits, severe maxilla-mandibular space discrepancies, uncontrolled diabetes and treatment with bisphosphonates, patients smoking >10 cigarettes a day, and any drug/alcohol abuse. Each patient was informed about the evidence based, positive outcome of implant treatment, and signed a free informed consent form after he/she has received detailed information about the study. Treatments were performed according to the principles outlined in the Declaration of Helsinki on experimentation involving human subjects. The study was approved by the Research Ethics Committee of the La Sapienza University of Rome (#4597).

### 2.2 | Implants

Twenty one-stage Tissue Level Laser-Lok implants (BioHorizons, Birmingham, Alabama) implants were inserted by the same surgeons (R.G. and L.T.), using the same one-stage protocol in accordance with recommendations of the manufacturer, and with surgical procedures suggested for the one-stage implant placement in partially edentulous patients The implants have the body grit-blasted to create a moderately rough surface, while the apical 2.0 mm of the collar are characterized by the presence of laser-produced microgrooves in the range of 8 μm, and the most coronal 1.3 mm of the collar is smooth, machined metal.

All implants were inserted with the rough/microgrooved border placed flush to the bone crest, and the 2 mm of laser-microgrooved surface over the bone crest.

### 2.3 | Clinical examination

The clinical evaluation was performed by one clinician (R.G.) and included measurement of probing pocket depth (PPD) and assessments of the modified plaque index (mPI),[26] of the gingival index (GI),[27] and the presence or absence of bleeding on probing (BOP). Moreover, the distance between the implant coronal margin and the mucosal margin (DIM), was measured. In presence of a supragingival implant coronal margin the measurement was recorded as negative value. The DIM measurement, which corresponds to the level of intra/extrasulcular

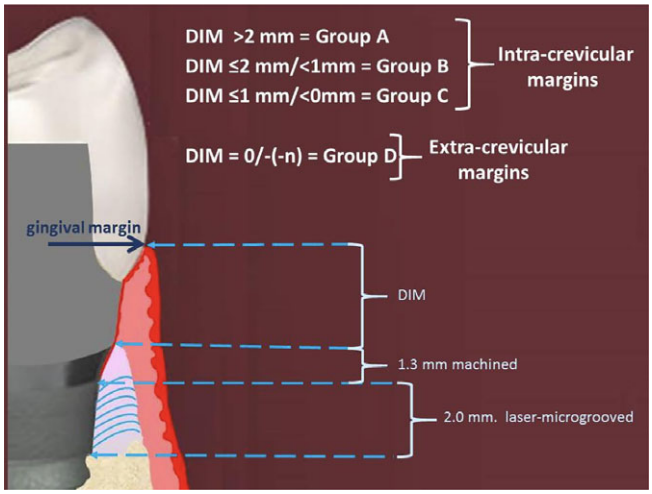


**FIGURE 1** Schematic illustration or measurements used to assess the crown margin position

crown margins position, was used to divide the implant-supported restorations in four groups: group A = intracrevicular position with DIM >2 mm; group B = intracrevicular position with DIM ≤2 mm/<1 mm; group C = intracrevicular position with DIM ≤1 mm/<0 mm; and group D = extracrevicular position with DIM = 0/−*n*), (Figure 1). Clinical measurements were performed at four sites around each implant and were carried out to the nearest mm using a Hu-Friedy specific periodontal probe with 2 mm colored tip (Figure 2). All clinical evaluations were assessed at baseline (crown delivery) and at each 6-month examination, until the end of the follow-up period. All the implant-supported restoration were screw retained single crowns.

## 3 | PISF SAMPLING AND BIOCHEMICAL ANALYSIS

The PISF was collected with standardized paper strips (Periopaper, Proflow, Amityville, New York) at the 3-year examination. Following the isolation of the sampling area with sterile cotton gauzes, accurate suction was performed and experimental sites were gently air dried to reduce any possible contamination with saliva. Supragingival plaque



**FIGURE 2** Example of the technique used to measure the distance between the implant coronal margin and the mucosal margin (DIM). The measurement of color tip of the probe is standardized at 2 mm

was removed with teflon or plastic curettes for implant maintenance. Extreme care was taken to minimize mechanical irritation during PISF sampling because this is known to affect the actual fluid volume. Two paper strips were placed at each sampling site at the same time (mesially and distally), and were left in situ for 30 s. Paper strips contaminated by blood were excluded. To eliminate the risk of evaporation, paper strips with PISF were immediately transported to previously calibrated, switched on and allowed to warm up. Periotron 8000 (Ora Flow, Inc, Plainview, New York) was used for volume quantification. Before volume measurement, a blank paper strip was placed in the device and the reading dial was set to zero. To increase reliability, the calibration of the device was checked periodically by triplicate readings. The PISF was measured electronically in Periotron units, which were converted to microliters (μL) by MCCONVRT software (Ora Flow).

For the biochemical analysis, the paper strips were placed in a single Eppendorf vial containing 100 μL phosphate-buffered saline and stored at −80°C. Interleukins IL-1β, IL-6, and TNF-α were quantified (pg/mL), by enzyme-linked immunosorbent assay (ELISA) kits, following the procedures recommended by the manufacturer (Duoset kit; R&D,Minneapolis, Minnesota). The standard solution and samples were added to wells, which had been precoated with specific monoclonal capture antibodies. After 3 hours, polyclonal antibodies conjugated with horseradish peroxidase were added to each well and incubated for 1 hour. A substrate solution containing hydrogen peroxidase and chromogen was added and allowed to react for 20 minutes. The biomarkers levels were assessed by a micro-ELISA reader (Ultramark, Bio-Rad, California) at 450 nm and normalized to the abundance of standard solution. All biochemical analyses were performed by a blinded researcher.

### 3.1 | Microbiological analysis

The microbiological analysis was performed at the 3-year follow-up examination, by means of real-time polymerized chain reaction (RT-PCR) technique using Carpegen Perio Diagnostics Test (Carpegen GmbH, Münster, Germany) according to the instructions of the manufacturer. Sampling areas were treated as described for PISF sampling and biochemical analysis. Paper points were inserted in four different sites for each implant included in the study (buccal, mesio and disto buccal, lingual). The article points were removed after 30 seconds with careful attention not to touch the oral mucosa and coronal surfaces. The points were then dropped in plastic sterile falcon tubes. The RT-PCR analysis was consequently assessed to test the quantitative and qualitative presence of the following pathogens using species-specific probes: *A. actinomycetemcomitans*, *Porphyromonas gingivalis*, *Prevotella intermedia*, *Treponema denticola*, and *Tannerella forsythensis*. Results were expressed in Genome Equivalents (Geq)/mL x $10^3$.

### 3.2 | Radiograph examination

Radiographs were performed immediately at implant placement (T0), at the delivery of definitive crowns 4/6 months after surgery (T1), and 3 years after loading (T3), with a paralleling technique using a Rinn film holder with a rigid film-object x-ray source. For the radiograph

procedure, a silicone index material was fixated to the residual dentition and a radiograph holder was constructed for each patient. This technique ensured that the same position of the radiograph film could be reproduced at each visit and the angle of the radiograph would not deviate. The radiographs were taken in high resolution mode (Vista Scan Durr Dental, Durr Dental Italy S.r.l) with a dental x-ray machine (TM 2002 Planmeca Proline CC, Planmeca Group Helsinki, Finland) equipped with a long tube that operated at 70 Kw/7.5 mA. Specialized software (DBSWIN software, Durr Dental Italy S.r.l) was used for linear measurements of marginal bone changes. The following radiographic measurements were performed:

- Radiographic implant length (IL): distance (in mm) between the implant coronal margin and the implant apex as assessed at the mid portion of the implant;
- Residual bone height at the mesial (MI) and distal (DI) aspects of the implant: distance (in mm) between the line linking the coronal implant margin, and the first contact of the crestal bone on both mesial and distal side of the implant.

To account for radiographic distortion, radiographic measurements on each radiograph were adjusted for a coefficient derived from the ratio: true length of the implant/IL. All measurements were carried out by a single trained examiner who had previously undergone a calibration session for radiographic assessment on a sample of five patients treated with the same implant system and not included in the study (Kappa test = 0.9550, SE of kappa = 0.048, 95% confidence interval: from 0.862 to 1.000).

### 3.3 | Statistical analysis

A public domain online software (Raosoft, http://www.raosoft.com/samplesize.html) was used to calculate the minimal number necessary for statistical evaluation. Data were analyzed using SPSS software version 13.0 (Chicago, Illinois).

Mean values and standard deviations (mean ± SD) were calculated for each considered parameter. The normal distribution of error terms and the validity of the model's assumptions were assessed using a QQ- plot. One-sided *P*-values were calculated, and corrected according to Sidak's method for multiple hypothesis testing. Data were analyzed by means of Mann-Whitney test and by repeated-measure analysis of variance (ANOVA). The Bonferroni test was applied for the pairwise comparison. A *P* value <.05 was considered statistically significant. Results of the linear mixed effects were used to calculate the estimates of the differences between groups and their 95% confidence intervals.

### 3.4 | Clinical results

No patients dropped out within the follow-up period. Thus, 20 implants in 20 subjects were evaluated. After 3 years of loading the cumulative survival rate was 100%. A mPI value of 3, 2, 1, and 0, was recorded in 0%, 5%, 16%, and 79% of 80 implant sites, respectively. Eighty-five % of sites presented a bleeding score of 0, while in 10.8%, 4.2%, and 0% of sites the bleeding score was 1, 2, and 3, respectively. The mean probing depth value before, and 3 years after of loading, was 2.02 mm ± 0.4 and 2.04 mm ± 0.3. At the baseline, six implants sites showed a mean DIM value of 2.1 mm, five implants a mean value of 1.6, four implants a mean value of 0.7, and five implants a mean value of 0/−0.5. Accordingly, at the baseline, six restorative crowns margins presented an intracrevicular position of >2 mm (group A), five restorative crowns margin an intracrevicular position of ≤2 mm/<1 mm (group B), four restorative crowns margin an intracrevicular position of ≤1 mm/<0 mm (group C), and five restorative crowns margins an extracrevicular position (group D). Before implants loading, the mean DIM value was 0.7 mm, while 3 years after loading was 0.9 mm. No statistically significant variations were found in DIM between the baseline and the 3-year follow-up examination. Thus at the 3-year examination, no differences in the restorative crown margin positions were found in the groups. The mean radiographic marginal bone loss at the delivery of definitive crowns was 0.2 ± 0.3 and 0.4 mm ± 0.2 after 3 years of loading. The difference was not statistically significant ($P > .05$). Regarding KTW, the mean values recorded at crown delivery and after 3 years of loading were 3.94 ± 0.9 mm, and 3.89 ± 1.1 mm, respectively, without significant statistical difference, while the mean value of KTT at the implant placement and after 3 years of function was, 1.96 ± 0.6 mm and 1.89 ± 0.9 mm, respectively. No statistically significant differences were found between sites with KTT >2 mm and ≤2 mm.

## 4 | BIOCHEMICAL RESULTS

The mean volumes of PISF in groups A, B, C, and D, were 0.21 ± 1.5, 0.28 ± 0.12, 0.14 ± 0.6, and 0.26 ± 1.1 μL, respectively, without statistically significant difference ($P < .05$). The mean levels of the IL 1β in groups A, B, C, and D, were 13.53 ± 7.5, 14.2 ± 8.1, 14.96 ± 7.8, and 13.52 ± 8.3 pg/mL, respectively; while the mean values of IL-6 were 6.24 ± 4.5, 7.12 ± 4.1, 6.86 ± 4.8, and 7.32 ± 5.1 pg/mL, respectively for groups A, B, C, and D. In the same groups, the mean values of TNF-α were respectively 0.71 ± 0.0.26, 0.72 ± 0.21, 0.68 ± 0.28, and 0.73 ± 0.19 pg/mL. Differences among the groups for IL 1β, IL-6, and TNF-α were not statistically significant (Tables 1–4).

## 5 | MICROBIOLOGICAL RESULTS

Table 5 shows the amount of five periodontal pathogens present in the saliva samples identified in the groups A, B, C, and D, using RT-PCR. *A. actinomycetemcomitans* scored <100 in all groups. In group A, the averages of *Porphyromonas gingivalis*, *Prevotella intermedia*, *Treponema denticola*, and *Tannerella forsythensis* were 2.6 x $10^3$ (SD 0.9), 3.1 x $10^3$ (SD 0.2), 2.0 x $10^3$ (SD 1.0), and 3.2 x $10^3$ (SD 0.4), respectively. In group B, the averages of *Porphyromonas gingivalis*, *Prevotella intermedia*, *Treponema denticola*, and *Tannerella forsythensis* were 0.8 x $10^3$ (SD 0.7), 1.2 x $10^3$ (SD 0.4), 0.9 x $10^3$ (SD 0.7), and 1.3 x $10^3$ (SD 0.1), respectively. In group C, *Porphyromonas gingivalis*, *Prevotella intermedia*, *Treponema denticola*, and *Tannerella forsythensis* scored 0.9 x $10^3$ (SD 0.4), 1.3 x $10^3$ (SD 0.4), 1.2 x $10^3$ (SD 0.5), and 1.5 x $10^3$ (SD 0.1),

**TABLE 1** Comparison of the mean value of PISF (μL) among the four groups

| Groups | Minimum | Maximum | Mean ± SD |
|---|---|---|---|
| A = intracrevicular position with DIM >2 mm | 0.11 | 0.26. | 0.21 ± 1.5 |
| B = intracrevicular position with DIM ≤2 mm/<1 mm | 0.24 | 0.32. | 0.28 ± 0.12 |
| C = intracrevicular position with DIM ≤1 mm/<0 mm | 0.9 | 17.9 | 0.14 ± 0.6 |
| D = extracrevicular position with DIM = 0/−*n* | 0.15 | 0.28 | 0.26 ± 1.1 |
| *P* | >.05 | >.05 | >.05 |

DIM, distance between the implant coronal margin and the mucosal margin; PISF, peri-implant sulcus fluid.

**TABLE 2** Comparison of the level of interleukin-1β (pg/mL) among the four groups

| Groups | Minimum | Maximum | Mean ± SD |
|---|---|---|---|
| A = intracrevicular position with DIM >2 mm | 1.42 | 26.52 | 13.53 ± 7.5 |
| B = intracrevicular position with DIM ≤2 mm/<1 mm | 1.71 | 28.27 | 14.2 ± 8.1 |
| C = intracrevicular position with DIM ≤1 mm/<0 mm | 1.59 | 29.49 | 14.96 ± 7.8 |
| D = extracrevicular position with DIM = 0/−*n* | 1.65 | 28.13 | 13.52 ± 8.3 |
| *P* | >.05 | >.05 | >.05 |

DIM, distance between the implant coronal margin and the mucosal margin.

**TABLE 3** Comparison of the level of interleukin IL-6 (pg/mL) among the four groups

| Groups | Minimum | Maximum | Mean ± SD |
|---|---|---|---|
| A = intracrevicular position with DIM >2 mm | 0.35 | 12.8 | 6.24 ± 4.5 |
| B = intracrevicular position with DIM ≤2 mm/<1 mm | 0.42 | 13.5 | 7.12 ± 4.1 |
| C = intracrevicular position with DIM ≤1 mm/<0 mm | 0.39 | 11.9 | 6.86 ± 4.8 |
| D = extracrevicular position with DIM = 0/−*n* | 0.43 | 14.1 | 7.32 ± 5.1 |
| *P* | >.05 | >.05 | >.05 |

DIM, distance between the implant coronal margin and the mucosal margin.

respectively. In group D, the averages of *Porphyromonas gingivalis*, *Prevotella intermedia*, *Treponema denticola*, and *Tannerella forsythensis* were 0.8 x $10^3$ (SD 0.7), 1.2 x $10^3$ (SD 0.4), 0.9 x $10^3$ (SD 0.7), and 1.3 x $10^3$ (SD 0.1), respectively. The difference between group A and groups B, C, and D was statistically significant.

## 6 | DISCUSSION

In the present study, peri-implant tissue responses to different positions of screw retained restorative crown margins around one-stage laser-microgrooved implants were investigated by evaluating clinical, biochemical, and microbiological parameters. The clinical parameters (PPD, mPI, BOP, GI, and DIM) showed no statistical differences between baseline and 3-year follow-up, regardless of the crown margin position. These results, indicating any statistically relevant changes in peri-implant hard and soft tissue conditions between baseline and 3-year follow-up examination, may be connected to the capacity of laser-microgrooved collar surface to influence positively the peri-implant soft tissue response. Contrary to what has been described for implants with machined/smooth collar, presenting a circumferential organization of the connective fibers, histological data in humans[28] documented the presence of connective tissue fibers around the laser-microgrooved implant perpendicular to the collar surface, which create a biological seal acting to stabilize the peri-implant tissues. Furthermore, one-stage laser-microgrooved implants investigated in the present study were placed with the border of the grit-blasted surface at the bone crest level, and with the 8 μm laser-microgrooved collar 2 mm above the bone crest. In this way, the micrograp/interface was at least 3.3 mm above the bone crest. The possible effects of the micrograp/interface bacterial colonization on BW were minimized.[29] Most clinical measures, used in the present study to evaluate the pathological or health condition of peri-implant tissues status, are indicative of a well-established peri-implant tissue inflammatory response, while they are not sensitive or specific enough to distinguish peri-implant tissue inflammation onset, development, and activity.[14] Analysis of PISF volume and some cytokine levels in the PISF have been suggested in detecting peri-implant inflammatory lesions at an early stage which might be clinically latent.[14] In the present study, in addition to the clinical indices, the volume of PISF, and PISF levels of IL-1β, IL-6, and TNF-α, were assessed. Similarly to gingival crevicular fluid (CGF), PISF is an interstitial fluid that appears in the sulcus because of an osmotic gradient.[17,30] Several clinical studies,[17,30–32] comparing the inflammatory and immunological responses around implants and teeth found no significant difference between PISF and GCF volumes at either healthy or inflamed sites. Inflammatory and immune events were similar in the peri-implant mucosa and gingiva, and GCF and PISF production was governed by similar mechanisms, which depend on peri-implant tissue inflammatory conditions.[30] Furthermore, the volumes of the CGF and PISF appear to be directly related to the severity of the tissue inflammation, as they increase as a function of the greater vascular permeability and ulceration of the epithelium at inflamed sites. Cytokines like interleukin, IL-1β, IL-6, and

**TABLE 4** Comparison of the level of TNF-α (pg/mL) among the four groups

| Groups | Minimum | Maximum | Mean ± SD |
|---|---|---|---|
| A = intracrevicular position with DIM >2 mm | 0.62 | 1.12. | 0.71 ± 0.0.26 |
| B = intracrevicular position with DIM ≤2 mm/<1 mm | 0.53 | 1.13. | 0.72 ± 0.21 |
| C = intracrevicular position with DIM ≤1 mm/<0 mm | 0.59 | 1.19 | 0.68 ± 0.28 |
| D = extracrevicular position with DIM = 0/−*n* | 0.53 | 1.14. | 0.73 ± 0.19 |
| *P* | >.05 | >.05 | >.05 |

DIM, distance between the implant coronal margin and the mucosal margin; TNF-α, tumor necrosis factor.

**TABLE 5** Comparison of the amount of five periodontal pathogens among the four groups

| Groups | *Porphyromonas gingivalis* | *Prevotella intermedia* | *Treponema denticola* | *Tannerella forsythensis* | *Aggregatibacter actinomycetemcomitans* |
|---|---|---|---|---|---|
| A = intracrevicular position >2 mm | $2.6 \times 10^3$ (SD 0.9)* | $3.1 \times 10^3$ (SD 0.2)* | $2.0 \times 10^3$ (SD 1.0)* | $3.2 \times 10^3$ (SD 0.4)* | <100 |
| B = intracrevicular position ≤2 mm/<1 mm | $0.8 \times 10^3$ (SD 0.7) | $1.2 \times 10^3$ (SD 0.4) | $0.9 \times 10^3$ (SD 0.7) | $1.3 \times 10^3$ (SD 0.1) | <100 |
| C = intracrevicular position ≤1 mm/<0 mm | $0.9 \times 10^3$ (SD 0.4) | $1.3 \times 10^3$ (SD 0.4) | $1.2 \times 10^3$ (SD 0.5) | $1.5 \times 10^3$ (SD 0.1) | <100 |
| D = extracrevicular position 0/−*n* | $0.8 \times 10^3$ (SD 0.7) | $1.2 \times 10^3$ (SD 0.4) | $0.9 \times 10^3$ (SD 0.7) | $1.3 \times 10^3$ (SD 0.1) | <100 |

*Difference between the group A and groups B, C, and D was statistically significant ($P < .05$).

TNF-α have been reported to be some of the most important biomarkers, and multifunctional mediators in the peri-implant inflammatory process.[33–41] IL-1β and IL-6 are strong pro-inflammatory proteins because they mediate the production of prostaglandin E2, leukotrienes and platelet-activating factor, and promote osteoclast activation and bone resorption. IL-1β regulates the degradation of extracellular matrix components of the plasminogen system and the collagenase activity in inflammation and wound healing. TNF-α induces fibroblast apoptosis and reduces the repair capacity of the peri-implant tissue.[33–41] Furthermore, IL-1β, IL-6, and TNF-α, induce tissue destruction and bone resorption by the activation of collagenase and through the receptor activator of nuclear factor-kappa B ligand which stimulates osteoclast differentiation. IL-1β, IL-6, and TNF-α have been used as predictors of disease progression,[42–45] as their concentrations increase in diseased peri-implant sites compared to healthy ones.

Tables 1–4, show that the volume of PISF and levels of IL-1β, IL-6, and TNF-α did not present statistically significant variations between the groups examined. This data indicate that no single investigated position of crowns margins (intracrevicular >2 mm, ≤2 mm/<1 mm, ≤1 mm/<0 mm, or extracrevicular position) was significantly more or less compatible with peri-implant tissue health.

Some studies suggested that around tooth abutments, subgingival restorations may create the conditions to stimulate gingival inflammatory responses, and may provide a less suitable environment for gingival health compared to supragingival restorations.[46–48] Some of the restorative factors that can condition directly and indirectly the periodontal health around tooth abutments, include defective contours of the crowns, roughness and porosity of the surfaces, and overhanging and overcontoured restorations.[6,49,50] Conversely, other authors have suggested that, around teeth, intracrevicular crown margin position is not a critical factor, if patients have acceptable oral hygiene. Moreover, if patients are on a regular recall program for dental prophylaxis, the potential for inflammation is reduced adjacent to crown margins below the free gingival tissue.[6,51]

Few data are present in literature on the influence of the crown margin positions on the peri-implant tissue health, and there is still doubt that the intracrevicular depth of crown margins represents a risk factor in the onset of peri-implant tissue inflammation.[23–25]

Unlike what happens on teeth abutments, on implants, prefabricated prosthetics present less roughness and porosity, and for more commonly used implant systems, imperfections between the various components do not exceed 50 μ.[52]

Moreover, around tooth abutments the surface chemistry and topography of the tooth/luting agent/restoration complex provide a potential niche for colonization of oral bacteria. The intracrevicular location of this complex can hinder mechanical removal by routine oral hygiene measures and potentially create an environment conducive to colonization by periodontal pathogens. On the contrary, screw retention of implant-supported restorations eliminates this risk.[53]

Outcomes of the present study indicated that, around one-stage laser-microtextured implant with single screw retained restorations, the intracrevicular margin positions compared to extracrevicular positions, seem not to be a more predisposing condition to the onset of peri-implant tissue inflammation. These results are in agreement with data reported by Kancyper and Koka,[23] who have demonstrated that implant-supported crowns with intracrevicular margins were not associated with a nonfavorable soft tissue response, as measured by gingival redness, swelling, and bleeding. However, it is important to stress that the absence of a control group represents an important limitation of the present study. Accordingly, further research for final confirmation of our findings is needed.

It is well-documented in literature that the initiation/progression of the inflammation process is related to the immune host response,[54] which in turn may be modulated by the presence of implant restoration-associated bacteria in an intracrevicular microenvironment. As the bacteria implicated in peri-implant tissue inflammation are primarily those associated with periodontal inflammation,[19] it has been suggested that the presence of periodontal pathogens, including *A. actinomycetemcomitans*, *Porphyromonas gingivalis*, *Prevotella intermedia*, *Treponema denticola*, and *Tannerella forsythensi*, may be correlated with a high risk of peri-implant diseases.[55] In the present study, intracrevicular levels of these bacteria were measured in the peri-implant sulcus adjacent to four different combinations of restoration margin depths (intracrevicular >2 mm, ≤2 mm/<1 mm, ≤1 mm/<0 mm, or extracrevicular position). The results indicated that extracrevicular restoration margins, and intracrevicular restoration margins (<2 mm) did not predispose a patient to a high level of sulcular colonization by the putative periodontal disease-associated bacterial species tested in this study. On the contrary, an intrasulcular restorative margin position deeper than 2 mm was correlated with a higher level of pathogens. The higher levels might indicate that the deeper location of the restoration margins could be a predisposing condition of colonization by such bacteria, and therefore, in the susceptible host, could be a condition of higher risk to develop a peri-implant inflammation. The intracrevicular location >2 mm of restorative margin could make difficult the patient's routine oral hygiene efforts, and potentially create an environment conducive to colonization by periodontal pathogens. However, it is important to highlight that the host response to a restoration margin depth is of greater clinical importance than merely measuring the presence or levels of any specific bacterial species.

Therefore, the single datum of intracrevicular levels of putative periodontal-pathogens is not sufficient to determine whether the deeper location of restoration margins is a predisposing condition to the onset or development of peri-implant tissue inflammation, and should be at least related to biochemical markers levels found in the same implant sites. In the present study, the difference in subgingival concentration of *A. actinomycetemcomitans*, *Porphyromonas gingivalis*, *Prevotella intermedia*, *Treponema denticola*, and *Tannerella forsythensi* found in the group A, compared to groups B, C, and D did not show any statistical correlation, after 3 year of function with levels of IL-1β, IL-6, and TNF-α or with PPD, mPI, BOP, and GI. The results indicate that further research is needed to clarify the biologic significance of the higher concentration of putative periodontal pathogens around implant-supported restoration with intracrevicular restorative margin >2 mm.

The results of the present study must be interpreted cautiously because of some limitations. In addition to the aforementioned absence of a control group without regular compliance with the supportive periodontal therapy, the small sample size, the short-term follow-up, and the lack of randomization in treatment groups (A, B, C, and D) made causal interpretation difficult. Therefore, final confirmation of findings needs further studies.

## ACKNOWLEDGMENT

The study was supported by BioHorizons, Birmingham, AL, USA, who provided the materials.

## CONFLICT OF INTEREST

The authors reported no conflicts of interest related to this study.

## ORCID

*Renzo Guarnieri* https://orcid.org/0000-0003-1449-8340

## REFERENCES

1. Morton D, Chen ST, Martin WC, Levine RA, Buser D. Consensus statements and recommended clinical procedures regarding optimizing esthetic outcomes in implant dentistry. *Int J Oral Maxillofac Implants*. 2014;29:216-220.
2. Belser UC, Buser D, Hess D, Schmid B, Bernard JP, Lang NP. Esthetic implant restorations in partially edentulous patients—a critical appraisal. *Periodontol 2000*. 1998;17:132-150.
3. Buser D, von Arx T. Surgical procedures in partially edentulous patients with ITI implants. *Clin Oral Implants Res*. 2000;11:83-100.
4. Belser UC, Mericske-Stern R, Bernard JP, Taylor T. Prosthetic management of the partially dentate patient with fixed implant restorations. *Clin Oral Implants Res*. 2000;11:126-145.
5. Padbury A Jr, Eber R, Wang H-L. Interactions between the gingiva and the margin of restorations. *J Clin Periodontol*. 2003;30:379-385.
6. Newcomb GM. The relationship between the location of subgingival crown margins and gingival inflammation. *J Periodontol*. 1974;45:151-154.
7. Gunay H, Seeger A, Tschernitschek H, Geurtsen W. Placement of the preparation line and periodontal health—a prospective 2-year clinical study. *Int J Periodont Rest Dent*. 2000;20:171-181.
8. Nevins M, Skurow HM. The intracrevicular restorative margin, the biologic width, and the maintenance of the gingival margin. *Int J Periodont Rest Dent*. 1984;3:31-49.
9. Orkin DA, Reddy J, Bradshaw D. The relationship of the position of crown margins to gingival health. *J Prost Dent*. 1987;57:421-442.
10. Wang H-L, Burgett FG, Shyr Y. The relationship between restoration and furcation involvement on molar teeth. *J Periodontol*. 1993;64:302-305.
11. Dragoo MR, Williams GB. Periodontal tissue reactions to restorative procedures, Part I. *Int J Periodont Rest Dent*. 1981;2:8-29.
12. Dragoo MR, Williams GB. Periodontal tissue reactions to restorative procedures, Part II. *Int J Periodont Rest Dent*. 1982;2:34-42.
13. Flores-de-Jacoby L, Zafiropoulas GG, Cianco S. The effect of crown margin location on plaque and periodontal health. *Int J Periodont Rest Dent*. 1989;9:197-205.
14. Dursun E, Tözüm TF. Peri-implant Crevicular fluid analysis, enzymes and biomarkers: a Systemetic review. *J Oral Maxillofac Res*. 2016;7(3):e9.
15. Carranza FA, Newman GS, Takei HH, eds. *Carranza's Clinical Periodontology*. 9th ed. Los Angeles, CA: Saunders; 2002.
16. Bhardwaj S, Prabhuji ML. Comparative volumetric and clinical evaluation of peri-implant sulcular fluid and gingival crevicular fluid. *J Periodontal Implant Sci*. 2013;43(5):233-242.
17. Tözüm TF, Akman AC, Yamalik N, et al. Analysis of the inflammatory process around endosseous dental implants and natural teeth: myeloperoxidase level and nitric oxide metabolism. *Int J Oral Maxillofac Implants*. 2007;22(6):969-979.
18. Loesche WJ. Clinical and microbiological aspects of chemotherapeutic agents used according to the specific plaque hypothesis. *J Dent Res*. 1979;58:2404-2412.
19. Mombelli A. Etiology, diagnosis, and treatment considerations in peri-implantitis. *Curr Opin Periodontol*. 1997;4:127-136.
20. Dabdoub SM, Tsigarida AA, Kumar PS. Patient-specific analysis of periodontal and peri-implant microbiomes. *J Dent Res*. 2013;92-(12 suppl):168S-175S.
21. Persson GR, Renvert S. Cluster of bacteria associated with peri-implantitis. *Clin Implant Dent Relat Res*. 2014;16(6):783-793.
22. Belibasakis GN. Microbiological and immuno-pathological aspects of peri-implant diseases. *Arch Oral Biol*. 2014;59(1):66-72.
23. Kancyper SG, Koka S. The influence of intracrevicular crown margins on gingival health: preliminary findings. *J Prosthet Dent*. 2001;85(5):461-465.
24. Giannopoulou C, Bernard JP, Buser D, Carrel A, Belser UC. Effect of intracrevicular restoration margins on peri-implant health: clinical, biochemical, and microbiologic findings around esthetic implants up to 9 years. *Int J Oral Maxillofac Implants*. 2003;18(2):173-181.
25. Nisapakultorn K, Suphanantachat S, Silkosessak O, Rattanamongkolgul S. Factors affecting soft tissue level around anterior maxillary single-tooth implants. *Clin Oral Impl Res*. 2010;21:662-670.
26. Mombelli A, Lang NP. Clinical parameters for the evaluation of dental implants. *Periodontol 2000*. 1994;4:81-86.
27. Löe H. The gingival index, the plaque index and the retention index systems. *J Periodontol*. 1967;38:610-616.
28. Nevins M, Nevins ML, Camelo M, Boyesen JL, Kim DM. Human histologic evidence of a connective tissue attachment to a dental implant. *Int J Periodont Rest Dent*. 2008;28(2):111-121.
29. Hermann JS, Jones AA, Bakaeen LG, Buser D, Schoolfield JD, Cochran DL. Influence of a machined collar on crestal bone changes around titanium implants: a histometric study in the canine mandible. *J Periodontol*. 2011;82(9):1329-1338.
30. Sakallıoğlu U, Lütfioğlu M, Sakallıoğlu EE, Sert S, Ceylan G. Osmotic pressure of periimplant sulcular and gingival crevicular fluids: a split-mouth, randomized study of its measurement and clinical significance. *Clin Oral Implants Res*. 2011;22(7):706-710.
31. Sakallioğlu EE, Lütfioğlu M, Sakallioğlu U, et al. Gingival crevicular fluid levels of neuropeptides following dental restorations. *J Appl Biomater Funct Mater*. 2015;13(2):e186-e193.
32. Kaklamanos EG, Tsakilis L. A review on peri-implant crevicular fluid assays potential in monitoring and predicting peri-implant tissue responses. *J Int Acad Periodontol*. 2002;4:49-59.
33. Kurtis B, Tuter G, Serdar M, et al. Gingival crevicular fluid levels of monocyte chemoattractant protein-1 and tumornecrosis factor-alpha in patients with chronic and aggressive periodontitis. *J Periodontol*. 2005;76(11):1849-1855.

34. Reis C, Da Costa AV, Guimar˜aes JT, et al. Clinical improvement following therapy for periodontitis: association with a decrease in IL-1 and IL-6. *Experim Therap Med*. 2014;8(1):323-327.
35. Casado PL, Canullo L, de Almeida FA, Granjeiro JM, Barboza EP, Leite Duarte ME. Interleukins 1β and 10 expressions in the periimplant crevicular fluid from patients with untreated periimplant disease. *Impl Dent*. 2013;22(2):143-150.
36. Petković AB, Matić SM, Stamatović NV, et al. Proinflammatory cytokines (IL-1beta and TNF-alpha) and chemokines (IL-8 and MIP-1alpha) as markers of peri-implant tissue condition. *Int J Oral Maxillofac Surg*. 2010;39(5):478-485.
37. Kao RT, Curtis DA, Richards DW, Preble J. Increased interleukin-1 beta in the crevicular fluid of diseased implants. *Int J Oral Maxillofac Implants*. 1995;10(6):696-701.
38. Duarte PM, de Mendonça AC, Máximo MB, Santos VR, Bastos MF, Nociti FH. Effect of anti-infective mechanical therapy on clinical parameters and cytokine levels in human peri-implant diseases. *J Periodontol*. 2009 Feb;80(2):234-243.
39. Troen BR. Molecular mechanisms underlying osteoclast formation and activation. *Exp Gerontol*. 2003;38:605-614.
40. Boyce BF, Li P, Yao Z, et al. TNF-alpha and pathologic bone resorption. *Keio J Med*. 2005;54(3):127-131.
41. Seymour GJ, Gemmell E. Cytokines in periodontal disease: where to from here? *Acta Odontol Scand*. 2001;59:167-173.
42. Liskmann S, Zilmer M, Vilhalemm T, Salum O, Fischer K. Correlation of peri-implant health and myeloperoxidase levels: a cross-sectional clinical study. *Clin Oral Implants Res*. 2004;15:546-552.
43. Özkavaf A, Aras H, Huri CB, et al. Relationship between the quantity of gingival crevicular fluid and clinical periodontal status. *J Oral Sci*. 2000;42:231-238.
44. Adonogianaki E, Mooney J, Wennström LU, Kinane DF. Acute-phase proteins and immunoglobulin G against Porphyromonas gingivalis in peri-implant crevicular fluid: a comparison with gingival crevicular fluid. *Clin Oral Implants Res*. 1995;6:14-23.
45. Gokul K. Estimation of the level of tumor necrosis factorin gingival crevicular fluid and serum in periodontal health and disease: a biochemical study. *Ind J Dent Res*. 2012;23(3):348-352.
46. Loe H. Reactions to marginal periodontal tissues to restorative procedures. *Int Dent J*. 1968;18(4):759-778.
47. Smales RJ, Nixon KC, Joyce KP. Effects of subgingival restorations in beagle dogs. Part II: Gingivitis. *J Prosthet Dent*. 1979;41(5):522-527.
48. Blank LW, Caffesse RG, Charbeneau GT. The gingival response to well-finished composite resin restorations. *J Prosthet Dent*. 1979; 42(6):626-632.
49. Waerhaug J. Effects of rough surface upon gingival tissue. *J Dent Res*. 1965;35:323.
50. Yuodelis RA, Weaver JD, Sapkos S. Facial and lingual contours of artificial complete crown restorations and their effects on the periodontium. *J Prost Dent*. 1973;29:61-66.
51. Valderhaug J, Ellingsen JE, Jokstad A. Oral hygiene, periodontal conditions and carious lesions in patients treated with dental bridges: a 15-year clinical and radiographic follow-up study. *J Clin Periodontol*. 1993;20(7):482-489.
52. Binon P, Weir D, Watanabe L, Walker L. Implant component compatibility. In: Laney WR, Tolman DE, eds. *Tissue Integration in Oral, Orthopedic and Maxillofacial Reconstruction*. Chicago, IL: Quintessence Publishing; 1992:218-226.
53. Wittneben JG, Millen C, Brägger U. Clinical performance of screw-versus cement-retained fixed implant-supported reconstructions—a systematic review. *Int J Oral Maxillofac Implants*. 2014;29:84-98.
54. Silness J. Periodontal conditions in patients treated with dental bridges. *J Periodontal Res*. 1970;5:60-68.
55. Sumida S, Ishihara K, Kishi M, Okuda K. Transmission of periodontal disease-associated bacteria from teeth to osseointegrated implant regions. *Int J Oral Maxillofac Implants*. 2002;17:696-702.


**How to cite this article:** Guarnieri R, Di Nardo D, Gaimari G, Miccoli G, Testarelli L. Influence of restorative margins position on one-stage laser-microgrooved implants-supported single screwed crowns: A clinical, biochemical, and microbiological analysis. *Clin Implant Dent Relat Res*. 2018;1–8. https://doi.org/10.1111/cid.12693