# Implant-Gingival Unit Stability Around One-Stage Implant with Laser-Microgrooved Collar: Three-Year Result of a Prospective Study



*Renzo Guarnieri, MD, DDS*[1]
*Dario Di Nardo, DDS, PhD*[1]
*Gianfranco Gaimari, DDS, PhD*[1]
*Gabriele Miccoli, DDS, PhD*[1]
*Luca Testarelli, DDS, PhD*[1]

*The aim of the present prospective study was to evaluate the stability of peri-implant soft tissue and the stability of the implant-gingival unit (IGU) around one-stage titanium implants with a laser-microgrooved collar surface following 3 years of loading. Thirty one-stage titanium implants with a laser-microgrooved collar surface were placed in 30 partially edentulous patients. Clinical and radiographic examinations were carried out at implant placement, after a period of 4 to 6 months free of masticatory loading, and after 3 years of function. Plaque Index (PI), modified sulcus bleeding index (SBI), probing depth (PD), distance between the implant coronal margin and the mucosal margin (DIM), clinical attachment level (CAL), and keratinized tissue width (KTW) and thickness (KTT) were recorded. Radiographic marginal bone levels (MBL) were assessed at the mesial (MI) and distal (DI) aspects of implant sites. In addition, the influence of KTT on IGU stability was investigated. No implants failed during the follow-up period. Compared to baseline, PI, BPI, PD, DIM, CAL, KTW, MBL, and IGU showed differences that were not statistically significant (P > .05). Moreover, IGU didn't show a statistical correlation with KTT. Within the limitations of the present study, it can be concluded that around one-stage implants with laser-microgrooved collar, the peri-implant tissues and IGU remain stable over the three evaluation periods.*
Int J Periodontics Restorative Dent 2019;39:875–882. doi: 10.11607/prd.3983

[1]Department of Dental and Maxillofacial Sciences, School of Dentistry, University La Sapienza, Rome, Italy.

Correspondence to: Dr Dario Di Nardo, Via Caserta 6, 00161 Roma, Italy.
Email: dario.dinardo@uniroma1.it

Submitted June 18, 2018; accepted July 23, 2018.
©2019 by Quintessence Publishing Co Inc.

The term "implant-gingival unit" (IGU) was coined by Cochran et al,[1] translating to dental implants the anatomic concepts of the dento-gingival unit (DGU). It was used to describe the relationships of the peri-implant mucosal tissue, as documented by a series of animal studies conducted around both one- and two-stage implants.[1–5] The histometric measurements of IGU allowed definition of the peri-implant biologic width (BW) dimensions and the relationship of its structural components, such as the peri-implant sulcus, the peri-implant junctional epithelium, and the peri-implant connective tissue attachment. These have been demonstrated to be significantly influenced by implant design characteristics, such as the presence or absence of microgap/interface between implant components, the microfeatures of the collar implant surface (machined or textured), and the placement technique (one- or two-stage) in relation to the crest of the bone.[1,6,7] Comparing the combined effects of above-mentioned factors that influence the dimension of implant BW and its components, histologic results in animals[6] indicated that the peri-implant soft tissue dimensions similar to natural dentition, as measured in the classic work by Gargiulo et al,[8] could be achieved using one-stage placement of an implant with



© 2019 BY QUINTESSENCE PUBLISHING CO, INC. PRINTING OF THIS DOCUMENT IS RESTRICTED TO PERSONAL USE ONLY.
NO PART MAY BE REPRODUCED OR TRANSMITTED IN ANY FORM WITHOUT WRITTEN PERMISSION FROM THE PUBLISHER.

a rough border at the alveolar crest and microgap/interface, placed at least 1 mm above the bone crest.

In an effort to obtain better peri-implant soft tissue responses, new surfaces and treatments for the implant neck have been recently proposed. Experimental in vitro studies[9–12] showed a high potential of fibroblast adhesion, growth, and differentiation into a microtextured surface with microgrooves 8 μm in pitch, created with a pulsed laser technology. Subsequent histologic results in humans documented that the application of this technology to dental implants allows a physical attachment of connective soft tissue into a microgrooved collar surface to be obtained.[13] Same histologic results have been documented also around laser-microgrooved healing and prosthetic abutments[14,15]; the high mechanical stability of this physical connective attachment, with connective fibers perpendicularly oriented to the microgrooved implant collar, suggests the formation of a soft-tissue seal, which might counteract the junctional epithelium downgrowth and peri-implant marginal bone remodeling.[16] However, there are no data in the literature investigating the stability of this kind of connective attachment over time. Therefore, the aim of the present study was to evaluate the stability of the IGU and, in an indirect manner, the stability of the connective attachment around one-stage implants with laser-microgrooved collar during 3 years of loading.

## Materials and Methods

### *Patients*

Thirty partially edentulous patients (17 males and 13 females, mean age 48.9 years) requiring implant therapy for a prosthetic rehabilitation participated in this study. Patients were included if they were older than 18 years, were in good general health, and had sufficient amount of bone available to place a standard implant (3.8-mm diameter and 9-mm length) detectable by cone beam computed tomography evaluation. Exclusion criteria were: natural teeth adjacent to the surgical area affected by untreated periodontal or endodontic infections; peri-implant bone defects requiring bone augmentation; absence of opposing occlusion; full-mouth plaque score (FMPS) ≥ 25%; full-mouth bleeding score (FMBS) ≥ 25% recorded at the time of implant placement; parafunctional habits; severe maxillary/mandibular space discrepancies; uncontrolled diabetes and treatment with bisphosphonates; patients smoking > 10 cigarettes a day; and any drug/alcohol abuse. Each patient was informed about the evidence-based, positive outcome of implant treatment and signed a free informed consent form after receiving detailed information about the study. Treatments were performed according to the principles outlined in the Declaration of Helsinki on experimentation involving human subjects. The study was approved by the Research Ethics Committee of the La Sapienza University of Rome (#4597).

### *Implants*

Thirty one-stage Tissue Level Laser-Lok implants (BioHorizons) were inserted by the same surgeons (R.G. and L.T.) in 30 patients using the same one-stage protocol. The implants have a grit-blasted body to create a moderately rough surface, while the apical 2.0 mm of the collar are characterized by the presence of laser-produced microgrooves in the range of 8 μm, and the most coronal 1.3 mm of the collar is smooth, machined metal.

All implants were inserted with the rough/microgrooved border placed flush to the bone crest with the 2-mm laser-microgrooved surface over the bone crest.

### *Clinical Procedure*

Before implant placement (T0), the FMPS and FMBS of each patient were collected. After performing anesthesia, keratinized tissue thickness (KTT) was measured by means of no. 30 K-file (Kerr) inserted until touching the bone crest. The KTT was dichotomized into two groups (≤ 2 mm and > 2 mm) in accordance with the results of an animal study performed by Berglundh et al.[17]

All subjects adopted an antimicrobial prophylaxis with mouthrinses of 0.12% chlorhexidine, used 1 minute before surgery and three times a day for the following 10 days (Dentosan 0.12%, Johnson & Johnson). Amoxicillin + clavulanic acid (1 g bid; Augmentin, GlaxoSmithKline) was prescribed for 7 days. Local anesthesia was induced by



© 2019 BY QUINTESSENCE PUBLISHING CO, INC. PRINTING OF THIS DOCUMENT IS RESTRICTED TO PERSONAL USE ONLY.
NO PART MAY BE REPRODUCED OR TRANSMITTED IN ANY FORM WITHOUT WRITTEN PERMISSION FROM THE PUBLISHER.

infiltration with articaine/epinephrine (1:100,000; 20 mg/mL; Ecocain, Molteni Dental). Crestal incisions were made with maximum effort to maintain the periodontal tissues of adjacent teeth; vertical releasing incisions were made only if necessary to obtain better visibility. A full-thickness flap was reflected buccally and lingually to expose the alveolar ridge of each implant site. Single-stage surgery with a nonsubmerged healing approach was performed in all sites. Closure of the flap was obtained without tension using 4.0 or 5.0 monofilament sutures. Patients were instructed to have a liquid or semiliquid diet for the first 3 days and then gradually return to a normal diet. An analgesic (ibuprofen, 600 mg) was prescribed, given immediately after surgical intervention and 8 hours later. Sutures were removed 7 to 10 days after surgery. At the delivery of definitive crowns (T1), on the mesial, distal, facial, and lingual implant surfaces, the following parameters were recorded: modified plaque index (PI),[18] modified sulcus bleeding index (SBI),[18] probing depth (PD), and the distance between the implant coronal margin and the mucosal margin (DIM) (Fig 1), measured to the nearest mm. In presence of a subgingival implant coronal margin, the measurement was recorded as negative value. The clinical attachment level (CAL) was calculated for each site by adding PD and DIM (Fig 1). In addition, at each implant site, the keratinized tissue width (KTW) was recorded. The KTW was determined by subtracting the sulcus depth from total width of gingiva measured by using a periodontal probe on the midfacial side from the mucogingival junction.[19] All the above-mentioned parameters were recorded at the same implant surfaces 3 years after loading (T3).

### *Radiographic Examination*

Radiographs were performed immediately at implant placement (T0), at the delivery of definitive crowns 4 to 6 months after surgery (T1), and 3 years after loading (T3) with a paralleling technique using a Rinn film holder with a rigid film-object x-ray source. For the radiograph procedure, a silicone index material was fixated to the residual dentition and a radiograph holder was constructed for each patient. This technique ensured that the same position of the radiograph film could be reproduced at each visit and the angle of the radiograph would not deviate. The radiographs were taken in high-resolution mode (VistaScan Dürr Dental) with a dental radiograph machine (PM 2002 CC Planmeca ProLine, Planmeca) equipped with a long tube that operated at 70 Kw/7.5 mA. Specialized software (DBSWIN, Dürr Dental) was used for linear measurements of marginal bone changes. The following radiographic measurements were performed (Fig 2): radiographic implant length (IL), which is the distance (in mm) between the implant coronal margin and the implant apex, as assessed at the midportion of the implant; and residual bone height at the mesial (MI) and distal (DI) aspects of the implant, which is the distance

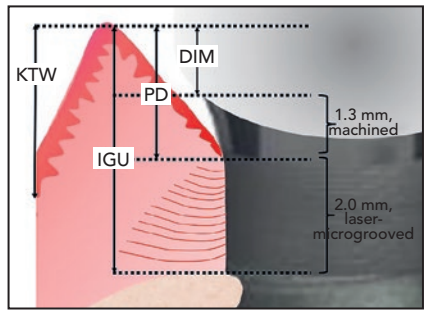


**Fig 1** *Schematic illustration of the investigated clinical measurements: KTW = keratinized tissue width; IGU = implant-gingival unit; PD = probing depth; DIM = distance between the implant coronal margin and the mucosal margin.*

(in mm) between the line linking the coronal implant margin and the first contact of the crestal bone on the respective side of the implant (Fig 2).

To account for radiographic distortion, measurements on each radiograph were adjusted for a coefficient derived from the ratio: true length of the implant / IL. All measurements were carried out by a single trained examiner (R.G.) who had previously undergone a calibration session for radiographic assessment on a sample of five patients treated with the same implant system who were not included in the study (kappa test = 0.9550; standard error of kappa = 0.048; 95% confidence interval: 0.862 to 1.000).

IGU was calculated by superimposing clinical and radiographic data, using the following formula, where 1.3 represents the height (in mm) of the machined collar:

$$IGU = [(MI + DI) / 2] - 1.3 + \text{mean CAL}$$



© 2019 BY QUINTESSENCE PUBLISHING CO, INC. PRINTING OF THIS DOCUMENT IS RESTRICTED TO PERSONAL USE ONLY.
NO PART MAY BE REPRODUCED OR TRANSMITTED IN ANY FORM WITHOUT WRITTEN PERMISSION FROM THE PUBLISHER.

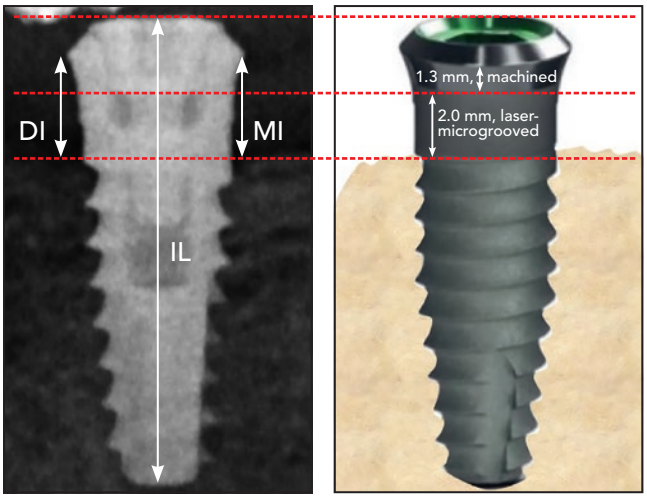


**Fig 2** *Schematic illustration of the investigated radiographic measurements: DI = residual bone height (in mm) at the distal aspect; MI = residual bone height (in mm) at the mesial aspect; IL = distance (in mm) between the implant coronal margin and the implant apex, assessed at the midportion of the implant.*

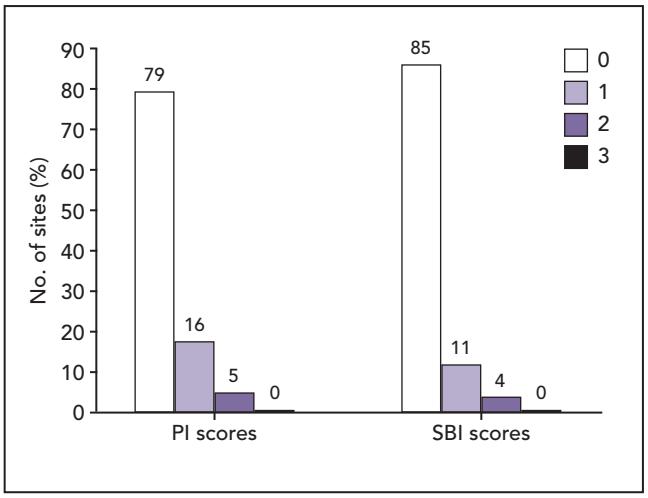


**Fig 3** *Frequency of Plaque Index (PI) and modified sulcus bleeding index (SBI) scores, which were measured at four sites, after 3 years of loading.*

## Results

No patients dropped out within the follow-up period. Thus, 30 implants in 30 subjects were evaluated. After 3 years of loading, the cumulative survival rate was 100%. PI values of 3, 2, 1, and 0 were recorded in 0, 6 (5%), 19 (16%), and 96 (79%) of 120 implant sites, respectively. A bleeding score of 0 was seen in 102 (85%) sites, while in 13 (10.8%), 5 (4.2%), and 0 sites the bleeding scores (SBI) were 1, 2, and 3, respectively (Fig 3). The mean PD values prior to and 3 years after loading were 2.02 ± 0.4 mm and 2.04 ± 0.3 mm, respectively. Regardless of the loading period, all implant sites showed a subgingival implant coronal margin, thus the mean DIM was recorded with a negative score. Before implant loading, the mean DIM value was –0.96 mm, while 3 years after loading it was –0.92 mm. Accordingly, the mean CAL values, obtained by adding the mean DIM value to the mean PD value, were 1.06 mm and 1.12 mm before and 3 years after implant loading, respectively. The mean radiographic marginal bone loss at the delivery of definitive crowns was 0.2 ± 0.3 mm, and after 3 years of loading was 0.4 ± 0.2 mm. Before implant loading, the radiographic MI value was 3.30 ± 0.3 mm, and the DI value was 3.31 ± 0.2 mm, while the same mesial and distal values after 3 years of implant loading were 3.35 ± 0.2 mm and 3.32 ± 0.1 mm, respectively. Thus, the IUG presented a mean value of 3.06 mm before implant loading and presented a mean value of 3.15 mm after 3 years of implant loading (Figs 4 to 6). The difference was not statistically significant ($P > .05$). Regarding KTW, the mean values recorded at the delivery crowns and after 3 years of loading were 3.94 ± 0.9 mm and 3.89 ± 1.1 mm, respectively, without statistical differences, while the mean KTT values at implant placement and after 3 years of function were 1.96 ± 0.6 mm and 1.89 ± 0.9 mm, respectively. No statistically significant differences were found in IGU between sites with KTT > 2 mm and those with KTT ≤ 2 mm (Table 1).

## Discussion

DGU has been first defined by Sicher[20] as the structural and functional unit present around natural teeth, composed by the epithelial and the connective tissue attachments of the



© 2019 BY QUINTESSENCE PUBLISHING CO, INC. PRINTING OF THIS DOCUMENT IS RESTRICTED TO PERSONAL USE ONLY.
NO PART MAY BE REPRODUCED OR TRANSMITTED IN ANY FORM WITHOUT WRITTEN PERMISSION FROM THE PUBLISHER.

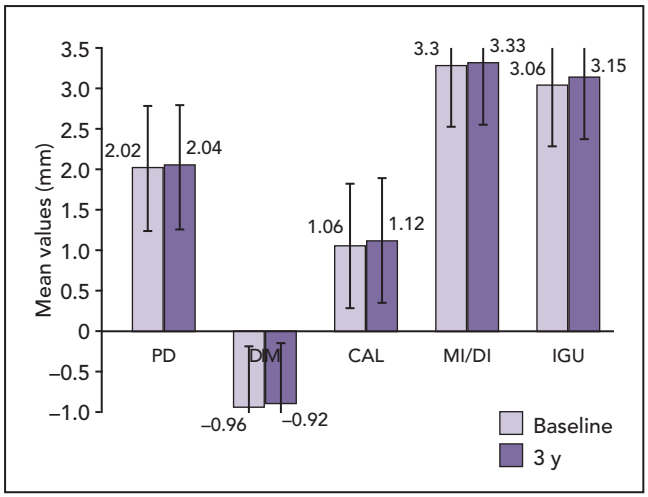


**Fig 4** *Mean clinical and radiographic measurements recorded at baseline and after 3 years: probing depth (PD), distance between the implant coronal margin and the mucosal margin (DIM), clinical attachment level (CAL), residual bone height at the mesial and distal radiographic aspects of the implant (MI/DI), and implant-gingival unit (IGU).*

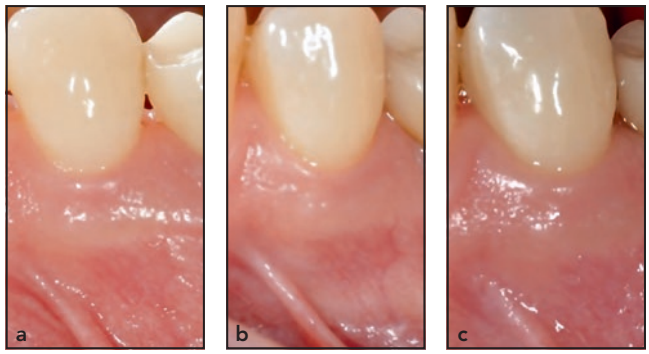


**Fig 5** *Clinical aspect of peri-implant tissues at* (a) *crown delivery,* (b) *2-year control, and* (c) *3-year control.*

**Table 1 Correlation Between KTT and IGU**

| KTT | No. of implants | IGU ± SD (mm) Baseline | IGU ± SD (mm) 1 y | *P* |
|---|---|---|---|---|
| > 2 mm | 22 | 2.08 ± 0.6 | 2.01 ± 0.4 | > .05 |
| ≤ 2 mm | 8 | 1.85 ± 0.9 | 1.78 ± 0.8 | > .05 |
| *P* | | > .05 | > .05 | |

KTT = keratinized tissue thickness; IGU = implant-gingival unit; SD = standard deviation.

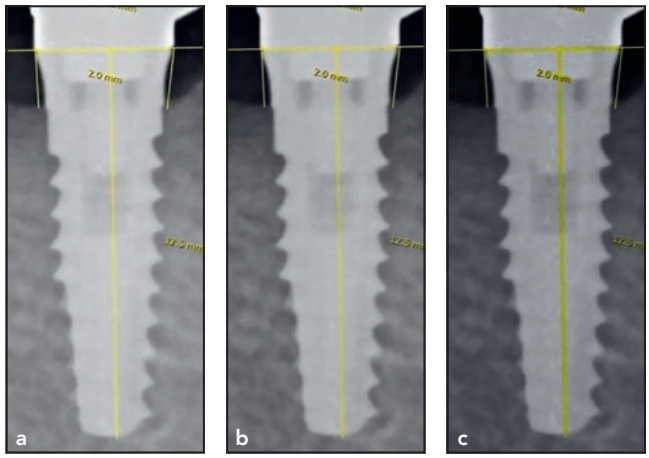


**Fig 6** *Radiographic aspect of the mesial and distal marginal bone levels at* (a) *crown delivery,* (b) *2-year control, and* (c) *3-year control.*

gingiva. It has been described histometrically by Gargiulo et al,[8] who used the term "physiological DGU" in application to the anatomical complex formed by the gingival margin, sulcus, junctional epithelium, and connective tissue attachment. The mean dimensions of the DGU components found in humans were 0.69 mm for the sulcus, 0.97 mm for the epithelial attachment, and 1.07 mm for the connective tissue attachment. The distance between the bottom of the gingival sulcus and the alveolar bone crest (mean value: 2.04 mm) was later named by Cohen[21] to be "biological width" since it represents a physiologically formed and stable space protecting from bacteria and invasion of other foreign materials. After detailed assessment of cadaver tooth surfaces, Vacek et al[22] also realized that the connective tissue attachment was the most stable measurement with the least degree of variance. Clinically, the DGU is located close to the cementoenamel junction, the gingival margin slightly covering the limits of the dental crown.[23]



© 2019 BY QUINTESSENCE PUBLISHING CO, INC. PRINTING OF THIS DOCUMENT IS RESTRICTED TO PERSONAL USE ONLY.
NO PART MAY BE REPRODUCED OR TRANSMITTED IN ANY FORM WITHOUT WRITTEN PERMISSION FROM THE PUBLISHER.

As histologically described by Cochran et al,[1] unlike what is documented for BW around teeth in healthy conditions (which present a constant mean dimension and a constant vertical relationship of the structural components), the implant BW depends on implant design characteristics, such as the presence or absence of microgap/interface between implant components, the microfeatures of the implant collar surface (machined or textured), and the placement technique (one- or two-stage) in relation to the crest of the bone. Subsequent histologic experimental comparative analysis in animals[6,23] documented that the peri-implant soft tissue dimensions that are similar to the natural dentition[8] could be obtained using one-stage placement of an implant with a rough border at the alveolar crest and the microgap/interface placed at least 1 mm above the bone crest. In this case, the obtained BW dimension remains stable after at least 1 year of loading, though significant differences occurred within its components, with an increase in linear dimension of the junctional epithelium compensated by the decrease of sulcus depth and connective tissue contact. The reasons for these changes are not yet known; however, some etiologic factors have been called into question, such as the occlusal forces placed on the implants over time, the maturation of peri-implant connective tissues,[6] and the peri-implant epithelial downgrowth.[24]

The one-stage implants investigated in the present study were placed with the border of the grit-blasted surface at the bone crest level and with the 8-µm laser-microgrooved collar 2 mm above the bone crest. This way, the microgap/interface was at least 3.3 mm above the bone crest, and the effects of the microgap/interface bacterial colonization on BW were eliminated. The mean DI (3.30 mm) and MI (3.31 mm) values, documented radiographically after the surgery, justify the assumption that the implant was placed according to the previous description in Materials and Methods. The placement depth of the implant and its radiographic reference points made it possible to carry out an assessment by superimposing clinical and radiographic data. Around a natural tooth, the cementoenamel junction represents the reference point for the CAL measurement. Likewise, in the present study, the implant coronal margin was used as a reference point for the CAL measurement. The epithelial downgrowth around implants is related to the coronal-apical proliferation and migration of epithelial cells derived from the mucosa, forming a junctional epithelium.[25] Around natural teeth, the junctional epithelium downgrowth is prevented by the gingival-fiber apparatus,[26,27] and that tissue has been speculated to provide the same important role around dental implants.[26,27] Experimental animal analysis showed that in the presence of healthy peri-implant conditions, the connective-fiber apparatus provides a seal, which blocks the tip of the probe at the apical extension of the junctional epithelium.[28]

In the present study, the mean CAL values recorded around implants before and after 3 years of loading were 1.06 mm and 1.12 mm, respectively, and the mean PD values before and 3 years after loading were 2.02 ± 0.4 mm and 2.04 ± 0.3 mm, respectively. The mean marginal bone loss values at the same time points were 0.2 ± 0.3 mm and 0.4 ± 0.2 mm, respectively. Consequently, one can hypothesize that the presence of an anatomical structure of about 1 mm, which remains stable over time, around the investigated implants provides a barrier against probe penetration. One study showed a direct relationship between the nanomorphology of the substrate surface and the cell attachment, orientation, and differentiation.[29] The phenomenon was first observed over a century ago by R. G. Harrison, then later described by Weiss and Garber[30] using the term "contact guidance," since it depends on the ability of cells to sense a specific environment. Laser-microgrooved surfaces have been the object of several tissue culture studies investigating its influence on fibroblast and epithelial cell-spreading and orientation.[9–12] Results showed that the laser-microtextured surface with 8-µm–pitched microgrooves has a high potential of fibroblast growth and orientation and an effective inhibition of epithelial cell migration across the microgrooves. Subsequent histologic animal and human studies[13–15] documented the possibility of obtaining a perpendicular/functional organization of connective tissue around implants and abutments, with fibers



© 2019 BY QUINTESSENCE PUBLISHING CO, INC. PRINTING OF THIS DOCUMENT IS RESTRICTED TO PERSONAL USE ONLY.
NO PART MAY BE REPRODUCED OR TRANSMITTED IN ANY FORM WITHOUT WRITTEN PERMISSION FROM THE PUBLISHER.

perpendicularly oriented to the laser-microgrooved collar surface to provide a stable soft tissue seal. In the present study, no statistically significant variations were found in PD, CAL, DIM, or MBL 3 years after loading. Clinical and radiographic results suggest, albeit indirectly, the presence of an anatomic structure around the investigated implants, likely of connective nature, that finds mechanical stability from the microtextured implant collar and remains stable over time.

Further interesting data from the present study emerged from the KTW and KTT data. At the end of the follow-up period, 84% of sites presented a KTW > 3.5 mm, with an overall mean KTW value of 3.89 ± 1.1 mm. The high percentage of implant sites with KTW > 3.5 mm demonstrates the conservative approach of one-stage compared to two-stage surgical procedure, in which the KTW is often sacrificed during the reopening procedure. After 3 years of function, the mean value of KTT was 1.89 ± 0.4 mm, and no statistical correlations were found in the IGU mean value between sites with KTT > 2 mm and ≤ 2 mm. Thus, in contrast to the values determined by other authors as necessary to maintain peri-implant soft tissue health,[31] the present findings suggest that, around the investigated one-stage implants, even smaller amounts of KTT may be sufficient for IGU stability. A possible explanation for this is that the laser-microgrooved collar surface has the ability to promote a stable physical connective tissue attachment, regardless of the thickness of keratinized mucosa at implant sites. However, the present study's small sample size, short follow-up period, absence of histologic data, and absence of a control group of implants without a laser-microtextured collar surface prevent the authors from drawing definite conclusions, and further studies are needed to confirm the current findings, possibly with histologic analysis.

## Conclusions

Within the limitations of the present study, it can be concluded that a laser-microgrooved collar prevents epithelium downgrowth, prevents marginal bone loss, and favors the stability of IGU around one-stage implants.

## Acknowledgments

The authors declare no conflicts of interest.

## References

1. Cochran DL, Hermann JS, Schenk RK, Higginbottom FL, Buser D. Biologic width around titanium implants. A histometric analysis of the implanto-gingival junction around unloaded and loaded nonsubmerged implants in the canine mandible. J Periodontol 1997;68:186–198.
2. Berglundh T, Lindhe J, Ericsson I, Marinello CP, Liljenberg B, Thomsen P. The soft tissue barrier at implants and teeth. Clin Oral Implants Res 1991;2: 81–90.
3. Berglundh T, Lindhe J. Dimension of the periimplant mucosa. Biological width revisited. J Clin Periodontol 1996;23: 971–973.
4. Abrahamsson I, Berglundh T, Wennström J, Lindhe J. The peri-implant hard and soft tissues at different implant systems. A comparative study in the dog. Clin Oral Implants Res 1996;7:212–219.
5. Abrahamsson I, Berglundh T, Lindhe J. The mucosal barrier following abutment dis/reconnection. An experimental study in dogs. J Clin Periodontol 1997; 24:568–572.
6. Hermann JS, Buser D, Schenk RK, Higginbottom FL, Cochran DL. Biologic width around titanium implants. A physiologically formed and stable dimension over time. Clin Oral Implants Res 2000;11:1–11.
7. Hermann JS, Buser D, Schenk RK, Schoolfield JD, Cochran DL. Biologic width around one- and two-piece titanium implants. Clin Oral Implants Res 2001;12:559–571.
8. Gargiulo AW, Wentz FM, Orban B. Dimensions and relations of the dentogingival junction in humans. J Periodontol 1961;32:261–267.
9. Ricci JL, Grew JC, Alexander H. Connective-tissue responses to defined biomaterial surfaces. I. Growth of rat fibroblast and bone marrow cell colonies on microgrooved substrates. J Biomed Mater Res A 2008;85:313–325.
10. Grew JC, Ricci JL, Alexander H. Connective-tissue responses to defined biomaterial surfaces. II. Behavior of rat and mouse fibroblasts cultured on microgrooved substrates. J Biomed Mater Res A 2008;85:326–335.
11. Dumas V, Rattner A, Vico L, et al. Multiscale grooved titanium processed with femtosecond laser influences mesenchymal stem cell morphology, adhesion, and matrix organization. J Biomed Mater Res A 2012;100:3108–3116.
12. Wang RC, Hsieh MC, Lee TM. Effects of nanometric roughness on surface properties and fibroblast's initial cytocompatibilities of Ti6Al4V. Biointerphases 2011;6:87.
13. Nevins M, Nevins ML, Camelo M, Boyesen JL, Kim DM. Human histologic evidence of a connective tissue attachment to a dental implant. Int J Periodontics Restorative Dent 2008;28:111–121.
14. Nevins M, Camelo M, Nevins ML, Schupbach P, Kim DM. Connective tissue attachment to laser-microgrooved abutments: A human histologic case report. Int J Periodontics Restorative Dent 2012;32:385–392.



© 2019 BY QUINTESSENCE PUBLISHING CO, INC. PRINTING OF THIS DOCUMENT IS RESTRICTED TO PERSONAL USE ONLY.
NO PART MAY BE REPRODUCED OR TRANSMITTED IN ANY FORM WITHOUT WRITTEN PERMISSION FROM THE PUBLISHER.

15. Geurs NC, Vassilopoulos PJ, Reddy MS. Histologic evidence of connective tissue integration on laser microgrooved abutments in humans. Clin Adv Periodont 2011;1:29–33.
16. Iglhaut G, Schwarz F, Winter RR, Mihatovic I, Stimmelmayr M, Schliephake H. Epithelial attachment and downgrowth on dental implant abutments—A comprehensive review. J Esthet Restor Dent 2014;26:324–331.
17. Berglundh T, Abrahamsson I, Welander M, Lang NP, Lindhe J. Morphogenesis of the peri-implant mucosa: An experimental study in dogs. Clin Oral Implants Res 2007;18:1–8.
18. Mombelli A, van Oosten MA, Schurch E Jr, Land NP. The microbiota associated with successful or failing osseointegrated titanium implants. Oral Microbiol Immunol 1987;2:145–151.
19. Ainamo J, Löe H. Anatomical characteristics of gingiva. A clinical and microscopic study of the free and attached gingiva. J Periodontol 1966;37:5–13.
20. Sicher H. Changing concepts of the supporting dental structures. Oral Surg Oral Med Oral Pathol 1959;12:31–35.
21. Cohen DW. Pathogenesis of Periodontal Disease and Its Treatment. Washington DC: Walter Reed Army Medical Center, 1962.
22. Vacek JS, Gher ME, Assad DA, Richardson AC, Giambarresi LI. The dimensions of the human dentogingival junction. Int J Periodontics Restorative Dent 1994;14:155–165.
23. Hermann JS, Jones AA, Bakaeen LG, Buser D, Schoolfield JD, Cochran DL. Influence of a machined collar on crestal bone changes around titanium implants: A histometric study in the canine mandible. J Periodontol 2011;82:1329–1338.
24. Lindhe J, Berglundh T. The interface between mucosa and implant. Periodontol 2000 1998;17:47–54.
25. Listgarten MA. Soft and hard tissue response to endosseous dental implants. Anat Rec 1996;245:410–425.
26. Squier CA, Collins P. The relationship between soft tissue attachment, epithelial downgrowth and surface porosity. J Periodontal Res 1981;16:434–440.
27. Chehroudi B, Gould TR, Brunette DM. The role of connective tissue in inhibiting epithelial downgrowth on titanium-coated percutaneous implants. J Biomed Mater Res 1992;26:493–515.
28. Lang NP, Wetzel AC, Stich H, Caffesse RG. Histologic probe penetration in healthy and inflamed peri-implant tissues. Clin Oral Implants Res 1994;5:191–201.
29. Clark P, Connolly P, Curtis AS, Dow JA, Wilkinson CD. Topographical control of cell behaviour: II. Multiple grooved substrata. Development 1990;108:635–644.
30. Weiss P, Garber B. Shape and movements of mesenchyme cells as functions of the physical structure of the medium. Contribution to quantitative morphology. Proc Natl Acad Sci U S A 1952;38:264–280.
31. Lang NP, Löe H. The relationship between the width of keratinized gingiva and gingival health. J Periodontol 1972;43:623–627.



© 2019 BY QUINTESSENCE PUBLISHING CO, INC. PRINTING OF THIS DOCUMENT IS RESTRICTED TO PERSONAL USE ONLY.
NO PART MAY BE REPRODUCED OR TRANSMITTED IN ANY FORM WITHOUT WRITTEN PERMISSION FROM THE PUBLISHER.