



Influence of the Microgap/Interface Vertical Position on Early Marginal Bone Remodeling Around One-Stage Implants with Laser-Microtextured Collar Surface: A Randomized Clinical Study



Renzo Guarnieri, MD, DDS[1]
Dario Di Nardo, DDS, PhD[1]
Gianni Di Giorgio, DDS, PhD[1]
Gabriele Miccoli, DDS, PhD[1]
Luca Testarelli, DDS, PhD[1]

The aim of the present randomized study was to radiographically evaluate the early marginal bone remodeling (EMBR) around one-stage implants with a collar surface that is laser-microtextured (LM), placed with the mirograp/interface at different levels relative to the bone crest, and to clinically evaluate the influence of keratinized tissue thickness (KTT) on outcomes. Thirty partially edentulous patients were selected to each receive at least two one-stage implants with LM collars placed at different depth levels in the mandible and maxilla: one implant placed at an equicrestal level (E group) and one implant placed at a supracrestal level (SP group). Rank-based analysis of variance test was used for statistical comparison between groups. Before loading, the E and SP groups showed a mean marginal bone loss of 0.03 ± 0.04 mm and 0.02 ± 0.03 mm, respectively, without a statistically significant difference (P > .05) between the groups. Moreover, no statistically significant correlation between EMBR and the amount of KTT was found (P > .05). Within the limitations of the present study, it can be concluded that neither the vertical position of the microgap/interface of one-stage implants with an LM surface nor the thickness of keratinized tissue around the implant site influences the amount of EMBR.
Int J Periodontics Restorative Dent 2019;39:xxx–xxx. doi: 10.11607/prd.3420

[1]Department of Dental and Maxillofacial Sciences, School of Dentistry, University La Sapienza, Rome, Italy.

Correspondence to: Dr Renzo Guarnieri, via A Moro 3, 31022 Preganziol TV, Italy.
Email: renzoguarnieri@gmail.com

Submitted April 14, 2017; accepted August 24, 2017.
©2019 by Quintessence Publishing Co Inc.

Implant marginal bone loss represents one of the most investigated factors in implant dentistry.[1] Although its etiology is not completely clear,[2] it is known that the total amount of marginal bone loss depends on bone remodeling that occurs early after implant installation and loss that occurs during implant function.[3] Early marginal bone remodeling (EMBR) around one-stage implants has been shown to depend on the implant collar surface and the location of the microgap/interface (M/I) in relation to the alveolar crest.[4,5] Since bacterial colonization of the peri-implant tissues occurs within minutes of implant placement,[6] early resorption of the crestal bone could be related to the presence of M/I microbial contamination. Several studies indicated an association between the location of the M/I relative to the bone crest and the density of inflammatory cell infiltrate, which is in turn associated with the amount of bone loss.[7–9] Other factors that have been shown to influence the degree of EMBR include implant neck design and surface characterization.[10,11] In an effort to minimize EMBR, new surfaces and treatments for the implant neck have been proposed. One of these, a new implant collar surface, is obtained by means of laser ablation, resulting in circumferential microgrooves on the implant neck (Fig 1).



Fig 1 *Laser microgrooves 8 µm in pitch on the implant collar* (left)*, and one-stage implant* (right).

Histologic research on humans and animals[12–14] has shown that laser-microtextured (LM) surfaces promote the formation of a physical connective tissue attachment with connective fibers perpendicularly oriented to the implant collar. To the best of the authors' knowledge, there are no data in the literature investigating the influence of the vertical position, relative to bone crest, of the M/I of implants with an LM collar surface on EMBR. Therefore, this study was planned to compare EMBR around one-stage implants with LM collars placed equicrestally and supracrestally. The influence of keratinized tissue thickness (KTT) on EMBR was also evaluated.

Materials and Methods

Thirty partially edentulous patients, who required implant therapy for prosthetic rehabilitation of at least two adjacent edentulous sites in the posterior area of the mandible or maxilla, were identified and enrolled in this study. Criteria for inclusion were: age ≥ 18 years; good general health; and sufficient amount of bone available to place a standard implant (3.8-mm diameter and 9-mm length), detectable by means of cone beam computed tomography (CBCT) evaluation. Exclusion criteria were: natural teeth adjacent to surgical area affected by untreated periodontal or endodontic infections; peri-implant bone defects requiring bone augmentation; absence of opposing occlusion; full-mouth plaque score (FMPS) ≥ 25% and full-mouth bleeding score (FMBS) ≥ 25% recorded at the time of implant placement; parafunctional habits; severe maxilla/mandibular space discrepancies; uncontrolled diabetes and treatment with bisphosphonates; patients smoking > 10 cigarettes a day; and any drug/alcohol abuse. All patients were informed about the evidence-based, positive outcome of implant treatment and the experimental approach of implant-placement depths being tested. Each patient signed an informed consent form after receiving detailed information about the study. Treatments were performed according to the principles outlined in the Declaration of Helsinki on experimentation involving human subjects. A total of 60 implants were planned and divided into two groups: Group E (30 implants) with equicrestal placement, and Group SP (30 implants) with supracrestal placement. The equicrestal and supracrestal placements were randomly assigned (mesial/distal) to each patient. A researcher not involved with the implant surgery used a computer-generated random-number table for site allocation and secured the implant information in sealed, opaque envelopes. KTT at the implant placement sites was recorded before the surgical procedures by an examiner blinded to the treatments provided. The blinded examiner previously underwent a calibration session for better reproducibility of the measurements performed. The KTT was measured at each implant site by means of a no. 30 K-file (Kerr) inserted until touching the bone crest. The KTT was dichotomized into two groups (≤ 2 mm and > 2 mm) in accordance with the results of an animal study performed by Berglundh et al, which was the first attempt to analyze the influence of mucosal thickness on marginal bone loss.[15]

Implants

Tapered Tissue Level Laser-Lok implants (BioHorizons) were used for the study. The implant body is grit-blasted to create a moderately rough surface (roughness: 0.72 to 1.34 µm), while the apical 2.0 mm



Fig 2 *Equicrestal implant placement (1 mm of LM is placed supracrestally and 1 mm is placed subcrestally).*



Fig 3 *Supracrestal implant placement (2 mm of LM are placed supracrestally).*

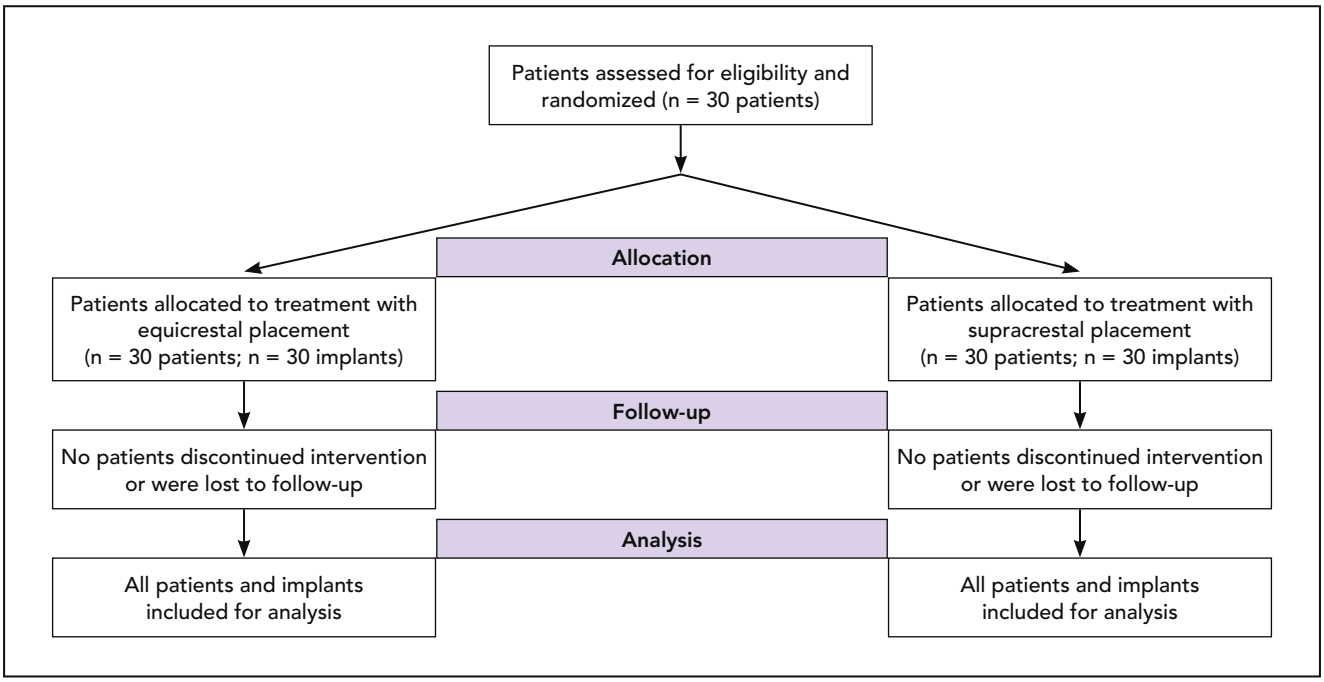

Fig 4 *Patient screening, recruitment, and allocation chart.*

of the collar is characterized by the presence of laser-produced microgrooves about 8 µm in size, and the most coronal 1.3 mm of the collar is smooth, machined metal (Fig 1). One-stage protocol was followed, and 30 implants were placed equicrestally according to the manufacturer's indications (ie, with 1 mm of the LM surface above the bone crest and 1 mm below the bone crest) (Fig 2), and 30 implants were placed supracrestally (ie, with 2 mm of the LM surface over the bone crest) (Fig 3). Treatment allocation is summarized in Fig 4.

Surgical Procedure

All implants were placed by the same operator (R.G.). All subjects adopted an antimicrobial prophylaxis routine consisting of 1-minute rinses with 0.12% chlorhexidine mouthrinse (Dentosan 0.12%, Johnson

& Johnson) before surgery and three times a day for the following 10 days. Amoxicillin/clavulanic acid (1 g twice a day; Augmentin, Glaxo-SmithKline) was prescribed for 7 days. Local anesthesia was induced by infiltration with articaine/epinephrine (1:100,000) (Ecocain 20 mg/mL, Molteni Dental). Crestal incisions were made with maximum effort to maintain the periodontal tissues of adjacent teeth; vertical release incisions were made only if necessary for obtaining better visibility. A full-thickness flap was reflected buccally and lingually to expose the alveolar ridge of each implant site. The preparation of the recipient site was performed following the implant manufacturer's instructions, under abundant saline solution irrigation. A single-stage surgery with a nonsubmerged healing approach was performed in all sites. Closure of the flap was obtained without tension using 4.0 or 5.0 monofilament sutures. Patients were instructed to have a liquid or semiliquid diet for the first 3 days and then gradually return to a normal diet. An analgesic (ibuprofen, 600 mg) was prescribed immediately after surgical intervention and again 8 hours later.

Radiographic Examination

Radiographs were taken immediately and 6 months after surgery (T0 and T6, respectively) with a paralleling technique using a Rinn film holder with a rigid object-film distance from the x-ray source. For the radiograph procedure, a silicone index material was fixated to the residual dentition and a radiograph holder was constructed for each patient. This technique ensured that the same position of the radiograph film could be reproduced at each visit and the angle of the radiograph would not deviate. The radiographs were taken in high resolution (Vista Scan Durr Dental, Durr Dental) with a dental x-ray machine (TM 2002 Planmeca Proline CC, Planmeca Group) equipped with a long tube that operated at 70 Kw/7.5 mA. Specialized software (DBSWIN software, Durr Dental) was used for linear measurements of marginal bone changes. The following radiographic measurements were performed:

Radiographic implant length (IL): distance (in mm) between the implant shoulder and the implant apex as assessed at the midportion of the implant

Residual bone height at the mesial (mBH) and distal (dBH) aspects of the implant: distance (in mm) between the implant shoulder and the first contact of the crestal bone on the mesial or distal side of the implant

To account for radiographic distortion, the measurements (ie, mBH, dBH) on each radiograph were adjusted for a coefficient derived from the ratio: true length of the implant/IL. For each implant, the marginal bone loss (MBL) was calculated as the mean value of mBH and dBH. All measurements were carried out by a single trained examiner (L.T.) who had previously undergone a calibration session for radiographic assessment of a sample of 10 patients treated with the same implant system but not included in the study (kappa = 0.940; standard error of kappa = 0.042; 95% confidence interval: 0.857 to 1.000). In the present study, means and standard deviations were obtained for all samples in each group.

Statistical Analyses

Early MBL and KTT were compared between equicrestal and supracrestal implants using SPSS statistical program, version 13.0 (IBM). Results were expressed as mean, standard deviation, median, and range. Rank-based analysis of variance (ANOVA) statistical test was used to compare implant placement depths (E vs SP) and KTT at T0 and T6.

Results

Following treatment, all 30 patients returned for the 6-month evaluation. No implants were lost and no signs of inflammation were detected during the period of the study. At the the 6-month follow-up (T6), Group E showed a mean MBL of 0.03 ± 0.04 mm, while the mean MBL in Group SP was 0.02 ± 0.03 mm. Crestal bone changes between equicrestal and supracrestal implants showed similar values, with no statistically significant difference ($P > .05$). In both groups, the change in MBL from T0 to T6 was statistically significant ($P < .05$) (Table 1). The influence of KTT on MBL, assessed at the T6 examination, was not significant ($P > .05$): implants from Groups E and SP placed in sites with KTT ≤ 2 mm had mean MBL values of

Table 1 EMBL for Both Groups in the Different Evaluation Times

Evaluation times	Equacrestal (E) group (n = 30 equicrestal implants)		Supracrestal (SP) group (n = 30 supracrestal implants)		*P** (E vs SP)
	Mean ± SD	Median (min–max)	Mean ± SD	Median (min–max)	
T0	1.07 ± 0.04	1.08 (1.01–1.16)	2.06 ± 0.44	2.07 (1.94–2.15)	
T6	1.10 ± 0.41	1.09 (1.03–1.18)	2.08 ± 0.37	2.09 (2.02–2.16)	**0.2177**
*P** (T0–T6)	< .0261				

EMBL = early marginal bone loss; SD = standard deviation; T0 = implant placement; T6 = after 6 months.
*Rank-based ANOVA test.

Table 2 EMBL for Both Groups in the Different Evaluation Times According to the KTT

	Equacrestal group (n = 30 implants)		Supracrestal group (n = 30 implants)	
	Mean ± SD	Median (min–max)	Mean ± SD	Median (min–max)
KTT ≤ 2 mm	(n = 8 implants)		(n = 8 implants)	
T0	1.08 ± 0.05	1.09 (1.05–1.19)	2.05 ± 0.04	2.04 (2.01–2.13)
T6	1.10 ± 0.05	1.11 (1.05–1.19)	2.08 ± 0.04	2.08 (2.04–2.167
Significance*	*P* = .0736		*P* = .0964	
KTT > 2 mm	(n = 22 implants)		(n = 22 implants)	
T0	1.07 ± 0.55	1.08 (1.03–1.15)	2.06 ± 0.45	2.07 (1.94–2.15)
T6	1.09 ± 0.31	1.09 (1.06–1.17)	2.08 ± 0.03	2.09 (2.02–2.14)
Significance*	*P* = .1124		*P* = .0894	

EMBL = early marginal bone loss; SD = standard deviation; T0 = implant placement; T6 = after 6 months; KTT = keratinized tissue thickness.
*Rank-based ANOVA test.

0.02 mm and 0.03 mm, respectively; when placed in sites with KTT > 2 mm, both groups had mean MBL values of 0.02 mm (Table 2). EMBL changes from T0 to T6 are shown in Figs 5 and 6.

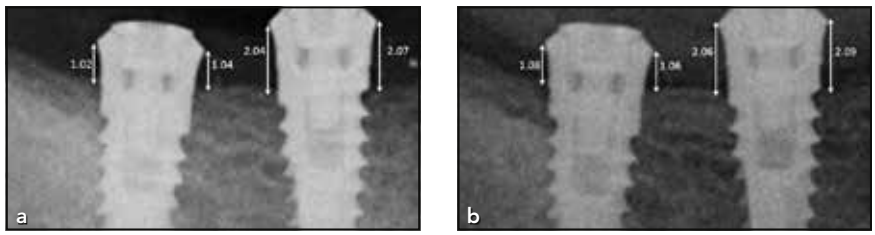

Fig 5 *EMBL measurements (in mm)* (a) *immediately after surgery and* (b) *6 months after surgery for sub- and equicrestal implants (patient 17).*

Discussion

This study aimed to radiographically evaluate the influence of the vertical position of the M/I with an LM implant collar surface on EMBR. To achieve this, one-stage Laser-Lok implants were inserted equicrestally and supracrestally to allow varying vertical placement of

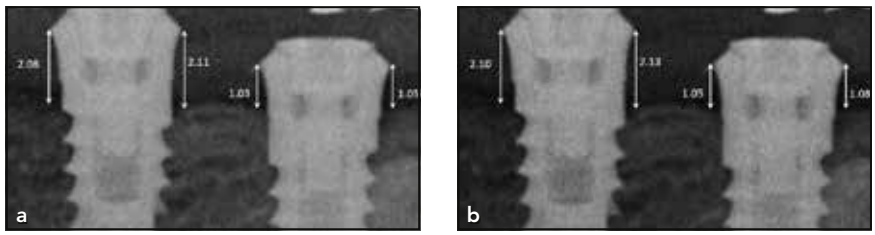

Fig 6 *EMBL measurements (in mm)* (a) *immediately after surgery and* (b) *6 months after surgery for sub- and equicrestal implants (patient 24).*

the M/I relative to bone crest. Few studies, mostly on animal models, have evaluated the influence of different implant collar surfaces and depths on EMBR around one-stage implants.[16,17] Hermann et al[16] conducted a histologic study comparing sandblasted, large-grit, and HCL/H_2SO_4 dual acid-etched (SLA) surfaces to machined surfaces in an animal model. The results showed that EMBR can be significantly reduced with roughened-surface one-stage implants placed 1 mm above the bone crest. At the same M/I vertical position, one-stage implants sprayed/roughened all the way to the collar performed better than implants with machined collars. Another comparative study by Alomrani et al[17] radiographically evaluated the influence of SLA vs machined-collar surfaces on EMBR around one-stage implants placed at different heights relative to the bone crest. The results showed that when the position of the M/I was above the crest, SLA-collar surfaces had less MBL. The previously mentioned studies suggest that EMBR is associated with both the location of M/I and the type of collar surface, emphasizing that a structured surface close to the microgap may have advantages in regards to minimizing bone loss. The EMBR that occurs after implant placement may be related to the biologic width associated with implants.[18] It is likely safe to assume that the structure and biologic dimensions of the peri-implant width are influenced by the collar surface. In animal and human histologic studies,[12–14] machined/smooth-collar surfaces showed a parallel organization of the connective tissue fibers with respect to the surface,[19,20] as compared to a perpendicular/functional organization of connective tissue fibers around LM collar surfaces.[12–14] This perpendicular arrangement seems to be determined by the laser microgrooves layout. Preliminary in vitro studies[21–25] on LM surfaces showed high potential for fibroblast growth, effective inhibition of epithelial cell migration across the grooves around the 8-µm grooves, and more extensive bone ingrowth, osteoblast attachment, and directional control of bone attachment around the 12-µm grooves compared to blast-textured surfaces. Based on these results, it was hypothesized that this kind of microgeometry on collar surfaces could be used to control soft and hard tissue responses to dental implants. The first generation of LM implants was designed with a 0.3-mm coronal section of turned surface to potentially inhibit or reduce the adhesion of oral bacteria and plaque, a 0.7-mm middle section of 8-µm microgrooves to potentially create a physical connective tissue attachment, and a 0.8-mm section of 12-µm microgrooves to potentially have an extensive bone attachment. Histologic research in animal models and in humans[12–14] have afterwards confirmed the aforementioned hypothesis, documenting the effect of LM implant collars on peri-implant tissues. Similar histologic results have also been documented around LM healing and prosthetic abutments with an 8-µm pitch.[26–30] For the one-stage LM implants used in the present study, the collar height was 3.3 mm and comprised of two sections: a 1.3-mm coronal machined section and a 2.0-mm apical, 8-µm microgrooved section. Since M/I is considered one of the potential factors affecting EMBL around one-stage implants, the effect of its vertical placement in the present study was combined with that of an LM collar surface. One-stage LM implants placed equicrestally and supracrestallly showed similar mean MBL values (0.3 ± 0.04 mm vs 0.02 ± 0.03 mm), with no statistically significant difference ($P > .05$). These results suggest that LM implant collars may limit the amount of EMBR, regardless of the distance from M/I to the bone crest. Moreover, regardless of the level of placement (equicrestal or supracrestal), similar mean values of EMBR were observed around one-stage LM implants placed in sites with thin vs thick keratinized mucosa. Reported data from the literature regarding the influence of KTT on MBL are scarce and contrasting. Studies by Adibrad et al,[31] Chung et al,[32] and de Siqueira et al[33] failed to reveal significant difference in marginal bone loss between implants placed in sites with KTT > 2 mm and ≤ 2 mm. On the contrary, Bouri et al,[34] Kim et al,[35] and Linkevicius et al[36] found that the mean marginal bone loss was higher for implants placed in sites with KTT < 2 mm. The absence in the present study of comparative histologic data regarding implant/tissue interface makes it difficult to assess how a LM surface placed at the supracrestal or equicrestal level interacts with peri-implant tissues. However, a possible explanation of the results of this

study related to KTT would be that LM collar surfaces have the ability to promote a physical connective tissue attachment during healing, regardless of the thickness of keratinized mucosa at the implant site. Further histologic research is needed to confirm this hypothesis. One important limitation of the present study is the absence of a control group to include implants with no LM collars. However, preliminary results of clinical studies such as this one often represent the first line of clinical evidence, which underscores their clinical value.

Conclusions

Within the limitations of the present study, it can be concluded that one-stage implants with LM collars placed equicrestally and supracrestally do not show differences in EMBR, regardless of the amount of KTT present in the implant site. Therefore, the placement depths of one-stage implants with LM surface can be chosen based on synergistic action of other factors required for successful implant treatment (ie, anatomic conformation of bone crest, location of interdental papilla, type of prosthetic component, emergency profile, etc).

Acknowledgments

The authors report no conflicts of interest related to this study. The study was supported by BioHorizons (Birmingham, Alabama, USA), who provided the materials. Drs Guarnieri and Testarelli contributed substantially to the research design and draft of the manuscript. Drs Di Nardo, Di Giorgio, and Miccoli worked on data acquisition and analysis. All authors helped with data interpretation and critical review of the manuscript.

References

1. Ting M, Tenaglia MS, Jones GH, Suzuki JB. Surgical and patient factors affecting marginal bone levels around dental implants: A comprehensive overview of systematic reviews. Implant Dent 2017; 26:303–315.
2. Albrektsson T, Dahlin C, Jemt T, Sennerby L, Turri A, Wennerberg A. Is marginal bone loss around oral implants the result of a provoked foreign body reaction? Clin Implant Dent Relat Res 2014;16:155–165.
3. Qian J, Wennerberg A, Albrektsson T. Reasons for marginal bone loss around oral implants. Clin Implant Dent Relat Res 2012;14:792–807.
4. Hermann JS, Cochran DL, Nummikoski PV, Buser D. Crestal bone changes around titanium implants. A radiographic evaluation of unloaded nonsubmerged and submerged implants in the canine mandible. J Periodontol 1997; 68:1117–1130.
5. Hermann JS, Buser D, Schenk RK, Cochran DL. Crestal bone changes around titanium implants. A histometric evaluation of unloaded non-submerged and submerged implants in the canine mandible. J Periodontol 2000;71: 1412–1424.
6. Furst MM, Salvi GE, Lang NP, Persson GR. Bacterial colonization immediately after installation on oral titanium implants. Clin Oral Implants Res 2007; 18:501–508.
7. Jansen VK, Conrads G, Richter EJ. Microbial leakage and marginal fit of the implant-abutment interface. Int J Oral Maxillofac Implants 1997;12:527–540.
8. Broggini N, McManus LM, Hermann JS, et al. Peri-implant inflammation defined by the implant-abutment interface. J Dent Res 2006;85:473–478.
9. Persson LG, Lekholm U, Leonhardt A, Dahlén G, Lindhe J. Bacterial colonization on internal surfaces of Brånemark system. Clin Oral Implants Res 1996;7: 90–95.
10. Koodaryan R, Hafezeqoran A. Evaluation of implant collar surfaces for marginal bone loss: A systematic review and meta-analysis. Biomed Res Int 2016;2016:4987526.
11. Bateli M, Att W, Strub JR. Implant neck configurations for preservation of marginal bone level: A systematic review. Int J Oral Maxillofac Implants 2011;26: 290–303.
12. Nevins M, Nevins ML, Camelo M, Boyesen JL, Kim DM. Human histologic evidence of a connective tissue attachment to a dental implant. Int J Periodontics Restorative Dent 2008;28:111–121.
13. Weiner S, Simon J, Ehrenberg DS, Zweig B, Ricci JL. The effects of laser microtextured collars upon crestal bone levels of dental implants. Implant Dent 2008;17:217–228.
14. Shin SY, Han DH. Influence of a microgrooved collar design on soft and hard tissue healing of immediate implantation in fresh extraction sites in dogs. Clin Oral Implants Res 2010;21:804–814.
15. Berglundh T, Abrahamsson I, Welander M, Lang NP, Lindhe J. Morphogenesis of the peri-implant mucosa: An experimental study in dogs. Clin Oral Implants Res 2007;18:1–8.
16. Hermann JS, Jones AA, Bakaeen LG, Buser D, Schoolfield JD, Cochran D. Influence of a machined collar on crestal bone changes around titanium implants: A histometric study in the canine mandible. J Periodontol 2011;82: 1329–1338.
17. Alomrani AN, Hermann JS, Jones AA, Buser D, Schoolfield J, Cochran DL. The effect of a machined collar on coronal hard tissue around titanium implants: A radiographic study in the canine mandible. Int J Oral Maxillofac Implants 2005;20:677–686.
18. Cochran DL, Hermann JS, Schenk RK, Higginbottom FL, Buser D. Biologic width around titanium implants. A histometric analysis of the implanto-gingival junction around unloaded and loaded nonsubmerged implants in the canine mandible. J Periodontol 1997;68: 186–198.
19. Schupbach P, Glauser R. The defense architecture of the human periimplant mucosa: A histological study. J Prosthet Dent 2007;97(6 suppl):s15–s25.
20. Degidi M, Piattelli A, Scarano A, Shibli JA, Iezzi G. Peri-implant collagen fibers around human cone Morse connection implants under polarized light: A report of three cases. Int J Periodont Restor Dent 2012;32:323–328.

21. Dalby MJ, Riehle MO, Johnstone H, Affrossman S, Curtis AS. Investigating the limits of filopodial sensing: A brief report using SEM to image the interaction between 10 nm high nano-topography and fibroblast filopodia. Cell Biol Int 2004;28:229–236.
22. Wang RC, Hsieh MC, Lee TM. Effects of nanometric roughness on surface properties and fibroblast's initial cytocompatibilities of Ti6Al4V. Biointerphases 2011;6:87.
23. Ricci JL, Grew JC, Alexander H. Connective-tissue responses to defined biomaterial surfaces. I. Growth of rat fibroblast and bone marrow cell colonies on microgrooved substrates. J Biomed Mater Res A 2008;85:313–325.
24. Grew JC, Ricci JL, Alexander H. Connective-tissue responses to defined biomaterial surfaces. II. Behavior of rat and mouse fibroblasts cultured on microgrooved substrates. J Biomed Mater Res A 2008;85:326–335.
25. Dumas V, Rattner A, Vico L, et al. Multiscale grooved titanium processed with femtosecond laser influences mesenchymal stem cell morphology, adhesion, and matrix organization. J Biomed Mater Res A 2012;100:3108–3116.
26. Nevins M, Camelo M, Nevins ML, Schupbach P, Kim DM. Connective tissue attachment to laser-microgrooved abutments: A human histologic case report. Int J Periodontics Restorative Dent 2012;32:385–392.
27. Nevins M, Kim DM, Jun SH, Guze K, Schupbach P, Nevins ML. Histologic evidence of a connective tissue attachment to laser microgrooved abutments: A canine study. Int J Periodontics Restorative Dent 2010;30:245–255.
28. Nevins M, Nevins ML, Camelo M, Boyesen JL, Kim DM. Human histologic evidence of a connective tissue attachment to a dental implant. Int J Periodontics Restorative Dent 2008;28:111–121.
29. Geurs NC, Geisinger ML, Vassilopoulos PJ, O'Neal SJ, Haigh SJ, Reddy MS. Optimizing connective tissue integration on laser-ablated implant abutments. Clin Adv Periodontics 2016;6:153–159.
30. Geurs NC, Vassilopoulos PJ, Reddy MS. Histologic evidence of connective tissue integration on laser microgrooved abutments in humans. Clin Adv Periodontics 2011;1:29–33.
31. Adibrad M, Shahabuei M, Sahabi M. Significance of the width of keratinized mucosa on the health status of the supporting tissue around implants supporting overdentures. J Oral Implantol 2009;35:232–237.
32. Chung DM, Oh TJ, Shotwell JL, Misch CE, Wang HL. Significance of keratinized mucosa in maintenance of dental implants with different surfaces. J Periodontol 2006;77:1410–1420.
33. de Siqueira RAC, Fontão FNGK, Sartori IAM, Santos PGF, Bernardes SR, Tiossi R. Effect of different implant placement depths on crestal bone levels and soft tissue behavior: A randomized clinical trial. Clin Oral Implants Res 2017; 28:1227–1233.
34. Bouri A Jr, Bissada N, Al-Zahrani MS, Faddoul F, Nouneh I. Width of keratinized gingiva and the health status of the supporting tissues around dental implants. Int J Oral Maxillofac Implants 2008;23:323–326.
35. Kim BS, Kim YK, Yun PY, et al. Evaluation of peri-implant tissue response according to the presence of keratinized mucosa. Oral Surg Oral Med Oral Pathol Oral Radiol Endod 2009;107:e24–e28.
36. Linkevicius T, Apse P, Grybauskas S, Puisys A. The influence of soft tissue thickness on crestal bone changes around implants: A 1-year prospective controlled clinical trial. Int J Oral Maxillofacial Implants 2009;24:712–719.