A Retrospective Multicenter Study on Short Implants With a Laser-Microgrooved Collar (≤7.5 mm) in Posterior Edentulous Areas: Radiographic and Clinical Results up to 3 to 5 Years

Francesco Zuffetti, MD, DDS, * *Luca Testarelli, DDS, PhD,* † *Pio Bertani, MD, DDS,* ‡ *Spyridon Vassilopoulos, DDS, PhD,* § *Tiziano Testori, MD, DDS,* ‖ *and Renzo Guarnieri, MD, DDS* ¶

Purpose: We aimed to retrospectively evaluate the radiographic and clinical results and the success rate of short implants with a laser-microgrooved collar (≤7.5 mm) placed in the posterior areas after up to 3 to 5 years of function and the possible influence of several variables—such as gender, periodontitis, smoking habit, location, implant stability at placement, and prosthetic fixation design—on implant marginal bone loss (MBL).

Materials and Methods: A chart review was used for this multicenter study, which involved 5 private dental clinics. All patients had been treated with short dental implants with a laser-microgrooved collar from January 2012 to December 2015.

Results: A total of 174 patients (99 male and 75 female patients; mean age, 51.6 ± 2.8 years) with 254 implants were evaluated. Seven short implants failed. The cumulative success rate was 97.2%, without a statistically significant difference between implants placed in the posterior maxilla and mandible. The mean MBL was 0.18 ± 0.7 mm at the mesial aspect and 0.19 ± 0.6 mm at the distal aspect. No statistical relationships were found between MBL and gender, periodontitis, smoking habit, location, implant stability at placement, and prosthetic fixation design.

Conclusions: At the end of the 3- to 5-year follow-up period, short implants with a laser-microgrooved collar (≤7.5 mm) in the posterior areas yielded a relatively high cumulative success rate. The laser-microgrooved collar implant maintained stable marginal bone levels. No investigated variable was statistically associated with MBL.

© 2019 American Association of Oral and Maxillofacial Surgeons

J Oral Maxillofac Surg ■*:1.e1-1.e11, 2019*

*Assistant Professor, Section of Implant Dentistry and Oral Rehabilitation, IRCCS Galeazzi Institute, and Private Practice, Milan, Italy.

†Associate Professor, Department of Oral and Maxillofacial Sciences, La Sapienza University, and Private Practice, Rome, Italy.

‡Private Practice, Parma, Italy.

§Assistant Professor, Department of Periodontology, National and Kapodistrian University of Athens, and Private Practice, Athens, Greece.

‖Head of Section of Implantology and Oral Rehabilitation, Department of Odontology, IRCCS Galeazzi, University of Milan, Milan, Italy; Adjunct Clinical Associate Professor, Department of Periodontics and Oral Medicine, School of Dentistry, University of Michigan, Ann Arbor, MI; and Private Practice, Como, Italy.

¶Adjunct Professor, Department of Oral and Maxillofacial Sciences, La Sapienza University, Rome, and Private Practice, Treviso, Italy.

This study was supported by BioHorizons, which provided materials.

Conflict of Interest Disclosures: None of the authors have any relevant financial relationship(s) with a commercial interest.

Address correspondence and reprint requests to Dr Guarnieri: via L Cattarin 3D, 31100 Treviso, Italy; e-mail: renzoguarnieri@gmail.com

Received February 27 2019

Accepted August 7 2019

© 2019 American Association of Oral and Maxillofacial Surgeons

0278-2391/19/31005-5

https://doi.org/10.1016/j.joms.2019.08.007

In patients with long-standing posterior edentulous jaws, the pneumatized maxillary sinus and the inferior alveolar canal often represent anatomic boundaries for the placement of standard-length implants.[1] Different surgical procedures have been proposed to augment the bone height in resorbed posterior jaws,[2,3] but they involve the risk of postoperative complications and increased treatment times and costs.[4,5] In the resorbed posterior areas of the jaws, the placement of short implants (SIs) could be an alternative and less invasive treatment. However, conflicting data are present on the clinical outcomes of SIs: Studies performed with machined-surface implants placed in compromised sites with poor bone quality and quantity have shown more early failures (before osseointegration)[6-8] and late failures[9-15] for SIs than for standard-length implants. Failures were frequently associated with the low-density bone of the atrophic posterior jaws and a high crown-to-implant (C/I) ratio, needed to achieve proper occlusion in vertically resorbed posterior areas. Nowadays, thanks to the introduction of rough-surface implants, which favor a higher bone-to-implant contact,[16] the predictability of SIs is significantly increased.[17-23] Recent systematic reviews have highlighted that SIs with a textured surface and standard-length implants have similar long-term success rates (SRs).[24-32]

Among clinicians, there is no unanimous consensus on the definition of "short implants" and on the SR according to the relative implant length.[33] When short is considered any implant with a length less than 10 mm, similar SRs compared with standard (≥10-mm) implants are reported, whereas lower SRs are reported when short is considered an implant with a length less than 7 mm.[19,21,24]

Peri-implant marginal bone loss (MBL) is an important indicator of peri-implant tissue health.[34] Several studies that have evaluated the MBL around SIs reported values similar to standard-length implants.[35-37] Although these values (maximum, 1.5 or 2 mm after 1 year, with 0.2 mm more for each subsequent year of function) are considered a successful outcome for standard-length implants, they should be interpreted differently for SIs. An MBL of 2 or 3 mm after 3 or 5 years of loading around an implant 6 or 7.5 mm in length, involving almost 30% or 50% of the bone support, could have a different prognostic significance for an SI compared with a longer implant. The specific criteria to define the success of SIs are missing, and factors that could specifically influence the MBL around SIs are still under investigation. Therefore, the first objective of this multicenters retrospective study was to clinically and radiographically evaluate the outcomes of SIs (≤7.5 mm) placed in the posterior maxilla and mandible after 3 to 5 years of follow-up. The second objective was to evaluate the possible influence of different variables on the implant SR and MBL.

Materials and Methods

The data were obtained from clinical and radiographic analyses performed in 5 private dental centers. All patients were previously treated as part of either an approved research protocol or routine implant treatment. Therefore, the study was granted an exemption by the local institutional review board. Each included patient was asked to sign an informed consent form, and the study was conducted in compliance with the Declaration of Helsinki.

The inclusion criteria were as follows:

- Patients aged 18 years or older
- Absence of medical conditions known as contraindications to implant surgery
- No abuse of alcohol or drugs
- Presence of resorbed posterior edentulous jaws requiring rehabilitation with prostheses supported by dental implants
- Presence of residual bone height to place an implant of at least 6 or 7.5 mm in length and residual bone width to place an implant of at least 4.6 mm in diameter detected on cone-beam computed tomography scans (Figs 1, 2).

The exclusion criteria were as follows:

- Patients with poor oral hygiene (full-mouth plaque score and full-mouth bleeding score ≥ 25%)
- Previous bone regenerative treatment at the surgical sites
- Patients who abandoned supportive therapy

When at least 3 mm of attachment loss and 30% of radiographic bone loss in 30% of sites were present, the patients were classified as periodontally compromised. Patients who had never smoked in their lives were categorized as never smokers, those who had quit smoking for at least 5 years were considered former smokers, and all other patients were considered current smokers. In all patients, full-mouth intraoral radiographs, cone-beam computed tomography scans, and diagnostic wax-up were used for the presurgical evaluations.

SURGICAL PROTOCOL

In all patients, after local infiltration of articaine/epinephrine (Ecocain, 20 mg/mL; Molteni Dental, Milan, Italy), a full-thickness flap was raised to expose the alveolar ridge. Implants were inserted following the manufacturer's recommendations. A No. 4.0 or 5.0

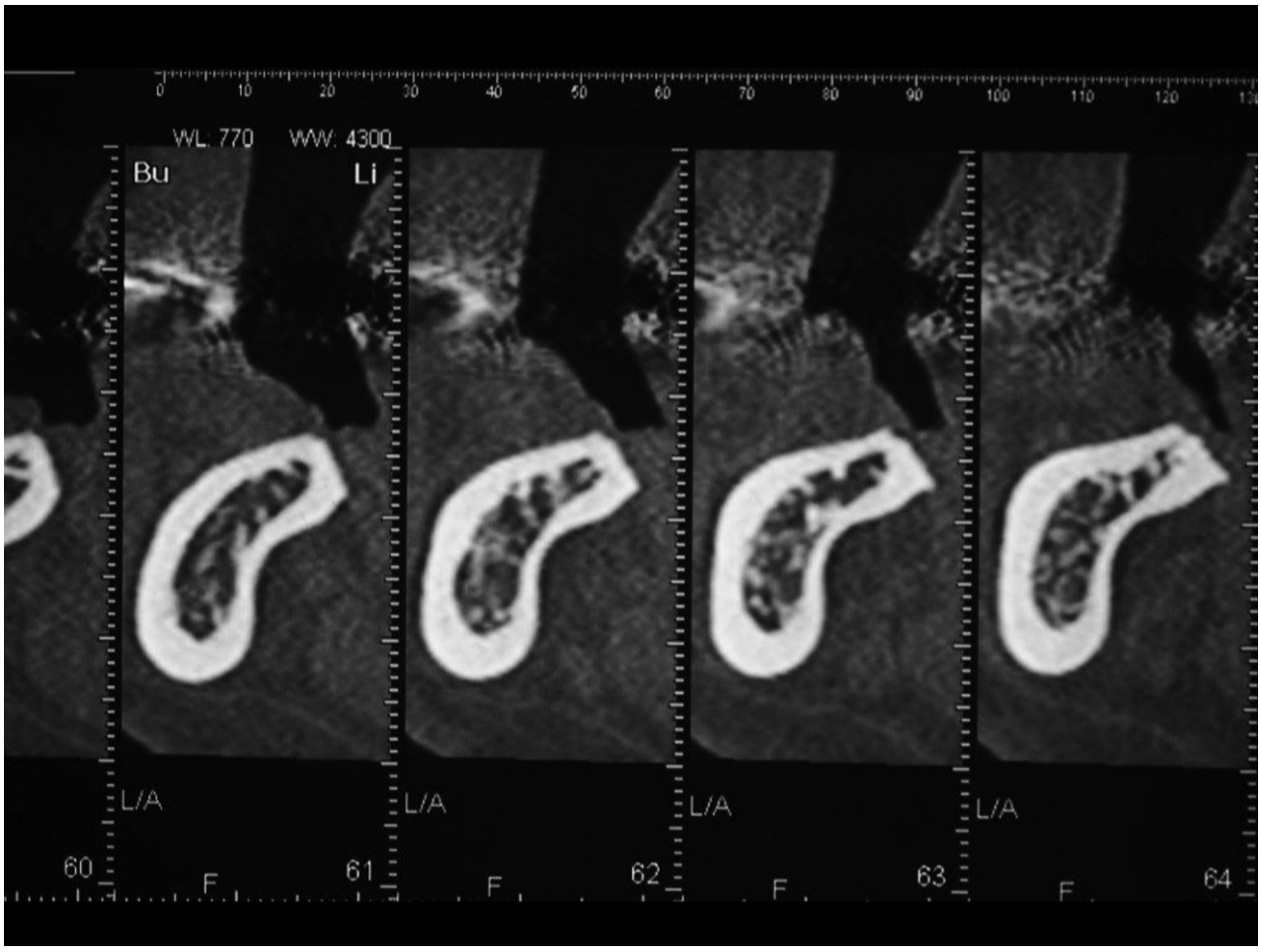

FIGURE 1. Cone-beam computed tomography scans used to evaluate residual bone height and width.

Zuffetti et al. Laser-Microgrooved Collar. J Oral Maxillofac Surg 2019.

monofilament was used to suture the flap. Systemic antibiotic therapy with amoxicillin, 875 mg/clavulanic acid, 125 mg (Augmentin; GlaxoSmithKline, Verona, Italy), was used 1 hour before surgery. Postoperative management included the continuation of antibiotic therapy (amoxicillin, 875 mg/clavulanic acid, 125 mg, twice a day for 7 days) and chlorhexidine gluconate 0.12% mouth rinses (Dentosan 0.12%; Johnson & Johnson, New Brunswick, NJ) (twice daily for 1 minute) for the first 4 weeks. An analgesic (ibuprofen, 600 mg) was prescribed to take immediately after surgery and after 8 hours. Sutures were removed 2 weeks after implant insertion. After 4 and 6 months, for implants placed in the mandible and maxilla, respectively, the healing abutment connection was performed. Four weeks later, definitive prosthetic abutments were connected, and definitive crowns were delivered.

In an attempt to assess primary stability, at the time of implant insertion, resonance frequency analysis (RFA) via the Osstell implant stability quotient (ISQ) system (Integration Diagnostic, Goteborg, Sweden) was used. The implant stability measured by means of the ISQ allows evaluation of the stiffness of the implant in the surrounding bony tissues, and this should correspond to histologic results.[38]

IMPLANTS

The investigated SIs had the following characteristics:

- Tapered body design with resorbable blast-textured (RBT) surface
- 1.8-mm laser-microgrooved collar with 8 μm in pitch
- Diameter of 4.6 mm and length of 6 mm (Tapered Short Laser-Lok; BioHorizons, Birmingham, AL)
- Diameter of 4.6 mm and length of 7.5 mm (Tapered Internal Laser-Lok; BioHorizons)

RESTORATIONS

Non-splinted implant-supported restorations were used in patients with decreased manual dexterity to

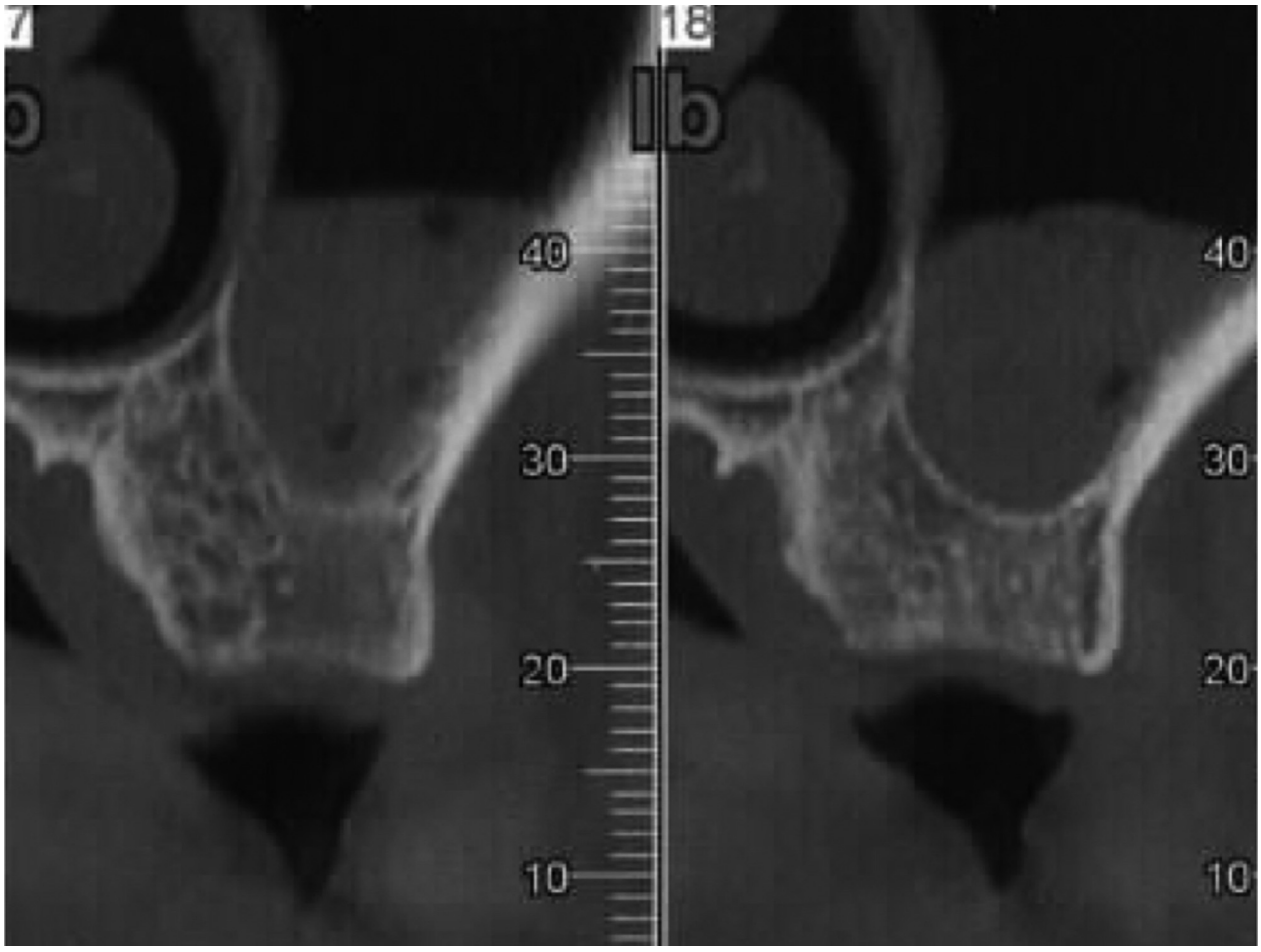

FIGURE 2. Cone-beam computed tomography scans used to evaluate residual bone height and width.

Zuffetti et al. Laser-Microgrooved Collar. J Oral Maxillofac Surg 2019.

facilitate oral hygiene maneuvers, whereas splinted implant-supported restorations were used in patients with a history of bruxism for the purpose of limiting forces applied to prosthetic components.

FOLLOW-UP

After crown delivery (baseline), patients were enrolled in a 6-month maintenance recall program. At each visit, a professional oral hygiene and clinical and/or radiographic examination was performed. The number of sites with plaque, number of sites with bleeding on probing, probing depth, mucosal recession, and mesial and/or distal radiographic peri-implant marginal bone levels were considered at baseline and every 6 months. Moreover, prosthesis mobility, pain, infection, and complications, if present, were recorded.

The absence of mobility, pain, infection, and radiolucency around the implant was considered a parameter of success. Implant loss, implant or screw fracture leading to prosthesis failure, bone loss greater than 3 mm, and lack of osseointegration were considered parameters of failure.

RADIOGRAPHIC EXAMINATION

Digital radiographs were taken with an individualized acrylic resin device fixed to the residual dentition and a radiograph holder (Figs 3-7). Radiographic measurements were calculated using a software program (VixWin Platinum Imaging Software; Gendex, Des Plaines, IL). The radiographic crown length was measured as the distance between the most coronal part of the implant collar and the most coronal part of the crown and was dichotomized into 2 groups: 0 to less 1 versus 1 or greater. Radiographically, MBL was assessed on the mesial and distal sides of each implant by subtracting the measure of MBL at baseline from the measure of MBL at 3- to 5-year follow-up. A dedicated software program (VixWin Platinum Imaging Software) was used to calculate the radiographic measurements.

ARTICLE IN PRESS

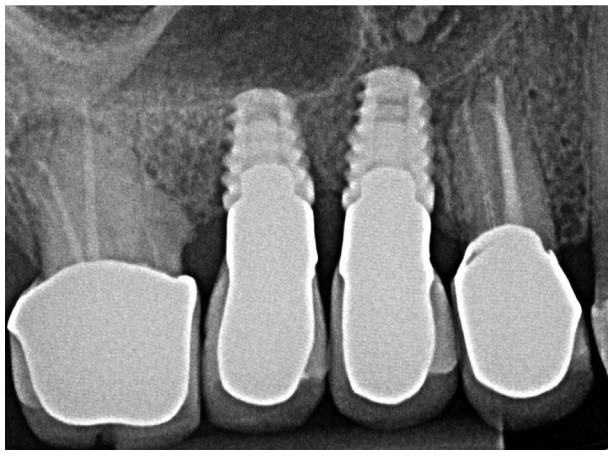

FIGURE 3. Radiograph of 2 short single implants placed in maxilla taken at baseline.

Zuffetti et al. Laser-Microgrooved Collar. J Oral Maxillofac Surg 2019.

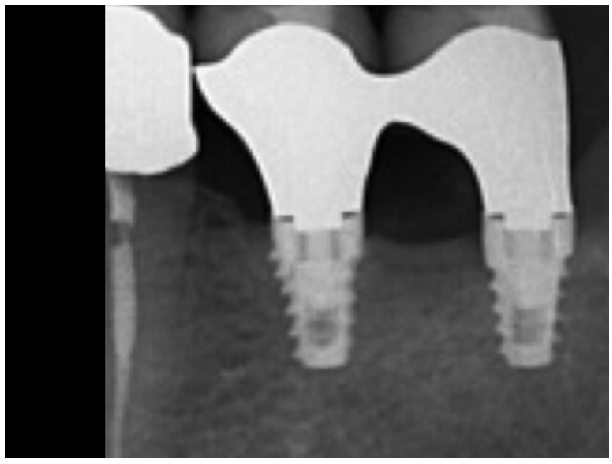

FIGURE 5. Radiograph of 2 short implants placed in mandible taken at baseline.

Zuffetti et al. Laser-Microgrooved Collar. J Oral Maxillofac Surg 2019.

EXAMINER CALIBRATION

For reproducibility of clinical and radiographic examinations, calibration of the examiner was performed by measuring the clinical and radiographic indices in the same 10 patients and on the same radiographs 1 week apart, achieving an intra-examination reliability of 90% (data not shown).

STATISTICAL ANALYSIS

One independent examiner collected and analyzed the data. Implants were used as units of analysis. Qualitative variables (patient's gender, smoking habit, implant location, ISQ value, prosthesis type [cemented or screw retained], and prosthesis design) were collected as absolute and relative frequency distributions. Quantitative variables (MBL and crown height) were collected as mean values and standard deviations. The potential statistical relationship between MBL and categorical variables was analyzed with the Mann-Whitney nonparametric test, whereas the potential statistical relationship between MBL and the quantitative variables was evaluated by means of a linear regression analysis. The potential statistical relationship between different variables and MBL was evaluated with Cox regression analysis. A confidence level of 95% ($P < .05$) was applied. The influence of each variable (gender, smoking habit, ISQ value, implant location, C/I ratio, and restoration design and fixation) simultaneously present was evaluated with multivariate analysis and the multiple linear regression test. The influence of each variable on MBL was determined by means of standardized

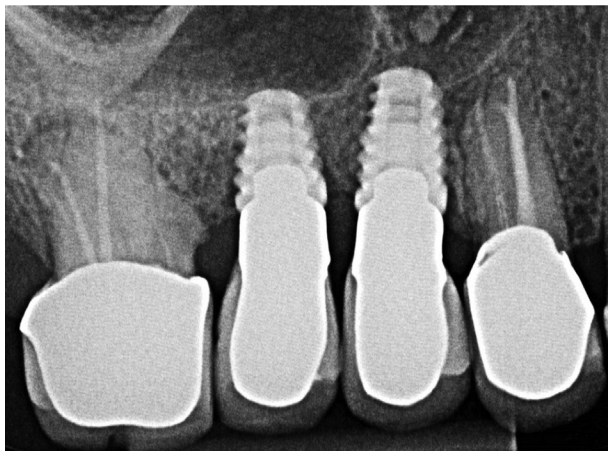

FIGURE 4. Radiograph of 2 short single implants placed in maxilla taken at end of follow-up period.

Zuffetti et al. Laser-Microgrooved Collar. J Oral Maxillofac Surg 2019.



FIGURE 6. Radiograph of 2 short implants placed in mandible taken at 2 years.

Zuffetti et al. Laser-Microgrooved Collar. J Oral Maxillofac Surg 2019.

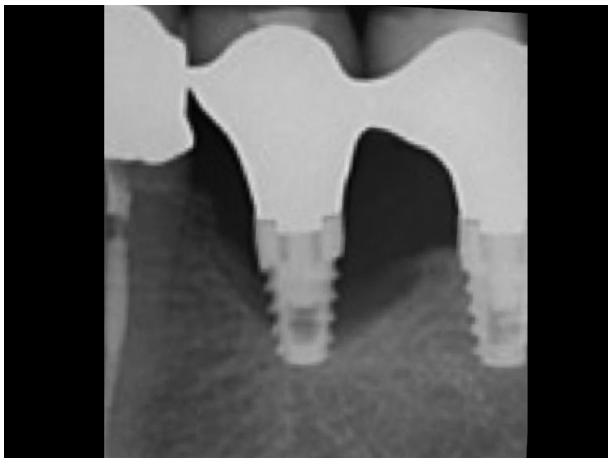

FIGURE 7. Radiograph of 2 short implants placed in mandible taken at 4 years.

Zuffetti et al. Laser-Microgrooved Collar. J Oral Maxillofac Surg 2019.

regression coefficients. Statistical analysis was performed with SPSS for Windows (version 15.0; SPSS, Chicago, IL).

Results

At the end of the study, 254 SIs and 174 patients were evaluated. Table 1 reports overall results. Of the patients, 75 were women and 99 were men; the mean age at the implant placement time was 51.6 ± 2.8 years. A total of 65 patients (37.0%) were smokers. Of the implants, 110 (43.3%) were placed in mandibular posterior areas whereas 144 (56.7%) were placed in maxillary posterior areas of the maxilla. Regarding implant length, 132 implants measured 6.00 mm whereas 120 measured 7.5 mm. Table 2 reports the anatomic location of SIs.

Of the SIs, 140 (55%) supported single crowns, 66 (26%) were splinted to another SI, and 48 (19%) were splinted to standard-length implants (Laser-Lok tapered internal implant with diameter of 3.8 mm and length of 9 to 12 mm; BioHorizons). A total of 135 restorations were screwed, whereas 119 were cemented.

Seven SIs were removed during the study period; thus, at the end of the follow-up, the SR of SIs was 97.2%. Four SIs that failed were inserted in the posterior maxilla (2 right molars [1 of 6.0 mm in length, splinted with 1 standard implant and screwed, and 1 of 7.5 mm in length, splinted with 1 SI and cemented] and 2 left molars [1 of 6.0 mm in length, single and screwed, and 1 of 7.5 mm in length, single and cemented]). Three SIs that failed were inserted in the posterior mandible (1 right molar of 7.5 mm in length, single and screwed, and 2 left molars [1 of 6.0 mm in length, splinted with 1 SI and screwed (Fig 2), and 1 of 7.5 mm in length, splinted with 1 standard implant and cemented]). Thus, the total number of SIs measuring 6.0 mm in length that failed was 3 (2.2%), and the total number of SIs measuring 7.5 mm in length that failed was 4 (3.3%). Of the failed implants, 4 (4.6%) were in smokers and 3 (1.1%) were in nonsmokers; no implant failed in former smokers. Implants failed in 2 periodontally compromised patients (3.9%) and 5 periodontally healthy patients (2.4%). The implants were removed after 2 years in 2 cases, after 3 years in 2 cases, after 4 years in 2 cases, and after 5 years in 1 case.

Regarding MBL, the mean values recorded at the end of the 3- to 5-year follow-up were 0.18 ± 0.7 mm at the mesial aspect and 0.19 ± 0.6 mm at the distal aspect. The mean MBL value was greater in smokers (0.24 mm) than in nonsmokers (0.19 mm) and greater in periodontally compromised patients (0.23 mm) than in periodontally healthy patients (0.20 mm). However, the differences were not statistically significant. Moreover, no correlations were found between mean MBL values and the other qualitative and quantitative variables considered (Tables 2,3).

Table 1. OVERALL RESULTS DURING 3 TO 5 YEARS OF FOLLOW-UP (MEAN, 41.9 MONTHS)

	n (%)	Implants Inserted	Implants Lost (%)
Total patients	174	254	7 (2.7)
Gender			
Male	99 (56.8)	142	4 (2.8)
Female	75 (43.2)	112	3 (2.7)
Jaw			
Mandible	80	110	3 (2.7)
Maxilla	94	144	4 (2.7)
Smoking habit			
Smokers	65 (37.3)	86	4 (4.6)
Nonsmokers	79 (45.4)	110	3 (1.1)
Former smokers	30 (17.3)	58	0 (0)
Periodontitis			
Yes	34 (19.5)	51	2 (3.9)
No	143 (80.5)	203	5 (2.4)
Implant length			
6.0 mm		132	3 (2.2)
7.5 mm		122	4 (3.3)
Prosthetic design			
Single		140	3 (2.1)
Splinted with 1 short		66	1 (3.0)
Splinted with 1 standard		48	3 (3.6)
Fixation			
Screwed		135	4 (2.9)
Cemented		119	3 (2.5)

Zuffetti et al. Laser-Microgrooved Collar. J Oral Maxillofac Surg 2019.

Table 2. MBL VALUES AND QUALITATIVE AND QUANTITATIVE VARIABLES EVALUATED

	Mesial			Distal		
Variable	Mean, mm	SD, mm	*P* Value	Mean, mm	SD, mm	*P* Value
Gender			.49			.67
Male	0.16	0.7		0.19	0.6	
Female	0.19	0.4		0.18	0.5	
Smoking habit			.11			.15
Yes	0.24	0.4		0.23	0.3	
No	0.19	0.6		0.18	0.7	
Periodontitis			.62			.46
Yes	0.22	0.5		0.23	0.3	
No	0.20	0.4		0.19	0.6	
ISQ at implant placement						
30-40	0.17	0.3	.58	0.16	0.6	.57
41-50	0.19	0.6	.71	0.20	0.5	.61
51-60	0.18	0.4	.46	0.17	0.4	.73
>60	0.16	0.5	.82	0.17	0.7	.28
Jaw						
Mandible	0.19	0.7	.43	0.20	0.3	.63
Maxilla	0.17	0.8	.38	0.17	0.4	.42
C/I ratio						
<1	0.18	0.4	.78	0.18	0.7	.39
≥1	0.19	0.3	.66	0.21	0.2	.47
Fixation						.68
Screwed	0.19	0.3	.42	0.19	0.4	.29
Cemented	0.16	0.5	.49	0.20	0.3	.48
Prosthetic design						
Single	0.16	0.5	.58	0.17	0.5	.39
Splinted to 1 short implant	0.17	0.2	.89	0.21	0.4	.22
Splinted to 1 standard implant	0.19	0.3	.67	0.20	0.1	.51

Abbreviations: C/I, crown to implant; ISQ, implant stability quotient; MBL, marginal bone loss; SD, standard deviation.

Zuffetti et al. Laser-Microgrooved Collar. J Oral Maxillofac Surg 2019.

The implants were divided into 5 groups according to the ISQ value: 30 to 40, 41 to 50, 51 to 60, 61 to 70, or 71 to 80. No correlation was found between values of ISQ and MBL. The mean ISQ value at the time of implant insertion was 58.70 ± 8.01. The mean ISQ value was 59.0 ± 5.0 for failed implants and 60.6 ± 8.2 for non-failed implants.

The mean C/I ratio was 1.5 (standard deviation, 0.4), ranging between 0.7 and 2.8. The C/I ratio was less than 1 for 91 implants (35.8%) but 1 or greater for 163 implants (64.2%). No correlation was found between a C/I ratio of less than 1 or C/I ratio of 1 or greater and MBL.

Discussion

This retrospective multicenter study was designed with 2 main purposes: *1)* to clinically and radiographically evaluate the outcomes of SIs with a laser-microgrooved collar (≤7.5 mm), placed in the posterior areas, after 3 to 5 years of function and *2)* to evaluate the possible influence of several variables—such as gender, periodontitis, smoking habit, location, implant stability at placement, and prosthetic fixation design—on MBL. The cumulative success rate (CSR) of 97.1% shows that SIs with a laser-microgrooved collar had favorable clinical outcomes during the 3 to 5 years of follow-up. These data are in agreement with the short-term results of recent literature reviews reporting that in patients with resorbed posterior jaws, textured SIs (<8 mm) and standard-length implants have similar outcomes.[24-28] Compared with data first published on machined-surface SIs, which reported failure rates slightly higher than for standard-length implants, the high predictability of outcomes achieved today by SIs has been related to improvements in implant designs and surface treatment techniques.[21-23] In particular, the use of rough-texture surfaces, which provide an increased bone-to-implant contact surface area, has been considered one of the improvements that have dramatically increased the predictability of SIs.[37]

Table 3. MULTIVARIATE ANALYSIS OF MBL

	Multiple Linear Regression				
	Unstandardized Coefficient		Standardized Coefficient	*t*	Sig.
Constant	B	Error Tip	Beta	B	Error Tip
Gender	−0.0272992	0.063848617	−0.051984364	−0.41873253	0.68448316
Smoking habit	−0.03925597	0.039456931	−0.2413801325	−0.61416212	0.33972124
Periodontitis	−0.01934641	0.022910233	−0.1633502121	−0.53215782	0.29933368
ISQ	−0.02986318	0.028413211	−0.1443982555	−1.15346122	0.26689281
Implant location	−0.01986248	0.018912534	−0.1575987632	−1.05276427	0.29757211
Fixation	−0.02935997	0.032476941	−0.1412801325	−0.91516272	0.37952324
Prosthetic design	−0.00019423	0.023691696	−0.0009231554	−0.08568564	0.95189264

Abbreviations: ISQ, implant stability quotient; MBL, marginal bone loss.

Zuffetti et al. Laser-Microgrooved Collar. J Oral Maxillofac Surg 2019.

The implant body of the SIs tested in our study presents an RBT surface and a tapered design. Several reports highlighted that an RBT surface favors greater bone-to-implant contact[16] and a tapered implant design increases the primary stability in low-density bone.[16,39]

The amount of MBL around SIs represents an important parameter to be evaluated, as a few millimeters of marginal bone resorption around an implant shorter than 7.5 mm could have a different clinical meaning compared with a longer implant. Data on MBL around SIs are conflicting: A recent literature review by Annibali et al[28] indicated that mean MBL values around SIs are similar to those around standard-length implants. However, a comparison among the included studies was difficult because of the different baselines used. On the contrary, the literature reviews of Gonçalves et al[40] and Mezzomo et al[41] indicated that SIs present an increased MBL compared with standard-length implants. Considering 16 studies with 4 years' follow-up, a meta-analysis by Mezzomo et al reported a mean MBL value of 0.83 mm for SIs. In our study, taking into account, as a baseline, the definitive crown delivery, SIs with a laser-microgrooved collar surface showed lower values of MBL (0.18 ± 0.7 mm at the mesial aspect and 0.19 ± 0.6 mm at the distal aspect) after 3 to 5 years of loading. These outcomes are aligned with data reported by a previous study on MBL around short laser-microgrooved implants[42] and confirmed that the presence of microgrooves on implant collars positively influences the amount of peri-implant bone remodeling. Histologic studies of humans showed that, unlike fibers aligned in a direction parallel to a machined implant collar, around a laser-microgrooved implant, fibers present a perpendicular orientation with a physical attachment to the collar implant surface.[43] This kind of connective attachment helps to stabilize the peri-implant soft tissue and diminish the MBL.[44]

The second aim of our investigation was to evaluate the possible influence of implant, patient, and prosthetic variables on MBL after 3 to 5 years of function. Because MBL is considered one of the most important indicators of peri-implant health, the presence of its possible statistical correlation with 1 or more examined variables could represent an important predictive monitoring instrument.

Some studies suggested that primary stability and its associated factors (quality of the bone, surgical technique, microstructure of the implant's surface, and bone surface–implant distance) could have an impact on the success of SIs.[45] RFA via the Osstell ISQ system provides a noninvasive and objective method to quantitatively and qualitatively analyze the stability of implants and examine their behavior under different bone conditions.[38,46] Because the high failure rates of posterior-placed short dental implants have been associated with the low-density bone of the atrophic posterior jaws, in our study the RFA method was used in an attempt to assess primary stability at the time of implant insertion.

According to the collected data, no statistically significant correlation was found between ISQ values at the implant placement time and MBL. Because all the implants were positioned in a submerged way and without immediate or early loading, the following healing process around the RBT surface, which favors a higher bone-to-implant contact, could have counteracted the initial low ISQ value of primary stability.

Smoking habit has been reported to be one of the most important patient variables affecting the success of SIs**.** Telleman et al,[27] in a recent systematic review, indicated—for implants measuring less than 10 mm—a failure rate of 0.008 implants/year in smokers compared with 0.004 implants/year in nonsmokers. Of the 7 failed implants in our study, 4 were in smokers. However, no statistical correlation

was found between smoking habit and implant failure. In accordance with our interpretation of these data, the reduced number of implants lost (7 of 254 implants) could have undermined the power of statistical analysis and thus the possibility of detecting a potential risk factor.

The presence of periodontitis is another factor that has been reported to influence MBL around implants. According to the data collected in our study, no statistical difference in MBL was found between healthy and periodontally compromised patients. However, it is important to stress that all patients were enrolled in a strictly controlled supportive therapy program, which is necessary for achieving long-term success and preventing peri-implantitis and the progression of periodontitis.

Connected with the relatively low bone density, the prognosis of SIs has been reported to be worse in the maxilla than in the mandible.[11,26,35,36] The results of our study are in contrast with these reports, with MBL having shown no statistical correlation with areas of placement (mandible or maxilla). This could be linked to the tapered design of implants with reverse buttress threads that, in a vitro study, have been proved to provide high support to loading also in sites with low bone density.[39]

Regarding the prosthetic factors, some studies have reported that an excessive C/I ratio could be associated with a greater MBL and lower SR.[35,36,47,48] A higher C/I ratio, leading to a longer lever arm, could increase the peri-implant bone stress and, consequently, the risk of MBL and implant failure. In contrast, with any influence of the C/I ratio on MBL not having been documented, other studies have suggested that if loading forces are correctly oriented and distributed, a higher C/I ratio does not determine greater peri-implant marginal bone remodeling.[49]

In our study, no statistically significant correlation was documented between the C/I ratio and MBL. According to this outcome, it is also possible to hypothesize that the laser-microtextured treatment of the implant collar surface and its position at the crestal bone level, counteracting MBL, could have offset inadequate C/I ratios.

Although literature data have indicated for SIs a similar SR regardless of the kind of prosthesis,[28] in our study, in accordance with the indications of several authors,[50,51] no cantilevers were used and utmost care was used to avoid lateral contacts. Only a few studies have reported data on MBL around splinted versus nonsplinted SIs. Compared with splinted SIs, Rokni et al reported a lower MBL around nonsplinted implants measuring less than 6 mm in length whereas Clelland et al reported a greater MBL around nonsplinted implants measuring 5 or 7 mm in length.[52,53] A recent review of biological and technical complications of splinted and nonsplinted implants[54] indicated that, although there should not be any difference in the ease of performing proper oral hygiene between both restorations if the prosthesis is designed correctly, nonsplinted implant-supported restorations are indicated for patients with decreased manual dexterity and poor oral hygiene. Splinted implant-supported restorations present fewer technical complications in the long-term. Furthermore, for the purpose of avoiding excessive occlusal forces on the prosthetic components, splinted SIs could be recommended for patients with a history of bruxism. According to these therapeutic choices used in our study, no statistically significant correlation was found between splinted and nonsplinted SIs and MBL.

Surgical techniques needed for the placement of standard-length implants in resorbed posterior jaws increase treatment times and biological and economic costs for patients. Consequently, if SIs presented a CSR and MBL similar to standard-length implants placed in grafted bone areas, they could represent an alternative treatment option that eliminates all disadvantages associated with bone augmentation procedures. Few data are available on the comparative SR and MBL between SIs and standard implants placed in augmented sites. A recent literature review indicated that, in the short-term, implants measuring 7 mm or less in length placed in native bone and implants with a standard length placed in augmented sites had similar CSRs.[54] However, implants measuring 7 mm or less showed a lower MBL than standard-length implants. In a literature review on bone augmentation procedures, Chiapasco et al[2] reported that, after at least 1 year of loading, the incidence of failure for standard-length implants placed in sites treated with block bone grafting, sinus lifting, vertical distraction, and guided bone regeneration was 12.9%, 5%, 4.1%, and 4%, respectively. The 2.8% of failures recorded in our study after 3 to 5 years of loading highlights that SIs placed in resorbed posterior jaws had a favorable prognosis even in the medium-term. Therefore, at equal rates of success, priority should be given to the less invasive surgical approach.

Our study supports the predictability of SIs in the rehabilitation of resorbed posterior jaws. However, given the retrospective design, the absence of a control group without a laser-microtextured surface, and the short-term follow-up, which represent important limitations, future analyses are necessary to confirm these promising results.

At the end of the 3- to 5-year follow-up period, SIs with a laser-microgrooved collar ($\leq$7.5 mm) in the posterior areas yielded a relatively high SR. The laser-microgrooved collar implant maintained stable marginal bone levels. No investigated variable was statistically associated with the CSR and MBL.

References

1. Reich KM, Huber CD, Lippnig WR, et al: Atrophy of the residual alveolar ridge following tooth loss in an historical population. Oral Dis 17:33, 2011
2. Chiapasco M, Casentini P, Zaniboni M: Bone augmentation procedures in implant dentistry. Int J Oral Maxillofac Implants 24(Suppl):237, 2009
3. Anitua E, Alkhraisat M, Orive HG: Novel technique for the treatment of the severely atrophied posterior mandible. Int J Oral Maxillofac Implants 28:1338, 2013
4. Esposito M, Felice P, Worthington HV: Interventions for replacing missing teeth: Augmentation procedures of the maxillary sinus. Cochrane Database Syst Rev 5:CD008397, 2014
5. Esposito M, Grusovin MG, Felice P, et al: Interventions for replacing missing teeth: Horizontal and vertical bone augmentation techniques for dental implant treatment. Cochrane Database Syst Rev CD003607, 2009
6. Alsaadi G, Quirynen M, Komarek A, Van Steenberghe D: Impact of local and systemic factors on the incidence of oral implant failures, up to abutment connection. J Clin Periodontol 34:610, 2007
7. Bornstein MM, Halbritter S, Harnisch H, et al: A retrospective analysis of patients referred for implant placement to a specialty clinic: Indications, surgical procedures, and early failures. Int J Oral Maxillofac Implants 23:1109, 2008
8. Palma-Carrio C, Maestre-Ferrin L, Peñarrocha-Oltra D, et al: Risk factors associated with early failure of dental implants. A literature review. Med Oral Patol Oral Cir Bucal 16:e514, 2011
9. van Steenberghe D, Lekholm U, Bolender C, et al: The applicability of osseointegrated oral implants in the rehabilitation of partial edentulism: A prospective multicenter study on 558 fixtures. Int J Oral Maxillofac Implants 5:272, 1990
10. Friberg B, Jemt T, Lekholm U: Early failure in 4641 consecutively placed Branemark dental implants: A study from stage 1 to the connection of completed prostheses. Int J Oral Maxillofac Implants 6:142, 1991
11. Jemt T: Failures and complications in 391 consecutively inserted fixed prostheses supported by Branemark implant in edentulous jaws: A study of treatment from the time of prosthesis placement to the first annual checkup. Int J Oral Maxillofac Implants 6:270, 1991
12. Bahat O: Treatment planning and placement of dental implants in the posterior maxillae: Report of 732 consecutive Nobelpharma implants. Int J Oral Maxillofac Implants 8:151, 1993
13. Jemt T, Lekholm U: Implant treatment in edentulous maxillae: A 5-year follow-up report on patients with different degrees of jaw resorption. Int J Oral Maxillofac Implants 10:303, 1995
14. Wyatt CCL, Zarb GA: Treatment outcomes of patients with implant-supported fixed partial prostheses. Int J Oral Maxillofac Implants 13:204, 1998
15. Bahat O: Branemark system implants in the posterior maxilla: Clinical study of 660 implants followed for 5 to 12 years. Int J Oral Maxillofac Implants 15:646, 2000
16. Piattelli M, Scarano A, Paolantonio M, et al: Bone response to machined and resorbable blast material titanium implants: An experimental study in rabbits. J Oral Implant 28:2, 2002
17. Lops D, Bressan E, Pisoni G, et al: Short implants in partially edentuolous maxillae and mandibles: A 10 to 20 years retrospective evaluation. Int J Dent 2012:351793, 2012
18. Mertens C, Meyer-Baumer A, Kappel H, et al: Use of 8-mm and 9-mm implants in atrophic alveolar ridges: 10-Year results. Int J Oral Maxillofac Implants 27:1501, 2012
19. Lai HC, Si MS, Zhuang LF, et al: Long-term outcomes of short dental implants supporting single crowns in posterior region: A clinical retrospective study of 5-10 years. Clin Oral Implants Res 24:230, 2013
20. Anitua E, Pinas L, Begona L, Orive G: Long-term retrospective evaluation of short implants in the posterior areas: Clinical results after 10-12 years. J Clin Periodontol 1:8, 2013
21. Anitua E, Alkhraisat MH: Clinical performance of short dental implants supporting single crown restoration in the molar-premolar region: Cement versus screw retention. Int J Oral Maxillofac Implants 34:969, 2019
22. Lorenz J, Blume M, Korzinskas T, et al: Short implants in the posterior maxilla to avoid sinus augmentation procedure: 5-Year results from a retrospective cohort study. Int J Implant Dent 5:3, 2019
23. Weerapong K, Sirimongkolwattana S, Sastraruji T, Khongkhunthian P: Comparative study of immediate loading on short dental implants and conventional dental implants in the posterior mandible: A randomized clinical trial. Int J Oral Maxillofac Implants 34:141, 2019
24. Kotsovilis S, Fourmousis I, Karoussis IK, Bamia C: A systematic review and meta-analysis on the effect of implant length on the survival of rough-surface dental implants. J Periodontol 80: 1700, 2009
25. Menchero-Cantalejo E, Barona-Dorado C, Cantero-Álvarez M, et al: Meta-analysis on the survival of short implants. Med Oral Patol Oral Cir Bucal 16:e546, 2011
26. Sun HL, Huang C, Wu YR, Shi B: Failure rates of short (≤ 10 mm) dental implants and factors influencing their failure: A systematic review. Int J Oral Maxillofac Implants 26:816, 2011
27. Telleman G, Raghoebar GM, Vissink A, et al: A systematic review of the prognosis of short (<10 mm) dental implants placed in the partially edentulous patient. J Clin Periodontol 38:667, 2011
28. Annibali S, Cristalli MP, Dell'Aquila D, et al: Short dental implants: A systematic review. J Dent Res 91:25, 2012
29. Atieh MA, Zadeh H, Stanford CM, Cooper LF: Survival of short dental implants for treatment of posterior partial edentulism: A systematic review. Int J Oral Maxillofac Implants 27:1323, 2012
30. Srinivasan M, Vazquez L, Rieder P, et al: Efficacy and predictability of short dental implants (<8 mm): A critical appraisal of the recent literature. Int J Oral Maxillofac Implants 27:1429, 2012
31. Al-Johany SS: Survival rates of short dental implants (≤ 6.5 mm) placed in posterior edentulous ridges and factors affecting their survival after a 12-month follow-up period: A systematic review. Int J Oral Maxillofac Implants 34:605, 2019
32. Ravidà A, Barootchi S, Askar H, et al: Long-term effectiveness of extra-short (≤ 6 mm) dental implants: A systematic review. Int J Oral Maxillofac Implants 34:68, 2019
33. Albrektsson T, Donos N, Working Group 1. Implant survival and complications. The third EAO consensus conference. Clin Oral Implants Res 23(Suppl 6):63, 2012
34. Lemos CA, Ferro-Alves ML, Okamoto R, et al: Short dental implants versus standard dental implants placed in the posterior jaws: A systematic review and meta-analysis. J Dent 47:8, 2016
35. Bratu E, Chan HL, Mihali S, et al: Implant survival rate and marginal bone loss of 6-mm short implants: A 2-year clinical report. Int J Oral Maxillofac Implants 29:1425, 2014
36. Monje A, Suarez F, Galindo-Moreno P, et al: A systematic review on marginal bone loss around short dental implants (≤10 mm) for implant-supported fixed prostheses. Clin Oral Implants Res 25:1119, 2014
37. Morand M, Irinakis T: The challenge of implant therapy in the posterior maxilla: Providing a rationale for the use of short implants. J Oral Implantol 33:257, 2007
38. Gedrange T, Hietschold V, Mai R, et al: An evaluation of resonance frequency analysis for the determination of the primary stability of orthodontic palatal implants. A study in human cadavers. Clin Oral Implants Res 16:25, 2005
39. Alexander H, Ricci JL, Hrico GJ: Mechanical basis for bone retention around dental implants. J Biomed Mater Res B Appl Biomater 88B:306, 2009
40. Gonçalves TM, Bortolini S, Martinolli M, et al: Long-term short implants performance: Systematic review and meta-analysis of the essential assessment parameters. Braz Dent J 26:325, 2015
41. Mezzomo LA, Miller R, Triches D, et al: Meta-analysis of single crowns supported by short (<10 mm) implants in the posterior region. J Clin Periodontol 41:191, 2014
42. Guarnieri R, Di Nardo D, Gaimari G, et al: Short vs. standard laser-microgrooved implants supporting single and splinted crowns: A prospective study with 3 years follow-up. J Prosthodont 28:e771, 2019
43. Nevins M, Nevins ML, Camelo M, et al: Human histologic evidence of a connective tissue attachment to a dental implant. Int J Periodontics Restorative Dent 28:111, 2008
44. Guarnieri R, Serra M, Bava L, et al: The impact of laser-microtexturing collar design on crestal bone level and clinical

ARTICLE IN PRESS

parameters under various placement and loading protocols. Int J Oral Maxillofac Implants 29:345, 2014
45. Bidez MW, Misch CE: Force transfer in implant dentistry: Basic concepts and principles. J Oral Implant 18:264, 1992
46. Meredith N, Alleyne D, Cawley P: Quantitative determination of the stability of the implant-tissue interface using resonance frequency analysis. Clin Oral Implants Res 7:261, 1996
47. Mendoza-Azpur G, Lau M, Valdivia E, et al: Assessment of marginal peri-implant bone-level short-length implants compared with standard implants supporting single crowns in a controlled clinical trial: 12-Month follow-up. Int J Periodontics Restorative Dent 36:791, 2016
48. Renouard F, Nisand D: Impact of implant length and diameter on survival rates. Clin Oral Implants Res 17:35, 2006
49. Nisand D, Renouard F: Short implant in limited bone volume. Periodontology 2000 66:72, 2014
50. Garaicoa-Pazmiño C, Suárez-López del Amo F, Monje A, et al: Influence of crown/implant ratio on marginal bone loss: A systematic review. J Periodontol 85:1214, 2014
51. Quaranta A, Piemontese M, Rappelli G, et al: Technical and biological complications related to crown to implant ratio: A systematic review. Implant Dent 23:180, 2014
52. Rokni S, Todescan R, Watson P, et al: An assessment of crown-to-root ratios with short sintered porous-surfaced implants supporting prostheses in partially edentulous patients. Int J Oral Maxillofac Implants 20:69, 2005
53. Clelland N, Chaudhry J, Rashid RG, et al: Split-mouth comparison of splinted and nonsplinted prostheses on short implants: 3-year results. Int J Oral Maxillofac Implants 31:1135, 2016
54. Uehara PN, Matsubara VH, Igai F, et al: Short dental implants (≤7mm) versus longer implants in augmented bone area: A meta-analysis of randomized controlled trials. Open Dent J 12:355, 2018