Incidence of Peri-implant Diseases on Implants With and Without Laser-Microgrooved Collar: A 5-Year Retrospective Study Carried Out in Private Practice Patients

Renzo Guarnieri, MD, DDS[1]/Maurizio Grande, DDS[2]/
Francesco Zuffetti, MD, DDS[3]/Tiziano Testori, MD, DDS[4]

Purpose: *To retrospectively evaluate the incidence of peri-implant mucositis and peri-implantitis around dental implants with the same body design and surface but different collar surface (laser-microgrooved vs not laser-microgrooved) after 5 years of loading in private practice patients.* ***Materials and Methods:*** *The study was carried out on patients at a private dental clinic enrolled in a periodontal maintenance program, who received at least one implant with a laser-microgrooved collar surface and one implant without a laser-microgrooved collar surface. Clinical variables such as plaque, pocket depth, bleeding on probing, suppuration, and radiographic marginal bone loss at > 5 years around implants were investigated. The correlation between the prevalence of peri-implant mucositis/peri-implantitis and biotype, keratinized tissue width, prosthetic connection type, and prosthetic design type was also analyzed.* ***Results:*** *A total of 166 implants in 74 patients were investigated. At the end of the 5-year follow-up period, 38 implants presented peri-implant mucositis, accounting for 22.8% of the total, affecting a total of 24 patients (32.4%), while 13 implants (7.8%) in 10 patients (13.5%) were diagnosed with peri-implantitis. Sixteen of 82 laser-microgrooved implants (19.5%) and 24 of 84 implants (28.5%) without a laser-microgrooved collar presented peri-implant mucositis, while 3 of 82 (3.6%) of laser-microgrooved implants and 10 of 84 (11.9%) implants without a laser-microgrooved collar demonstrated peri-implantitis. Differences in implant-based incidence of peri-implant diseases between implants with and without a laser-microgrooved collar were statistically significant (P < .05).* ***Conclusion:*** *In private practice patients enrolled in a professional, controlled oral hygiene regimen, implants with a laser-microgrooved collar, compared with implants without a laser-microgrooved collar, presented a statistically significantly lower incidence of peri-implant diseases.*
Int J Oral Maxillofac Implants 2018;33:457–465. doi: 10.11607/jomi.6178

Keywords: *dental implants, laser-microgrooved collar surface, peri-implantitis, peri-implant mucositis, prevalence*

[1]Adjunct Professor, Department of Oral and Maxillofacial Sciences, University "La Sapienza", Roma; Private Practice, Roma, Treviso, Italy; Freelance Researcher, SCS, Scientific Consulting Services, Treviso, Italy.
[2]Private Practice, Roma, Italy.
[3]Assistant Professor, Section of Implantology and Oral Rehabilitation, Department of Odontology, IRCCS Galeazzi, University of Milan, Milan, Italy; Private Practice, Milan, Italy.
[4]Head of the Section of Implantology and Oral Rehabilitation, Department of Odontology, IRCCS Galeazzi, University of Milan, Milan, Italy; Adjunct Clinical Associate Professor, Department of Periodontics and Oral Medicine, The University of Michigan, School of Dentistry, Ann Arbor, Michigan, USA; Private Practice, Como, Italy.

Correspondence to: Dr Renzo Guarnieri, via L. Cattarin 3D, 31100 Treviso, Italy. Email: renzoguarnieri@gmail.com

©2018 by Quintessence Publishing Co Inc.

Dental implant failures are classified as early or late. Early failures happen during the osteointegration period and may be related to the surgical trauma, or to implant and host-related factors.[1] Late failures happen after implant loading and may be connected to excessive load[2,3] or infection.[4] Two types of peri-implant infection have been described: peri-implant mucositis and peri-implantitis.[5–7] Peri-implant mucositis is characterized by an inflammatory process localized in peri-implant soft tissues, whereas peri-implantitis entails a concomitant peri-implant marginal bone loss.[8,9] However, because of the multifactorial etiology, the variety and the different degrees of clinical manifestations, and the lack of standardized diagnostic criteria, a clear clinical framing of this disease still remains difficult. Huge discrepancies in the incidence of peri-implant mucositis and peri-implantitis are present

© 2018 BY QUINTESSENCE PUBLISHING CO, INC. PRINTING OF THIS DOCUMENT IS RESTRICTED TO PERSONAL USE ONLY.
NO PART MAY BE REPRODUCED OR TRANSMITTED IN ANY FORM WITHOUT WRITTEN PERMISSION FROM THE PUBLISHER.

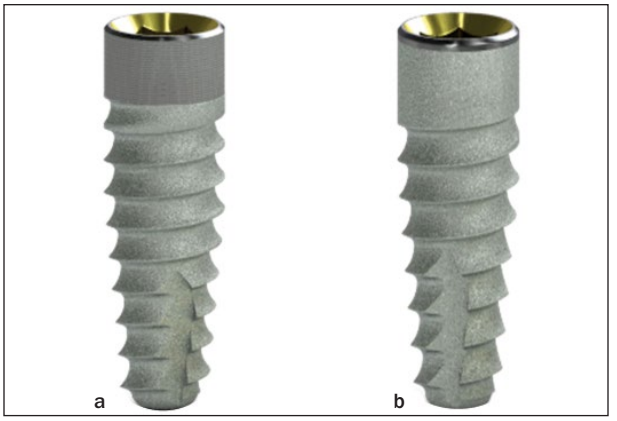

Fig 1 Implants used in the study: *(a)* implant with laser-microgrooved collar and *(b)* implant without laser-microgrooved collar.

in the literature.[8–14] The Consensus Report of the Sixth European Workshop on Periodontology[6] indicated that 80% of subjects and 50% of sites treated with dental implants present peri-implant mucositis, whereas peri-implantitis occurs in 28% to 56% of subjects and 12% to 40% of sites. Data reported in a meta-analysis by Derks and Tomasi[15] indicated a mean incidence of peri-implant mucositis of 43% and peri-implantitis of 22%, while in previous systematic reviews with meta-analysis, the incidence of peri-implant mucositis ranged between 30.7% and 9.6%, and the incidence of peri-implantitis was between 63.4% and 18.8%.[8,10] Differences reported in the literature depend on varying study designs, follow-up period, and population sizes, with different risk and statistic profiles.

There is not much literature highlighting the relationship between implant surface characteristics and peri-implant diseases. Although it has been reported that, after 3 years of function, implants with textured surfaces presented a peri-implantitis incidence of 20% greater than implants with turned/machined surfaces,[16] currently, the relationship between the implant surface roughness and the development of peri-implantitis is still controversial[17,18] and needs further investigation.

Recently, some new technologies have been used to change the conventional implant surface in search of better biologic results. One of these technologies is the controlled laser ablation, which allows the realization of microgrooves on the neck segment of implants with resolution within a micrometric range. Numerous clinical studies have shown the impact of the laser-microgrooved implant collar on the preservation of peri-implant marginal bone level and on the stability of peri-implant soft tissue,[19–21] but there are no studies in the literature focusing on the influence of this type of implant collar surface and the development of peri-implant mucositis and peri-implantitis. Therefore, this study aimed to evaluate the incidence of peri-implant diseases on implants with and without a laser-microgrooved collar surface, after at least 5 years of function.

MATERIALS AND METHODS

The clinical and radiographic evaluation in the present study was conducted, retrospectively, in private practice patients enrolled in a periodontal maintenance program who received at least one implant with a laser-microgrooved collar and one implant without a laser-microgrooved collar. Since authors analyzed pre-existing, and no identifiable data of patients who had already been treated on the basis of previously approved research protocols, this study did not require approval by a review board. However, written consent was obtained from each patient, and the study was conducted according to the principles embodied in the Declaration of Helsinki for biomedical research involving human subjects. Seventy-four patients attending four Italian private dental clinics with extensive experience in implantology, between January 2008 and December 2008, were enrolled in the study.

Patients were excluded in the presence of the following:

- Age < 18 years
- Implants placed in regenerated bone
- Implants with immediate loading, and with immediate postextractive placement
- No availability of a periodontal chart and periapical radiograph at the beginning and at the end of the follow-up period
- Presence of alcohol and drug abuse; pregnancy; uncontrolled metabolic disorders
- Tobacco smoking (> 10 cigarettes/day)
- Full-Mouth Plaque Score (FMPS) and Full-Mouth Bleeding Score (FMBS) ≥ 25%
- Periodontally compromised patients
- Patients with erratic compliance with the supportive periodontal therapy, ie, patients who abandoned regular 3/6 months recalls

Implants

Two tapered implants (Fig 1) (BioHorizons) with the same body design with reverse buttress thread and the same grit-blasted moderately rough body surface (between 0.72 and 1.34 μm), but with different collar surfaces, were used in this study. The laser-microgrooved implant has the 1.8 mm of the collar surface characterized by the presence of laser-produced microgrooves, while the implant without a laser-microgrooved surface has the most coronal 0.3 mm of the collar surface machined and the next 1.5 mm of the collar surface grit-blasted.

© 2018 BY QUINTESSENCE PUBLISHING CO, INC. PRINTING OF THIS DOCUMENT IS RESTRICTED TO PERSONAL USE ONLY.
NO PART MAY BE REPRODUCED OR TRANSMITTED IN ANY FORM WITHOUT WRITTEN PERMISSION FROM THE PUBLISHER.

Clinical Procedures

Local anesthesia was performed using lidocaine 2% with epinephrine 1:100,000 (Octocaine 100, Septodont). Implants in both groups were placed according to a two-stage protocol, approximating the alveolar bone crest. Amoxicillin 1 g for 7 days, and ibuprofen 600 mg, immediately after surgery and 8 hours later were prescribed. A prophylaxis with mouthrinses of 0.12% chlorhexidine with a 1-minute rinse before surgery and three times a day for the following 10 days was used in all the subjects. Sutures were removed after 1 week. Healing screws were placed during implant-uncovering surgery 3 to 6 months later. Prosthetic abutment connection and definitive crown delivery were carried out after a further 8/10 and 14/16 weeks, respectively.

Clinical Examination

Plaque Index, probing depth, bleeding on probing, suppuration, width of the keratinized gingiva, gingival biotype, type of prosthetic connection (screwed or cemented), and prosthetic design (splinted or single implants) were collected for each implant. Soft tissue biotype was dichotomized into two groups: "thick" biotype, when the periodontal probe outline did not transpire through the gingival tissue; and "thin" biotype, when the periodontal probe outline transpired through the gingival tissue. The width of keratinized gingiva, measured in millimeters on the buccal site from the gingival margin midpoint to the mucogingival junction, was dichotomized into two groups: < 2 mm and ≥ 2 mm.

Implants were categorized as follows[22]:

- Affected by peri-implant mucositis in the presence of probing depth < 5 mm with bleeding on probing, and radiographic bone loss < 2 mm
- Affected by peri-implantitis in the presence of probing depth ≥ 5 mm with bleeding on probing, or suppuration; and radiographic bone loss ≥ 2 mm
- Each patient was considered healthy when no implant was classified as affected by peri-implant mucositis or peri-implantitis. In the presence of at least one implant diagnosed with peri-implant mucositis/peri-implantitis, the patient was considered not healthy.

Follow-up Examination

During the 5-year follow-up period, each patient was recalled every 3 to 6 months to receive supportive periodontal treatment. Once a year, FMPS, FMBS, probing depth, bleeding on probing, and suppuration were recorded.

Radiographic Examinations

Radiographs were taken using a film holder at the time of data collection by means of the long-cone technique, and afterward digitized with a resolution of 1,200 dpi. Peri-implant marginal bone levels were recorded in millimeters at the mesial and the distal aspects of the implant shoulder, using dedicated software (VixWin Platinum Imaging Software, Gendex). The difference between the radiographic bone loss values recorded at the 5-year follow-up, minus the values recorded at the baseline, was considered for the comparison between the two groups of implants. The case definition proposed by Persson et al[23] was used for the radiographic diagnosis of peri-implantitis. For the radiographic prognosis of peri-implantitis, the rate of bone loss, obtained by dividing the bone loss value by the years of implant functioning, was used.

Calibration

For the evaluation, the examiners were calibrated by measuring the same five implants with a laser-microgrooved collar and the same five implants without a laser-microgrooved collar, 1 week apart (Kappa Test = 0.940, standard error [SE] of kappa = 0.042, 95% confidence interval: 0.857 to 1.000). Recalibration of examiners was carried out once a year by measuring the same 10 implants, and a reliability calibration of > 90% was considered satisfactory.

Statistical Analysis

Statistic Package for Social Sciences (SPSS v 16.0, SPSS) was used for the implant-based and patient-based statistical analysis. Quantitative data (probing depth and radiographic bone loss) were analyzed descriptively (mean and standard deviations), whereas qualitative dichotomous variables (bleeding on probing, suppuration, plaque, type of prosthetic design, type of restoration fixation, biotype, and thickness of keratinized tissue) were recorded as absolute and relative frequencies, and expressed in percentages. The Mann-Whitney *U* test, chi-square test, and binary logistic regression analysis were used for the comparative incidence evaluation of diseases between the groups. For all statistical tests, a confidence interval of 95% was assumed, and a *P* value of < .05 was considered statistically significant.

RESULTS

Seventy-four patients with a total of 166 implants were screened for this study. The mean age of the patients was 44.5 ± 13.7 years (range: 19 to 67 years). Of the 166 investigated implants (Table 1), 82 were in the group with a laser-microgrooved collar, and 84 were in the group without a laser-microgrooved collar. In the laser-microgrooved group, 52 implants were splinted, and 30 were not splinted. In the group without a laser-microgrooved collar, 48 implants were splinted

© 2018 BY QUINTESSENCE PUBLISHING CO, INC. PRINTING OF THIS DOCUMENT IS RESTRICTED TO PERSONAL USE ONLY.
NO PART MAY BE REPRODUCED OR TRANSMITTED IN ANY FORM WITHOUT WRITTEN PERMISSION FROM THE PUBLISHER.

Table 1 Implants, Prosthetic Design, and Prosthetic Fixation

	Implants with laser-microgrooved collar	Implants without laser-microgrooved collar	Total
Implants	82	84	166
Prosthetic design			
Unitary implants	30	36	66
Splinted implants	52	48	100
Fixation			
Cemented fixation	38	42	80
Screwed fixation	44	42	86

Table 2 Descriptive Results Among Different Diseases in Two Groups of Implants at End of Follow-up Period

	Implant-based prevalence (n/%)	Patient-based prevalence (n/%)	Probing depth (mm)	Bone loss/Rate of bone loss (mm)
Implants with laser-microgrooved collar (82)				
Peri-implant mucositis	16/19.5	16/21.6	3.5 ± 1.4	2.6 ± 0.8/0.52 ± 0.3
Peri-implantitis	3/3.6	3/4.0	6.1 ± 1.1	5.2 ± 0.4/1.04 ± 0.2
Implants without laser-microgrooved collar (84)				
Peri-implant mucositis	24/28.5	24/32.4	4.3 ± 0.8	2.9 ± 0.8/0.58 ± 0.4
Peri-implantitis	10/11.9	10/13.5	6.3 ± 1.9	5.5 ± 0.2/1.1 ± 0.8

and 36 were not splinted. In the laser-microgrooved group, a prosthetic cemented fixation and a prosthetic screwed fixation were used in 38 and 44 implants, respectively, while in the group without a laser-microgrooved collar, the cemented and screwed fixation were used in 42 and 42 implants, respectively. According to the previously mentioned diagnostic criteria, 38 of the 166 implants presented peri-implant mucositis, representing a prevalence of 22.8%, affecting a total of 24 of the 74 patients (32.4%), while 13 implants (7.8%) in 10 patients (13.5%) were diagnosed with peri-implantitis. Sixteen of 82 laser-microgrooved implants (19.5%) and 24 of 84 implants without a laser-microgrooved collar (28.5%) presented peri-implant mucositis, while 3 of 82 laser-microgrooved implants (3.6%) and 10 of 84 implants without a laser-microgrooved collar (11.9%) demonstrated peri-implantitis. Differences in the implant-based incidence of peri-implant diseases between implants with and without a laser-microgrooved collar were statistically significant ($P < .05$) (Table 2). At the 5-year follow-up examination, implants with and without a laser-microgrooved collar presented no significant difference in plaque accumulation (84 of 492 sites [23.7%] vs 123 of 504 sites [25.3%], respectively) ($P > .05$). At baseline, the mean probing depth value of laser-microgrooved implants was 1.2 ± 0.4 mm, and after 5 years, the mean probing depth value was 1.7 ± 0.7 mm. Differences between the two examination periods were not statistically significant ($P > .05$). At baseline and after 5 years, the mean probing depth value around implants without a laser-microgrooved collar was 2.4 ± 0.6 mm and 4.4 ± 0.8 mm, respectively. The difference was statistically significant ($P < .05$). At the 5-year follow-up examination, significant differences between implants with and without a laser-microgrooved collar were found in terms of bleeding on probing: 84 of 492 sites (17%) and 123 of 504 sites (24.4%), respectively ($P < .05$); and suppuration: 14 of 492 sites (2.8%) and 52 of 504 sites (10.3%), respectively ($P < .05$). Pockets ≥ 5 mm were found in 3 of 82 (3.6%) laser-microgrooved implants, and in 10 of 84 (11.9%) implants without a laser-microgrooved collar, whereas pockets ≥ 6 mm were found in 2 of 82 (2.4%) laser-microgrooved implants, and in 8 of 84 (9.5%) implants without a laser-microgrooved collar. The comparative values were found to be statistically significant ($P < .05$) (Table 3).

Radiographically, implants with and without a laser-microgrooved collar showed different marginal bone loss values. After 5 years of loading, the laser-microgrooved group showed mean marginal bone loss values of 1.45 ± 0.21 mm and 1.57 ± 0.25 mm at the mesial and distal aspects, respectively. The mean marginal bone loss values in the group of implants without a laser-microgrooved collar were 2.55 ± 0.25 mm and 2.61 ± 0.34 mm,

© 2018 BY QUINTESSENCE PUBLISHING CO, INC. PRINTING OF THIS DOCUMENT IS RESTRICTED TO PERSONAL USE ONLY.
NO PART MAY BE REPRODUCED OR TRANSMITTED IN ANY FORM WITHOUT WRITTEN PERMISSION FROM THE PUBLISHER.

Table 3 Clinical Parameters after 5 Years of Loading

Clinical variables	Implants with laser-microgrooved collar (n/N)	Implants without laser-microgrooved collar (n/N)	*P* value between 2 groups
BOP	84/492	123/504	< .05
Suppuration	14/492	52/504	< .05
Plaque	117/492	128/504	> .05
Implants with PD < 4 mm and BOP	16/82	24/84	< .05
Implants with PD ≥ 4 mm and BOP	11/82	20/84	< .05
Implants with PD ≥ 5 mm and BOP	3/82	10/84	< .05
Implants with PD ≥ 6 mm and BOP	2/82	8/84	< .05

BOP = bleeding on probing; PD = probing depth.

Table 4 Prevalence of Peri-implant Mucositis and Peri-implantitis According to Implant Group, Fixation, Prosthetic Design, Width of Keratinized Gingiva, and Biotype

	Implants with laser-microgrooved collar		Implants without laser-microgrooved collar		
	Peri-implant mucositis	Peri-implantitis	Peri-implant mucositis	Peri-implantitis	*P* value between groups
Prosthetic fixation					
Cemented	10	3	15	7	> .05
Screwed	6	0	9	3	> .05
P value	< .05	< .05	< .05	< .05	
Prosthetic design					
Unitary	9	1	8	2	> .05
Splinted	7	2	13	8	< .05
P value	> .05	< .05	> .05	< .05	
Width of keratinized gingiva					
< 2 mm	9	2	12	6	> .05
≥ 2 mm	8	1	12	4	> .05
P value	> .05	> .05	> .05	> .05	
Biotype					
Thin	10	1	9	4	> .05
Thick	7	2	15	6	> .05
P value	> .05	> .05	> .05	> .05	

respectively. Differences between the implants with and without a laser-microgrooved collar were statistically significant ($P < .05$).

In both groups of implants, a higher incidence of peri-implant mucositis and peri-implantitis was found to be associated with the cemented and the splinted prosthetic design ($P < .05$), whereas the association with the biotype and the keratinized gingiva width was not statistically significant ($P > .05$) (Table 4).

DISCUSSION

The present study aimed to determine, retrospectively, the prevalence of patient-based and implant-based peri-implant mucositis and peri-implantitis in private practice patients. Several reports[8,9,24–27] indicated clinical parameters for peri-implant mucositis and peri-implantitis diagnosis. Peri-implant mucositis requires the presence of bleeding on probing/suppuration and probing depth < 4 mm, and no evidence of radiographic bone loss beyond the expected value of 1.5 mm for the first year and not exceeding 0.2 mm per year afterward.[28,29] Peri-implantitis requires probing depth > 5 mm and radiographic bone loss of > 0.2 mm for each year of loading, or progressive bone loss of > 3 threads combined with signs of peri-implant mucositis. According to Albrektsson at al,[28] in cases where a baseline radiograph is present, diagnosis of peri-implantitis

© 2018 BY QUINTESSENCE PUBLISHING CO, INC. PRINTING OF THIS DOCUMENT IS RESTRICTED TO PERSONAL USE ONLY.
NO PART MAY BE REPRODUCED OR TRANSMITTED IN ANY FORM WITHOUT WRITTEN PERMISSION FROM THE PUBLISHER.

can also be made if signs of peri-implant mucositis are associated with any degree of bone loss beyond the expected peri-implant postplacement marginal bone resorption. In cases where the baseline radiograph is absent, diagnosis of peri-implantitis requires a bone loss of at least 2 mm beyond the expected peri-implant postplacement marginal bone resorption.[30] A classification for early, moderate, and advanced degrees of peri-implantitis has also been proposed by some authors,[31] according to the degree of bleeding on probing/suppuration, probing depth, and bone loss. However, further evidence-based studies for validation of the classification are still necessary. Peri-implant probing has been proposed as an accurate parameter for peri-implant disease diagnosis.[23,32,33] Histologic studies showed that in the presence of peri-implant inflammatory conditions, the tip of the periodontal probe, when used with a light force (0.2 to 0.3 N), penetrated close to the alveolar bone crest. On the contrary, in the presence of healthy peri-implant conditions, the tip of the probe stopped at the apical extension of the barrier epithelium.[23,32] Therefore, it has been suggested that an increase in the probe penetration is related to an increased degree of peri-implant tissue inflammation.[33] According to different authors, different thresholds are referred to as peri-implant diseases. Etter et al[34] proposed a threshold of at least 6 mm in probing depth for peri-implantitis diagnosis; Froum and Rosen[31] indicated a probing depth value of at least 4, 6, and 8 mm, respectively, for initial, moderate, and severe peri-implantitis diagnosis; Padial-Molina et al[35] used a value > 4 mm to indicate the presence of soft tissue pockets and a value < 4 mm to indicate an initial condition of soft tissue inflammation, whereas Koldsland et al[36] used two probing depth values, ≥ 4 mm and ≥ 6 mm, accordingly, to distinguish different levels of peri-implantitis severity.

A further clinical parameter proposed for peri-implant disease diagnosis is the presence of bleeding on probing. An experimental study[23] reported that bleeding on probing was present in 67% of sites with peri-implant mucositis and 91% of sites with peri-implantitis, whereas it was not detected in healthy peri-implant sites. Bleeding on probing is not only an important parameter for diagnosing peri-implant tissue conditions, but also a predictive parameter for monitoring the peri-implant disease progression.[36,37] The presence of suppuration is another diagnostic parameter, since it is commonly detected in peri-implantitis sites.[38] Bone loss is considered the most important parameter that differentiates peri-implant mucositis from peri-implantitis. In the present study, in accordance with the definition suggested by the First European Workshop on Periodontology,[8] the bone loss functioning time has been evaluated using the rate of bone loss value. This value is obtained by dividing the amount of bone loss by the years of implant functioning, and it indicates the prognosis since it can predict how much bone resorption could be expected every year. At the end of the 5-year follow-up period, peri-implant mucositis was diagnosed in 24 of 74 patients (32.4%) and in 38 of 166 implants (22.8%), whereas peri-implantitis affected 10 of 74 patients (13.5%) and 13 of 166 implants (7.8%). The patient-based incidence of peri-implant diseases found in the 74 patients of the present study is aligned with published data on patients treated in dental private practice. Mir-Mari et al,[39] in a cross-sectional study of 245 private practice patients, found a patient-based peri-implant mucositis and peri-implantitis incidence of 38.8% and 16.3%, respectively. Similar results are also reported in another cross-sectional study by Rinke et al,[12] who collected data on 89 private practice patients and found a patient-based prevalence of peri-implantitis of 11.2% after a mean follow-up period of 5.7 years. A different patient-based peri-implantitis incidence was instead reported in a cross-sectional study by Ferreira et al[40] (8.9% in a sample of 212 patients), and in a retrospective study by Roos-Jansåker et al[41] (16% in a sample of 218 patients). Since a correlation between peri-implant diseases and increased time of loading has already been reported,[40] the different incidence of peri-implant mucositis and peri-implantitis found in the present study, compared with the incidence collected in the aforementioned studies, could be linked with the shorter observation period used by Ferreira et al (3.5 years), and with the longer follow-up period (9 to 14 years) used by Roos-Jansåker et al, but also with a different study design. Considering the 166 implants evaluated, the implant-based incidence for peri-implant mucositis was 22.8%, and for peri-implantitis it was 7.8%. In general, the analysis of affected implants in the total number of patients, and within each group of the present study, confirms some important considerations previously highlighted in the literature: using the implant as a statistic unit, the incidence of peri-implant disease and of peri-implant bone loss is lower than the incidence obtained using the patient as a statistic unit. Consequently, in investigating this kind of disease, the choice of the implant as the unit of statistical analysis could cause the real incidence of the affliction to be underrated. The outcomes of the present study related to the type of prosthesis fixation and design confirm previously reported results[42,43] indicating that peri-implantitis is often associated with cemented and splinted prostheses. A logical explanation for these results could be the presence of residual cement aging as an iatrogenic factor in the cemented prosthesis, the difficulty for the clinician to evaluate the implant site by probing, and the patient not having adequate plaque control. Reported literature data regarding the relationship between keratinized gingiva width and peri-implant tissue health are

© 2018 BY QUINTESSENCE PUBLISHING CO, INC. PRINTING OF THIS DOCUMENT IS RESTRICTED TO PERSONAL USE ONLY.
NO PART MAY BE REPRODUCED OR TRANSMITTED IN ANY FORM WITHOUT WRITTEN PERMISSION FROM THE PUBLISHER.

contrasting.[44,45] According to the results of the present study, implant sites with keratinized gingiva width < 2 mm and ≥ 2 mm did not show statistical differences in the incidence of peri-implant diseases, regardless of their group (with and without laser-microgrooved collar). The mean value of the width of the keratinized gingiva recorded around implants not affected by peri-implant diseases was 1.37 ± 0.63 mm. Although these data seem to suggest that even a small portion of keratinized gingiva may be sufficient for peri-implant health, given the small sample size of the present study, conclusions cannot be drawn, and a possible relationship between the keratinized gingiva width and peri-implant diseases should be considered for future investigations with a greater number of patients and implants.

Comparing the two groups of implants under study, a statistically significantly lower incidence of peri-implant mucositis and peri-implantitis was found in the laser-microgrooved group. Accordingly, the comparative results of the present study indicate that the laser-microgrooved surface on the implant collar may reduce the risk of onset of peri-implant diseases. A logical interpretation of this finding could relate to the capacity of the laser-microtextured surface to influence the peri-implant soft tissue response. Contrary to what has been described for implants with a machined/smooth collar, presenting a circumferential organization of the connective fibers,[46–48] histologic studies in animals and in humans[49,50] documented the presence of a physical connective tissue attachment with connective fibers perpendicularly oriented to the laser-microgrooved implant collar surface. This perpendicular arrangement provides higher support to peri-implant soft tissues than that provided only by the marginal bone. It is known that the marginal bone loss may induce pocket formation, which may promote the onset of peri-implant tissue inflammation.[51,52] At the end of the follow-up period of the present investigation, a statistically significantly lower mean value of probing depth and bone loss was noted around implants with a laser-microgrooved collar, compared to implants without a laser-microgrooved collar. These consistent differences could explain the different incidence of the peri-implant mucositis/peri-implantitis observed between the two studied groups of implants. To the best of the authors' knowledge, only a study by Iorio-Siciliano et al,[20] comparing implants with and without a laser-microgrooved collar surface, reported data after 5 years of loading (0.81 ± 0.24 mm for laser-microgrooved vs 2.02 ± 0.32 mm for not laser-microgrooved). However, a comparison between the results reported by Iorio-Siciliano et al and the results of the present study is difficult. Each patient in the aforementioned study received one dental implant either with or without a laser-microgrooved collar, while in the present study, in each patient, at least one implant with a laser-microgrooved collar and one implant without a laser-microgrooved collar were placed. Using the implant as a statistical unit, as performed by Iorio-Siciliano et al, a statistically underrated incidence may occur, especially in high-risk groups of patients. In addition, Iorio-Siciliano et al reported only the mean value of bone loss, describing the conditions of several implants in the study population, but the mean value could conceal the presence of individual implants with substantially more bone loss than the mean value. According to what has already been suggested in the literature,[36] evaluating the relationship between peri-implant diseases and the degree of bone loss, a little standard deviation of the measurement errors (around laser-microgrooved implants, Iorio-Siciliano et al reported a standard deviation of 0.24 mm) could represent a substantial influential factor in peri-implant disease prevalence estimation.

The differences between collar types and the peri-implant tissue inflammation found in the present study could be linked to the histopathologic features of the peri-implantitis lesion. A comparative study[53] between peri-implantitis and periodontitis lesions carried out on human and animal biopsy specimens showed that in the periodontitis lesions, a connective tissue capsule of supracrestal connective fibers protected the alveolar bone from the progression of the lesion. On the contrary, in the peri-implantitis lesion, a connective tissue capsule that separated the inflammatory cell infiltrate from bone was not detected, and a great amount of neutrophil granulocytes and macrophages extended to the bone crest. It is supposed that the potentiality of the gingiva responding to biofilm accumulation and counteracting early inflammatory processes is associated with physiologic functions of the different structures that constitute the biologic width.[54,55] Accordingly, it is conceivable to assume that the structure and biologic dimensions of the peri-implant biologic width may influence mechanical and biologic defense mechanisms. Around the machined implant neck, collagen fibers are aligned in a direction parallel and circumferential as a fibrous capsule. This involves reduced stability of peri-implant soft tissue. As a connective tissue attachment is supposed to be creating a physical barrier, it is conceivable to speculate that its absence may facilitate an easier apical migration of inflammation. The laser-microgrooved collar surface, promoting a perpendicular, functional physical connective tissue attachment, helps to stabilize the peri-implant soft tissue, which could in turn counteract the early peri-implant inflammatory processes.

The present study has some limitations. The research was designed to evaluate the incidence of

© 2018 BY QUINTESSENCE PUBLISHING CO, INC. PRINTING OF THIS DOCUMENT IS RESTRICTED TO PERSONAL USE ONLY.
NO PART MAY BE REPRODUCED OR TRANSMITTED IN ANY FORM WITHOUT WRITTEN PERMISSION FROM THE PUBLISHER.

peri-implant mucositis and peri-implantitis, without identifying risk factors. Furthermore, the retrospective analyses of data have a limited level of evidence, since the risk of selection, performance, or reporting bias cannot be excluded. However, to minimize the differences, considerable effort was taken to identify two groups, which were as similar as possible regarding age, sex, smoking habit, and compliance with a controlled oral hygienic regimen. Another limitation was the small sample size; one might question the value of the results when only a limited patient population has been observed.

The follow-up period was also a limitation; since peri-implant diseases are among conditions that might need some time before developing, long-term data on the tissue response around implants with a laser-microgrooved collar surface are therefore necessary.

Also, the sample was treated in a private practice setting. Usually, patients treated in universities present more controlled conditions and more homogeneity. However, as most patients are treated in a private practice setting, the present study could provide an increased significance of results, and add further information about peri-implant diseases.

CONCLUSIONS

Within the limits of the present study, it is possible to conclude that in private practice patients enrolled in a strictly controlled oral hygiene regimen, implants with a laser-microgrooved collar surface, compared to implants without a laser-microgrooved collar surface, presented a statistically significantly lower incidence of peri-implant diseases.

ACKNOWLEDGMENTS

The authors reported no conflicts of interest related to this study.

REFERENCES

1. Esposito M, Hirsch JM, Lekholm U, Thomsen P. Biological factors contributing to failures of osseointegrated oral implants. (I). Success criteria and epidemiology. Eur J Oral Sci 1998;106:527–551.
2. Isidor F. Loss of osseointegration caused by occlusal load of oral implants. A clinical and radiographic study in monkeys. Clin Oral Implants Res 1996;7:143–152.
3. Isidor F. Histological evaluation of peri-implant bone at implants subjected to occlusal overload or plaque accumulation. Clin Oral Implants Res 1997;8:1–9.
4. van Steenberghe D, Klinge B, Lindén U, Quirynen M, Herrmann I, Garpland C. Periodontal indices around natural and titanium abutments: A longitudinal multicenter study. J Periodontol 1993;64:538–541.
5. Mombelli A, Lang NP. The diagnosis and treatment of peri-implantitis. Periodontol 2000 1998;17:63–76.
6. Lindhe J, Meyle J, Group D of European Workshop on Periodontology. Peri-implant diseases: Consensus report of the Sixth European Workshop on Periodontology. J Clin Periodontol 2008;35(suppl):s282–s285.
7. Rosen P, Clem D, Cochran D, et al. Peri-implant mucositis and peri-implantitis: A current understanding of their diagnoses and clinical implications. J Periodontol 2013;84:436–443.
8. Albrektsson T, Isidor F. Consensus report of session IV. In: Lang NP, Karring T (eds). Proceedings of the 1st European Workshop on Periodontology, House at Ittingen, Thurgau, Switzerland, February 1–4, 1993. London: Quintessence, 1994:365–369.
9. Zitzmann NU, Berglundh T. Definition and prevalence of peri-implant diseases. J Clin Periodontol 2008;35(suppl):s286–s291.
10. Pjetursson BE, Tan K, Lang NP, Brägger U, Egger M, Zwahlen M. A systematic review of the survival and complication rates of fixed partial dentures (FPDs) after an observation period of at least 5 years. Clin Oral Implants Res 2004;15:667–676.
11. Berglundh T, Persson L, Klinge B. A systematic review of the incidence of biological and technical complications in implant dentistry reported in prospective longitudinal studies of at least 5 years. J Clin Periodontol 2002;29(suppl):s197–s212.
12. Rinke S, Ohl S, Ziebolz D, Lange K, Eickholz P. Prevalence of peri-implant disease in partially edentulous patients: A practice-based cross-sectional study. Clin Oral Implants Res 2011;22:826–833.
13. Charyeva O, Altynbekov K, Zhartybaev R, Sabdanaliev A. Long-term dental implant success and survival—A clinical study after an observation period up to 6 years. Swed Dent J 2012;36:1–6.
14. Atieh MA, Alsabeeha NH, Faggion CM Jr, Duncan WJ. The frequency of peri-implant diseases: A systematic review and meta-analysis. J Periodontol 2013;84:1586–1598.
15. Derks J, Tomasi C. Peri-implant health and disease. A systematic review of current epidemiology. J Clin Periodontol 2015;42(suppl):s158–s171.
16. Esposito M, Coulthard P, Thomsen P, Worthington HV. The role of implant surface modifications, shape and material on the success of osseointegrated dental implants. A Cochrane systematic review. Eur J Prosthodont Restor Dent 2005;13:15–31.
17. Marcantonio C, Nicoli LG, Marcantonio Junior E, Zandim-Barcelos DL. Prevalence and possible risk factors of peri-implantitis: A concept review. J Contemp Dent Pract 2015;16:750–757.
18. Peixoto CD, Almas K. The implant surface characteristics and peri-implantitis. An evidence-based update. Odonotostomatol Trop 2016;39:23–35.
19. Guarnieri R, Serra M, Bava L, Grande M, Farronato D, Iorio-Siciliano V. The impact of a laser-microtextured collar on crestal bone level and clinical parameters under various placement and loading protocols. Int J Oral Maxillofac Implants 2014;29:354–363.
20. Iorio-Siciliano V, Matarasso R, Guarnieri R, Nicolò M, Farronato D, Matarasso S. Soft tissue conditions and marginal bone levels of implants with a laser-microtextured collar: A 5-year, retrospective, controlled study. Clin Oral Implants Res 2015;26:257–262.
21. Guarnieri R, Grande M, Ippoliti S, Iorio-Siciliano V, Riccitiello F, Farronato D. Influence of a Laser-Lok surface on immediate functional loading of implants in single-tooth replacement: Three-year results of a prospective randomized clinical study on soft tissue response and esthetics. Int J Periodontics Restorative Dent 2015;35:865–875.
22. Weinstein T, Bianchi F, Galli F, et al. Peri-implantite. La cartella per il monitoraggio del paziente implantare [in Italian]. Quintessenze Int & JOMI 2015;31:98–101.
23. Persson GR, Samuelsson E, Lindahl C, Renvert S. Mechanical non-surgical treatment of peri-implantitis: A single-blinded randomized longitudinal clinical study. II. Microbiological results. J Clin Periodontol 2010;37:563–573.
24. Lang NP, Berglundh T, Heitz-Mayfield LJ, Pjetursson BE, Salvi GE, Sanz M. Consensus statements and recommended clinical procedures regarding implant survival and complications. Int J Oral Maxillofac Implants 2004;19(suppl):s150–s154.
25. Karoussis IK, Müller S, Salvi GE, Heitz-Mayfield LJ, Brägger U, Lang NP. Association between periodontal and peri-implant conditions: A 10-year prospective study. Clin Oral Implants Res 2004;15:1–7.

© 2018 BY QUINTESSENCE PUBLISHING CO, INC. PRINTING OF THIS DOCUMENT IS RESTRICTED TO PERSONAL USE ONLY.
NO PART MAY BE REPRODUCED OR TRANSMITTED IN ANY FORM WITHOUT WRITTEN PERMISSION FROM THE PUBLISHER.

26. Roos-Jansåker AM, Lindahl C, Renvert H, Renvert S. Nine- to fourteen-year follow-up of implant treatment. Part II: Presence of peri-implant lesions. J Clin Periodontol 2006;33:290–295.
27. Misch CE, Perel ML, Wang HL, et al. Implant success, survival, and failure: The International Congress of Oral Implantologists (ICOI) Pisa Consensus Conference. Implant Dent 2008;17:5–15.
28. Albrektsson T, Zarb G, Worthington P, Eriksson AR. The long-term efficacy of currently used dental implants: A review and proposed criteria of success. Int J Oral Maxillofac Implants 1986;1:11–25.
29. Albrektsson T, Donos N, Working Group 1. Implant survival and complications. The Third EAO consensus conference 2012. Clin Oral Implants Res 2012;23(suppl):s63–s65.
30. Sanz M, Chapple IL, Working Group 4 of the VIII European Workshop on Periodontology. Clinical research on peri-implant diseases: Consensus report of Working Group 4. J Clin Periodontol 2012;39(suppl):s202–s206.
31. Froum SJ, Rosen PS. A proposed classification for peri-implantitis. Int J Periodontics Restorative Dent 2012;32:533–540.
32. Lang NP, Wetzel AC, Stich H, Caffesse RG. Histologic probe penetration in healthy and inflamed peri-implant tissues. Clin Oral Implants Res 1994;5:191–201.
33. Schou S, Holmstrup P, Stoltze K, Hjørting-Hansen E, Fiehn NE, Skovgaard LT. Probing around implants and teeth with healthy or inflamed peri-implant mucosa/gingiva. A histologic comparison in cynomolgus monkeys (Macaca fascicularis). Clin Oral Implants Res 2002;13:113–126.
34. Etter TH, Håkanson I, Lang NP, Trejo PM, Caffesse RG. Healing after standardized clinical probing of the perlimplant soft tissue seal: A histomorphometric study in dogs. Clin Oral Implants Res 2002;13:571–580.
35. Padial-Molina M, Suarez F, Rios HF, Galindo-Moreno P, Wang HL. Guidelines for the diagnosis and treatment of peri-implant diseases. Int J Periodontics Restorative Dent 2014;34:e102–e111.
36. Koldsland OC, Scheie AA, Aass AM. Prevalence of peri-implantitis related to severity of the disease with different degrees of bone loss. J Periodontol 2010;81:231–238.
37. Luterbacher S, Mayfield L, Brägger U, Lang NP. Diagnostic characteristics of clinical and microbiological tests for monitoring periodontal and peri-implant mucosal tissue conditions during supportive periodontal therapy (SPT). Clin Oral Implants Res 2000;11:521–529.
38. Jepsen S, Rühling A, Jepsen K, Ohlenbusch B, Albers HK. Progressive peri-implantitis. Incidence and prediction of peri-implant attachment loss. Clin Oral Implants Res 1996;7:133–142.
39. Mir-Mari J, Mir-Orfila P, Figueiredo R, Valmaseda-Castellón E, Gay-Escoda C. Prevalence of peri-implant diseases. A cross-sectional study based on a private practice environment. J Clin Periodontol 2012;39:490–494.
40. Ferreira CF, Buttendorf AR, de Souza JG, Dalago H, Guenther SF, Bianchini MA. Prevalence of peri-implant diseases: Analyses of associated factors. Eur J Prosthodont Restor Dent 2015;23:199–206.
41. Roos-Jansåker AM, Lindahl C, Renvert H, Renvert S. Nine- to fourteen-year follow-up of implant treatment. Part II: Presence of peri-implant lesions. J Clin Periodontol 2006;33:290–295.
42. Máximo MB, de Mendonça AC, Alves JF, Cortelli SC, Peruzzo DC, Duarte PM. Peri-implant diseases may be associated with increased time loading and generalized periodontal bone loss: Preliminary results. J Oral Implantol 2008;34:268–273.
43. Serino G, Ström C. Peri-implantitis in partially edentulous patients: Association with inadequate plaque control. Clin Oral Implants Res 2009;20:169–174.
44. Wennström JL, Bengazi F, Lekholm U. The influence of the masticatory mucosa on the peri-implant soft tissue condition. Clin Oral Implants Res 1994;5:1–8.
45. Ladwein C, Schmelzeisen R, Nelson K, Fluegge TV, Fretwurst T. Is the presence of keratinized mucosa associated with periimplant tissue health? A clinical cross-sectional analysis. Int J Implant Dent 2015;1:11.
46. Listgarten MA, Lang NP, Schroeder HE, Schroeder A. Periodontal tissues and their counterparts around endosseous implants [corrected and republished with original paging, article originally printed in Clin Oral Implants Res 1991 Jan-Mar;2(1):1–19]. Clin Oral Implants Res 1991;2:1–19.
47. Schupbach P, Glauser R. The defense architecture of the human periimplant mucosa: A histological study. J Prosthet Dent 2007;97(suppl):s15–s25.
48. Degidi M, Piattelli A, Scarano A, Shibli JA, Iezzi G. Peri-implant collagen fibers around human cone Morse connection implants under polarized light: A report of three cases. Int J Periodontics Restorative Dent 2012;32:323–328.
49. Nevins M, Kim DM, Jun SH, Guze K, Schupbach P, Nevins ML. Histologic evidence of a connective tissue attachment to laser microgrooved abutments: A canine study. Int J Periodontics Restorative Dent 2010;30:245–255.
50. Nevins M, Nevins ML, Camelo M, Boyesen JL, Kim DM. Human histologic evidence of a connective tissue attachment to a dental implant. Int J Periodontics Restorative Dent 2008;28:111–121.
51. Hermann JS, Cochran DL, Nummikoski PV, Buser D. Crestal bone changes around titanium implants. A radiographic evaluation of unloaded nonsubmerged and submerged implants in the canine mandible. J Periodontol 1997;68:1117–1130.
52. Berglundh T, Lindhe J, Erricson I, Marinello C, Liljenberg B, Thomsen P. The soft tissue barrier at implants and teeth. Clin Oral Implants Res 1991;2:81–90.
53. Berglundh T, Zitzmann NU, Donati M. Are peri-implantitis lesions different from periodontitis lesions? J Clin Periodontol 2001;38(suppl):s188–s202.
54. Apse P, Ellen RP, Overall CM, Zarb GA. Microbiota and crevicular fluid collagenase activity in the osseointegrated dental implant sulcus: A comparison of sites in edentulous and partially edentulous patients. J Periodontal Res 1989;24:96–105.
55. Cochran DL, Hermann JS, Schenk RK, Higginbottom FL, Buser D. Biologic width around titanium implants. A histometric analysis of the implanto-gingival junction around unloaded and loaded nonsubmerged implants in the canine mandible. J Periodontol 1997;68:186–198.

© 2018 BY QUINTESSENCE PUBLISHING CO, INC. PRINTING OF THIS DOCUMENT IS RESTRICTED TO PERSONAL USE ONLY.
NO PART MAY BE REPRODUCED OR TRANSMITTED IN ANY FORM WITHOUT WRITTEN PERMISSION FROM THE PUBLISHER.