Implants With and Without Laser-Microtextured Collar: A 10-Year Clinical and Radiographic Comparative Evaluation

Renzo Guarnieri, MD, DDS,* Rolando Ceccarelli, DDS,† John L. Ricci, PhD,‡ and Tiziano Testori, MD, DDS§

Introduction: *This article reports, after at least 10 years of follow-up, the comparative data of marginal bone loss (MBL) and periimplant soft tissue parameters, around implant with and without laser-microtextured (L) collar surface, previously reported at 3 years of follow-up.*

Materials and Methods: *Twenty implants with L collar surface (test) were placed adjacent to 20 control implants with machined (M) collar surface in 15 partially edentulous patients, who were followed up for at least 10 years as part of a prospective longitudinal study. The plaque score, bleeding on probing (BoP) score, and probing depth (PD) were recorded at baseline and at each year follow-up examination. Mucosal recession (MR), and radiographic MBL were assessed at baseline and after at least 10 years.*

Results: *Four patients were lost during follow-up, so the number of implants that have been followed for at least 10 years was 32 (16 tests and 16 controls). At the end of the follow-up period, no significant differences were found between the study groups regarding the presence of plaque and BoP (*$P > 0.05$*). A statistically significant difference between test and control implant was found for mean PD (*2.3 ± 0.7* mm vs *3.8 ± 0.8*), MBL (*1.23 ± 0.21* mm vs *2.8 ± 0.9* mm), and mean MR (*1.08 ± 0.4* mm vs *2.46 ± 0.3* mm).*

Conclusion: *Results suggest that after at least 10 years of function, implants with laser-microtexturing (L) collar surface, compared with implants with machined surface, lead to lower MBL and PD. (Implant Dent 2017;27:1–8)*

Key Words: osteointegrated implants, laser-microtextured collar surface, marginal bone loss

During the past decades, several macroscopic and microscopic features of dental implants have been proposed with the aim to control bone and soft tissue response. One of the most significant breakthroughs has been the introduction of a laser-microtextured (L) implant collar surface. This surface has highly oriented, consistent microstructures that are applied using computer-controlled laser ablation techniques by means of a pulsed, computer-controlled Excimer laser system and large-area masking. Preliminary *in vitro* studies[1–5] showed that the L surface presents a high potential for the growth of fibroblast cell types and effective inhibition of epithelial cell migration across the grooves. Subsequent histological analysis[6–10] in animal model and in humans documented the presence of a physical connective tissue attachment with fibers perpendicularly oriented to laser-produced microgrooves on implant collar surface. Consequently, it has been suggested that the L surface on the collar of dental implants could act at a predetermined site to attract physical connective tissue attachment and to restrict apical migration of gingival epithelium, preserving the coronal level of bone. Several subsequent clinical studies[11–17] reported a consistent difference in probing depth (PD) and marginal bone loss (MBL) between the implant pairs, with and without the L implant collar treatment. However, no data are present in the literature on the impact of the L surface on long-term clinical outcomes. Therefore, this study was aimed at comparing the long-term success rate, MBL, and periimplant soft tissue parameters around implant with

*Adjunct Professor, Department of Dental and Maxillofacial Sciences, School of Dentistry, University La Sapienza, Rome, Italy; Private Periodontal-Implant Practice, Treviso, Italy.
†Private Implant Practice, Lucca, Italy.
‡Associate Professor Program Director, Master's Program in Biomaterials Science, New York University College of Dentistry Biomaterials, New York, NY.
§Head of the Section of Implantology and Oral Rehabilitation, Department of Odontology, IRCCS Galeazzi, University of Milan, Milan, Italy; Adjunct Clinical Associate Professor, Department of Periodontics and Oral Medicine The University of Michigan, School of Dentistry Ann Arbor, Michigan, Private Practice, Como, Italy.

Reprint requests and correspondence to: Renzo Guarnieri, MD, DDS, via L Cattarin 3D, 31100 Treviso, Italy, Phone: +39 3425224458, Fax: +39 (0) 422 1781255, E-mail: renzoguarnieri@gmail.com

ISSN 1056-6163/17/02701-001
Implant Dentistry
Volume 27 • Number 1
Copyright © 2017 Wolters Kluwer Health, Inc. All rights reserved.
DOI: 10.1097/ID.0000000000000718

Copyright © 2017 Wolters Kluwer Health, Inc. Unauthorized reproduction of this article is prohibited.



Fig. 1. Microphotography (×700) of the laser-microtextured (L) collar surface of the test implants.

and without L collar surface. Three-year data on radiographic MBL and clinical parameters, including PD, plaque index (PI), and bleeding on probing (BoP), have been previously reported.[11]

MATERIALS AND METHODS

Two tapered implants (Silhouette BioLoK; now commercialized by BioHorizons, Birmingham, AL) with a reverse buttress thread design and a 2-mm wide collar were used in this study. The body of implants has been roughened by blasting with a resorbable blast media. The L implant (test) has the same body design and screw area surface treatment of the machined (M) control implant, but has a laser micromachined collar (Fig. 1). This implant has a 2-mm wide collar that has been laser microgrooved in the lower 1.5 mm. Each patient received 2 single tooth implants, with and without laser surface treatment. All implants were restored at 4 months postoperatively. The study was performed with 5 investigators and a total of 15 patients who received 20 sets of implants. For further details regarding study population, recruitment, and materials and methods, refer the study by Pecora et al.[11] As described in the previous publication, PD (the average of 4 measurements taken at the mesial, buccal, distal, and lingual surfaces of the implant) and MBL (average of the 2 radiographic measurements taken at the mesial and distal locations of the implant) were considered effectiveness end points. The PI and BoP were considered safety end points. Each of these safety end points were measured at the mesial and distal locations of the implant on a 4-point scale. Categories of 0 (no plaque detected), 1 (plaque was noted only by running a probe across the smooth marginal surface of the implant), 2 (plaque could be seen by the naked eye), and 3 (an abundance of soft matter) were considered for the PI. Categories of 0 (no bleeding when a periodontal probe was passed along the gingival margin adjacent to the implant), 1 (only isolated bleeding was visible), 2 (blood formed a confluent red line on the margin), and 3 (presence of heavy or profuse bleeding) were considered for the BoP index.

Follow-up Examination

All patients were recalled every 6 months for professional oral hygiene.

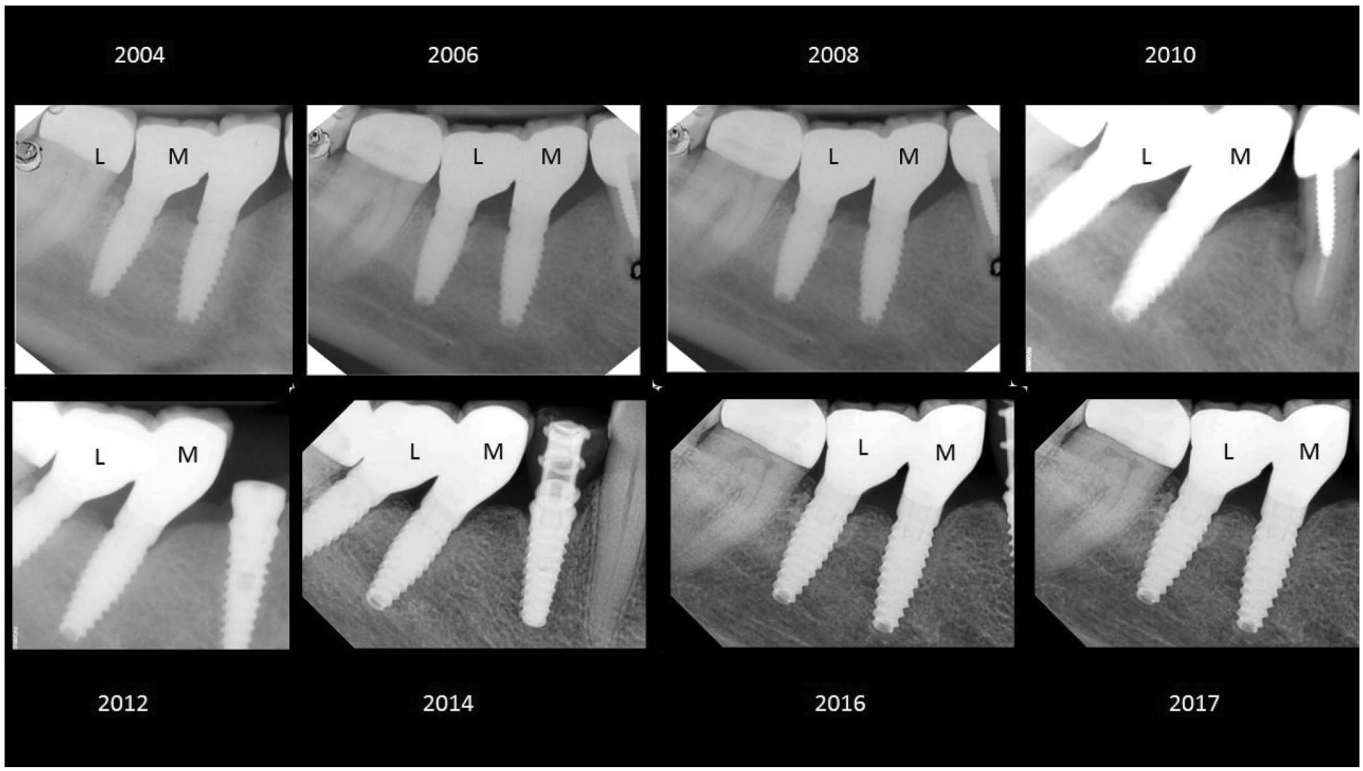

Fig. 2. Radiographic MBL around L and M implants recorded during the follow-up period.

Copyright © 2017 Wolters Kluwer Health, Inc. Unauthorized reproduction of this article is prohibited.

Table 1. Plaque Index, Test Implants Versus Control Implants, Followed for 10 Years

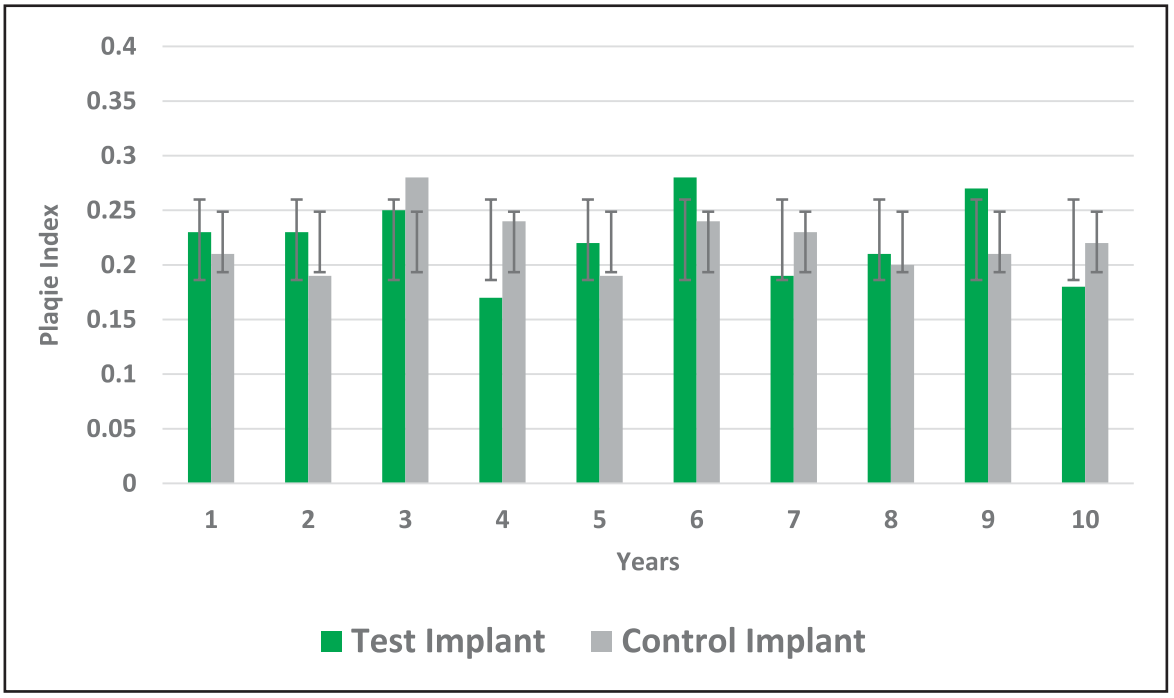

Error bars = SE: not significantly different for all time.

Table 2. Bleeding on Probing (BoP), Test Implants Versus Control Implants Followed for 10 Years

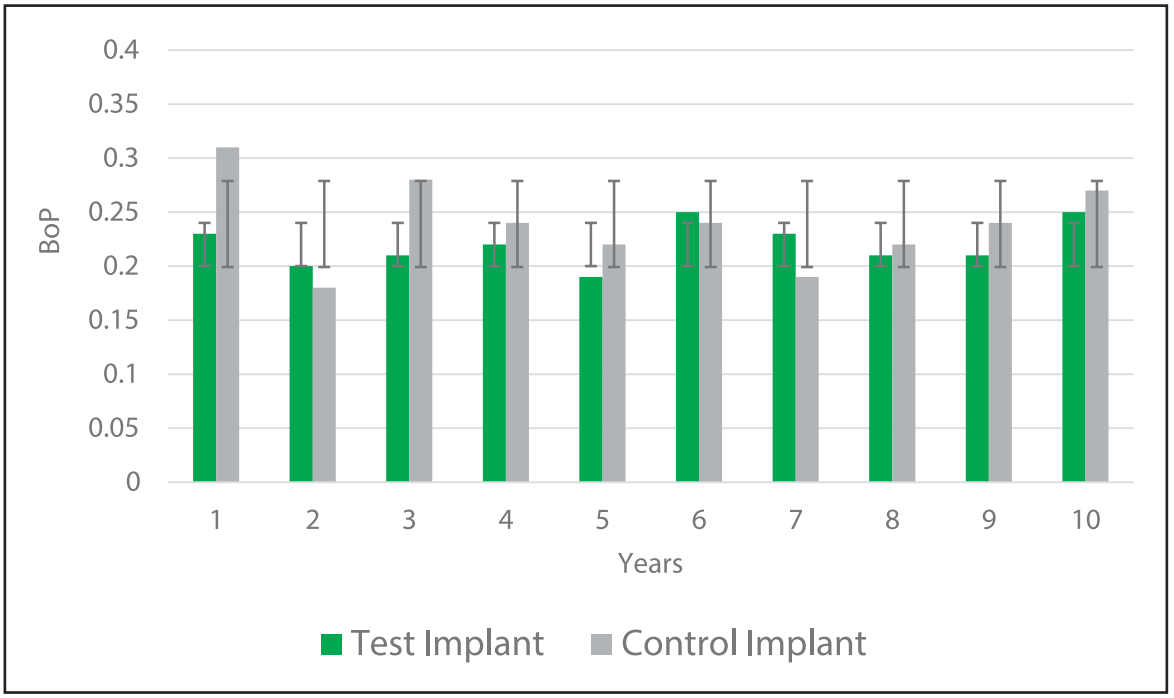

Error bars = SE: not significantly different for all time.

Copyright © 2017 Wolters Kluwer Health, Inc. Unauthorized reproduction of this article is prohibited.

Table 3. Mucosal Recession, Test Implants Versus Control Implants at 10 Years

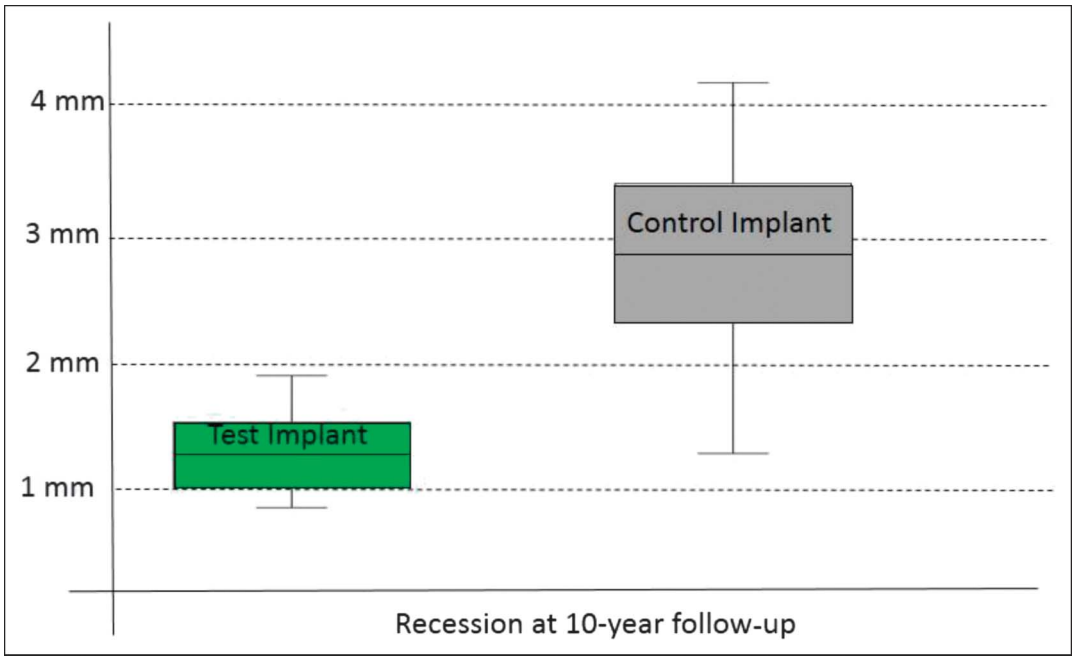

Error bars = SE: significantly different ($P < 0.05$).

Table 4. PD, Test Implants Versus Control Implants, Followed for 10 Years

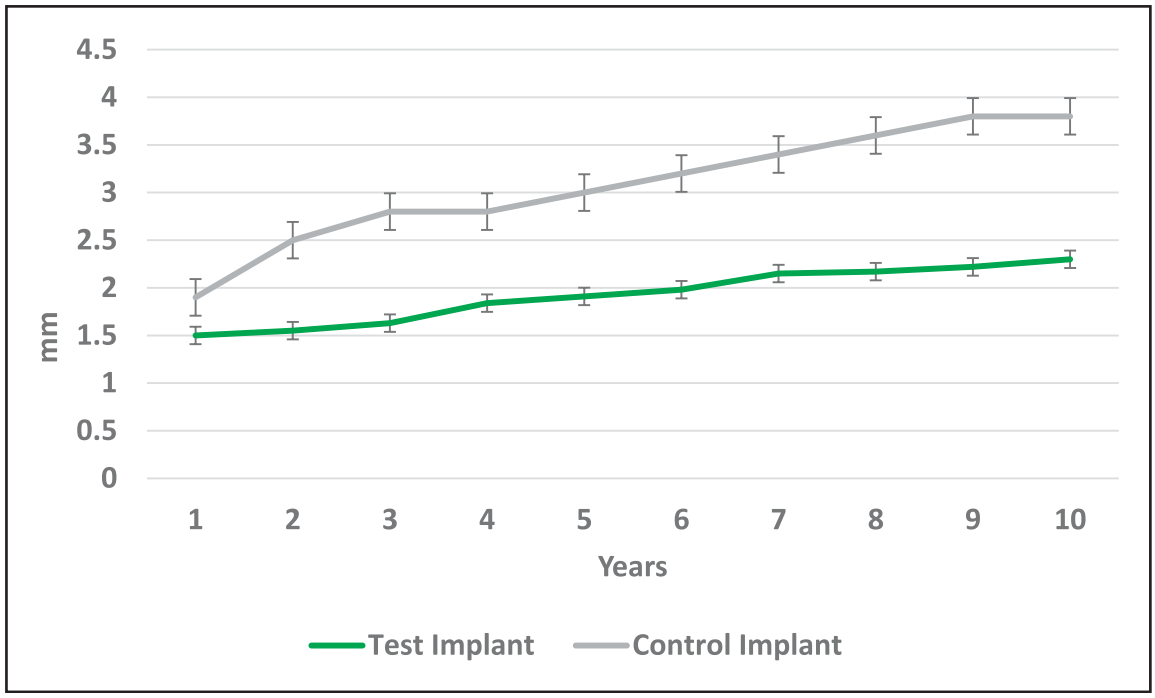

Error bars = SE: significantly different for all ($P < 0.05$).

Copyright © 2017 Wolters Kluwer Health, Inc. Unauthorized reproduction of this article is prohibited.

Table 5. Marginal Bone Loss, Test Implants Versus Control Implants, Followed for 10 Years

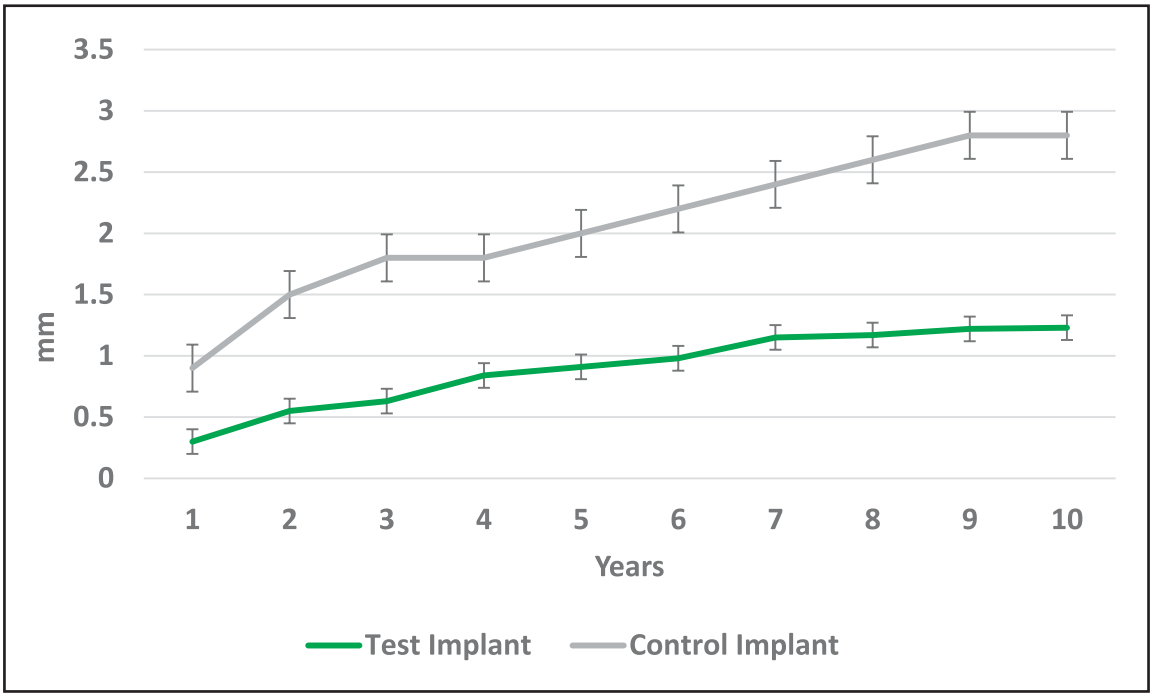

Error bars = SE: significantly different for all time ($P < 0.05$).

Every year during the recall visit, the following parameters were considered: PI, PD, and BoP. After at least 10 years, mucosal recession (MR) was recorded.

Radiographic Examinations

Radiographic examinations were performed at the time of crown placement (baseline) and at each year observation visit. All the radiographs were taken by applying the long-cone technique and using a film holder. The films were digitized at a precision of 1200 dpi. The location of the marginal bone levels in relation to the implant shoulder was assessed at the mesial and the distal aspect using a software program (VixWin Platinum Imaging Software; Gendex, Des Plaines, IL). The digitized images were scaled to the known distance between the implant threads. The radiographic MBL was calculated by subtracting the marginal bone level at baseline from marginal bone level at at least 10-year follow up. The radiographic MBL during the follow-up period around L and M implants in 1 patient included in the study is reported in Figure 2.

Statistical Analysis

A comparison between mean values was done using *t* tests for all measurements and the resulting *P* values were recorded. Nonparametric methods (Kruskal-Wallis test) were used to compare age and sex, PI, PD, MR, and MBL, both within and between groups, at baseline and at 10-year follow-up T5. An alpha error of 0.05 was set to accept a statistically significant difference.

RESULTS

Four patients were lost to follow-up, so the number of implants that have been followed for at least 10 years was 32 (16 tests and 16 controls). After the 10-year follow-up period, the survival rate was 100% for both implants (L and M). At 10-year follow-up, no significant differences were found between the study groups regarding the presence of plaque and BoP ($P > 0.05$) (Tables 1 and 2). Table 3 summarizes the PD recorded at baseline and after 10-year follow-up. Test implants showed at baseline a mean value PD of 1.5 ± 0.4 mm, and after the 10-year follow-up period, the PD was 2.3 ± 0.7 mm. No significant differences were found between the baseline and the 10-year follow-up period ($P > 0.05$). The control implants showed at baseline a mean PD value of 1.7 ± 0.6 mm, and at 10-year follow-up, the PD was 3.8 ± 0.8 mm, with a statistically significant difference ($P < 0.05$). In Table 4, the mean MR values after the 10-year follow-up period are reported. After the 10-year observation time, the mean MR value in the test implants was 1.08 ± 0.4 mm and in control implants was 2.46 ± 0.3 mm. The difference was statistically significant ($P < 0.05$). Radiographic results are reported in Table 5. At the end of follow-up period, the test implants showed a mean MBL value of 1.23 ± 0.21, whereas in the control implants, the mean MBL value was 2.8 ± 0.9 mm. The difference was statistically significant ($P < 0.05$). In both groups, no cases of periimplantitis (PD ≥5 mm with BoP or suppuration and radiographic bone loss ≥2 mm) were found. Two cases of periimplant mucositis (PD <5 mm with BoP and radiographic bone loss <2 mm) were recorded in the

Copyright © 2017 Wolters Kluwer Health, Inc. Unauthorized reproduction of this article is prohibited.

control group, whereas no cases of periimplant mucositis were found in the test group.

DISCUSSION

The MBL and PD mean values recorded around test and control implants are the most interesting result of the present study that aimed at evaluating the long-term comparative results between 2 implants with same body design and surface, but with different collar surface (L vs M). The MBL around dental implants is an important indicator of periimplant health because periimplant bone loss may induce pocket formation, which could be unfavorable for the longterm health of the periimplant tissues.[18,19] The mean MBL value accepted as the criterion of a successful implant should be less than 1 to 1.5 mm during the first year after implant loading and less than 0.2 mm annually.[20] Although there is a shared acceptance of these values, MBL still represented one of the most important factors focused in implant dentistry, and until now, its etiopathogenesis is not clarified.[21] Surgical trauma, the establishment of biologic width, the lack of passive fit of the superstructures, the presence of a microgap at implant, abutment interface, occlusal overload, and implant neck design are among the possible etiologic factors. However, because the study population has several confounding factors simultaneously, it seems difficult to isolate risk factors as a separate study. The influence of the implant collar surface on MBL around implants has been discussed only recently and has received little attention in comparison to other factors.[22–25] Implant collars had traditionally machined/smooth surface because it results in reduced plaque accumulation and thus presumably prevents periimplant inflammation.[20] However, *in vitro* investigations,[26,27] revealing high stress concentrations in the area of crestal bone around the machined collar of dental implants, suggested that MBL might be partially attributed to the lack of favorable stress distributions at the coronal portion of the implant. On the contrary, *in vitro* evaluation of the effect of implant collar roughness, microthread, and microgrooves suggested that bone retention elements might counteract the marginal bone resorption and might help to stabilize the marginal bone.[28,29] However, few clinical research studies has been aimed at comparing data on MBL of implants with different collar surfaces. Studies by Lee et al,[30] Kang et al,[31] and Song et al,[32] evaluating the effects on MBL of implants with a roughened neck with or without microthreads, concluded that a microthread design in the implant neck can significantly reduce the amount of MBL under functional loading. Same findings on MBL are reported also in studies by Bratu et al[33] and Nickenig et al,[23] which compared the effects of implants with a roughened microthreaded neck and polished neck. However, results of Bratu et al, and Nickenig et al, showing that the difference between a roughened neck with microthreads and a machined neck without microthreads was even larger, indicate that both the roughened and microthreads have an effect on MBL. The different influence on MBL of rough and rough-microthreaded collar compared with machined surface has been also confirmed by a recent systematic review with meta-analysis.[34] However, in the selected studies, the presence of several confounding factors, such as, surface topography, study design, follow-up period, prostheses design, implant–abutment connection with or without platform switching, makes it difficult to draw conclusions and suggests that results should be interpreted cautiously. As far as our knowledge is concerned, only 1 study reports comparative data on MBL of implants with machined collar, microthreaded collar, and L collar.[35] Histological results, obtained from an animal model, showed that L implant collars had a lower MBL mean value (0.26 mm) compared with machined (1.63 mm) and microthreaded collar (0.56 mm) and a slightly higher mean value of bone-implant contact of coronal 2 mm (41.02%) than in implants with machined collar (30.49%) and with microthreaded collar (22.56%). These results suggest that the influence of implant collar surface against the MBL around the implant might not only be related to the presence of retention elements, which might reduce the peak interfacial shear stress on marginal bone, but also to other factors, among which the significant effect of the mechanical substrate supporting biologic tissue and its nanofeatures on cell growth. Laser microgrooves created by laser ablation are smaller in dimension than machine-tooled microthreads. Moreover, the nanotopography of laser microgrooves is more pronounced, having knobs with rounded edges and some undercuts (Fig. 1), whereas blasted surfaces on machine-tooled microthreads show random nanoroughness and somewhat sharp edges. Electron microscopic results[35–37] suggested that L micro-geometry acts like an extracellular matrix as a complex 3-dimensional scaffold for cell and tissue attachment. Cultured fibroblasts grown on microgrooved surfaces become oriented and channeled in line with the grooves, whereas cells grown on nongrooved surfaces showed random growth. These *in vitro* results have provided the hypothesis that L surfaces could be used to control soft tissue responses to collar implant. This has been subsequently demonstrated by histologic research in an animal model and in humans,[6–10] which has documented the presence of a physical connective tissue attachment onto laser-produced microgrooves on collar implant, which acts as a seal to apical migration of gingival epithelial cells, providing a greater soft tissue support to the implant. Moreover, the ability to form a stable soft tissue seal around L implant collar has been documented by several clinical studies,[11–17] which reported a statistical difference in PD and MBL between implants with and without L collar surface. Results of the present long-term study confirm the previous reported results with a lower follow-up period (3–5 years) and indicate that after at least 10 years of function, implants with L surface, compared with implants with machined surface, show better hard and soft periimplant tissue conditions. The consistent difference in PD and MBL between the implant pairs with and without LM collar surface implies that a soft tissue seal above the bone has been established and

Copyright © 2017 Wolters Kluwer Health, Inc. Unauthorized reproduction of this article is prohibited.

maintained during the long-term period in the L implanted sites. In addition, the clinical indexes that were used to evaluate the quality of the soft tissues surrounding the implants (ie, PI, BoP, and MR) indicate that after at least 10 years of function around L implants there is no increase in these inflammation measures.

To minimize the differences in the examined sample, considerable effort was taken to identify the implant sites (L and M) as similar as possible regarding, diameter and position, bone volume, and prosthetic factors, such as abutment selection, occlusion, and accuracy of fit. However, a limitation to the present study is the absence of another control group including implants with microthread collar. Another limitation is the small sample size, and one might question the value of the results only when a limited number of implants and patients have been observed. Accordingly, final confirmation of findings needs further studies with an increased number of implants and patients.

Conclusions

Within the limitations of this study, results suggest that after at least 10 years of function, implants with laser collar surface, compared with implants with machined collar surface, reduced the level of MBL and PD, providing more favorable conditions for the attachment of hard and soft tissues.

Disclosure

This study was performed with a BioHorizons grant that provided the materials. The authors claim to have no financial interest, either directly or indirectly, in the products or information listed in the article.

Role/Contribution of Coauthors

R. Guarnieri: substantial contributions to research design, acquisition of data, analysis of data, interpretation of data, and drafting the manuscript. R. Ceccarelli: substantial contributions to research design, acquisition of data, revising the manuscript critically, and approval of the submitted and final versions. J. L. Ricci: substantial contributions to research design, revising the manuscript critically, and approval of the submitted and final versions. T. Testori: substantial contributions to research design, acquisition of data, revising the manuscript critically, and approval of the submitted and final versions.

References

1. Dalby MJ, Riehle MO, Johnstone H, et al. Investigating the limits of filopodial sensing: A brief report using SEM to image the interaction between 10 nm high nano-topography and fibroblast filopodia. *Cell Biol Int.* 2004;28:229–236.

2. Wang RC, Hsieh MC, Lee TM. Effects of nanometric roughness on surface properties and fibroblast's initial cytocompatibilities of Ti6Al4V. *Biointerphases*. 2011;6:87–96.

3. Ricci JL, Grew JC, Alexander H. Connective- tissue responses to defined biomaterial surfaces. I. Growth of rat fibroblast and bone marrow cell colonies on microgrooved substrates. *J Biomed Mater Res A.* 2008;85:313–325.

4. Grew JC, Ricci JL, Alexander H. Connective- tissue responses to defined biomaterial surfaces. II. Behavior of rat and mouse fibroblasts cultured on microgrooved substrates. *J Biomed Mater Res A.* 2008;85:326–335.

5. Dumas V, Rattner A, Vico L, et al. Multiscale grooved titanium processed with femtosecond laser influences mesenchymal stem cell morphology, adhesion, and matrix organization. *J Biomed Mater Res A.* 2012;100:3108–3116.

6. Nevins M, Kim DM, Jun SH, et al. Histologic evidence of a connective tissue attachment to laser microgrooved abutments: A canine study. *Int J Periodontics Rest Dent.* 2010;30:245–255.

7. Shin SY, Han DH. Influence of microgrooved collar design on soft and hard tissue healing of immediate implantation in fresh extraction sites in dogs. *Clin Oral Implants Res.* 2010;21:804–814.

8. Iglhaut G, Becker K, Golubovic V, et al. The impact of dis/reconnection of laser microgrooved and machined implant abutments on soft and hard-tissue healing. *Clin Oral Implants Res.* 2013;24:391–397.

9. Nevins M, Nevins ML, Camelo M, et al. Human histologic evidence of a connective tissue attachment to a dental implant. *Int J Periodontics Restorative Dent.* 2008;28:111–121.

10. Nevins M, Camelo M, Nevins ML, et al. Reattachment of connective tissue fibers to a laser microgrooved abutment surface. *Int J Periodontics Restorative Dent.* 2012;32:e131–e134.

11. Pecora GE, Ceccarelli R, Bonelli M, et al. Clinical evaluation of laser microtexturing for soft tissue and bone attachment to dental implants. *Implant Dent.* 2009;18:57–66.

12. Shapoff CA, Lahey B, Wasserlauf PA, et al. Radiographic analysis of crestal bone levels around Laser-Lok collar dental implants. *Int J Periodontics Restorative Dent.* 2010;30:129–137.

13. Botos S, Yousef H, Zweig B, et al. The effect of laser microtexturing of the dental implant collar on crestal bone levels and peri-implant health. *Int J Oral Maxillofac Implants.* 2011;26:492–498.

14. Guarnieri R, Serra M, Bava L, et al. The impact of laser microtexturing collar designs on crestal bone level, and clinical parameters under various placement and loading protocols. *Int J Oral Maxillofac Implants.* 2014;29:354–363.

15. Farronato D, Mangano F, Briguglio F, et al. Influence of laser-lok surface on immediate functional loading of implants in single-tooth replacement: A 2-year prospective clinical study. *Int J Periodontics Restorative Dent.* 2014;34:79–89.

16. Iorio-Siciliano V, Matarasso R, Guarnieri R, et al. Soft tissue conditions and marginal bone levels of implants with a laser-microtextured collar: A 5-year, retrospective, controlled study. *Clin Oral Implants Res.* 2015;26:257–262.

17. Guarnieri R, Grande M, Ippoliti S, et al. Influence of a laser-lok surface on immediate functional loading of implants in single-tooth replacement: Three-year results of a prospective randomized clinical study on soft tissue response and esthetics. *Int J Periodontics Restorative Dent.* 2015;35:865–875.

18. Hermann JS, Cochran DL, Nummikoski PV, et al. Crestal bone changes around titanium implants. A radiographic evaluation of unloaded non submerged and submerged implants in the canine mandible. *J Periodontol.* 1997;68:1117–1130.

19. Albrektsson T, Donos N; Working Group 1. Implant survival and complications. The Third EAO consensus conference. *Clin Oral Implants Res.* 2012;23(suppl 6):63–65.

20. Albrektssson T, Zarb G, Wortington P, et al. The long-term efficacy of currently used dental implants: A review

Copyright © 2017 Wolters Kluwer Health, Inc. Unauthorized reproduction of this article is prohibited.

and proposed criteria of success. *Int J Oral Maxillofac Implants.* 1986;1:11–25.

21. Albrektsson T, Dahlin C, Jemt T, et al. Is marginal bone loss around oral implants the result of a provoked foreign body reaction? *Clin Implant Dent Relat Res.* 2014;16:155–165.

22. Bateli M, Att W, Strub JR. Implant neck configurations for preservation of marginal bone level: A systematic review. *Int J Oral Maxillofac Implants.* 2011;26: 290–303.

23. Nickenig HJ, Wichmann M, Happe A, et al. A 5-year prospective radiographic evaluation of marginal bone levels adjacent to parallel-screw cylinder machined neck implants and rough-surfaced microthreaded implants using digitized panoramic radiographs. *J Cranio Maxillofac Surg.* 2013;41:564–568.

24. Sánchez-Siles M, Muñoz-Cámara D, Salazar-Sánchez N, et al. Incidence of peri-implantitis and oral quality of life in patients rehabilitated with implants with different neck designs: A 10-year retrospective study. *J Craniomaxillofac Surg.* 2016;43:2168–2174.

25. Calvo-Guirado JL, López-López PJ, Pérez-Albacete Martínez C, et al. Peri-implant bone loss clinical and radiographic evaluation around rough neck and microthread implants: A 5-year study. *Clin Oral Implants Res.* 2016;00:1–9.

26. Sadrimanesh R, Siadat H, Sadr-Eshkevari P, et al. Alveolar bone stress around implants with different abutment angulation: An FE-analysis of anterior maxilla. *Implant Dent* 2012;21:196–201.

27. Pierrisnard L, Renouard F, Renault P, et al. Influence of implant length and bicortical anchorage on implant stress distribution. *Clin Implant Dent Rel Res.* 2003;5:254–262.

28. Hansson S. The implant neck: Smooth or provided with retention elements. A biomechanical approach. *Clin Oral Implants Res.* 1999;10:394–405.

29. Alexander H, Ricci JL, Hrico GJ. Mechanical basis for bone retention around dental implants. *J Biomed Mater Res B Appl Biomater.* 2009;88:306–311.

30. Lee DW, Choi YS, Park KH, et al. Effect of microthread on the maintenance of marginal bone level: A 3-year prospective study. *Clin Oral Implants Res.* 2007; 18:465–470.

31. Kang YI, Lee DW, Park KH, et al. Effect of thread size on the implant neck area: Preliminary results at 1 year of function. *Clin Oral Implants Res.* 2012;23: 1147–1151.

32. Song DW, Lee DW, Kim CK, et al. Comparative analysis of peri-implant marginal bone loss based on microthread location: A 1-year prospective study after loading. *J Periodontol.* 2009;80:1937–1944.

33. Bratu EA, Tandlich M, Shapira L. A rough surface implant neck with microthreads reduces the amount of marginal bone loss: A prospective clinical study. *Clin Oral Implants Res.* 2009;20: 827–832.

34. Koodaryan R, Hafezeqoran A. Evaluation of implant collar surfaces for marginal bone loss: A systematic review and meta-analysis. *Biomed Res Int.* 2016;2016:4987526.

35. Ricci JL, Charvet J, Frenkel SR, et al. Bone response to laser microtextured surfaces. In: Davies JE, ed. *Bone Engineering*. Toronto, ON: EM2 Inc; 2000:282–294; Chapter 25.

36. Frenkel SR, Simon J, Alexander H, et al. Osseointegration on metallic implant surfaces: Effects of microgeometry and growth factor treatment. *J Biomed Mater Res.* 2002;63:706–713.

37. Bae HEK, Chung MK, Cha IH, et al. Marginal tissue response to different implant neck design. *J Korean Acad Prosthodont.* 2008;46:609.

Copyright © 2017 Wolters Kluwer Health, Inc. Unauthorized reproduction of this article is prohibited.