

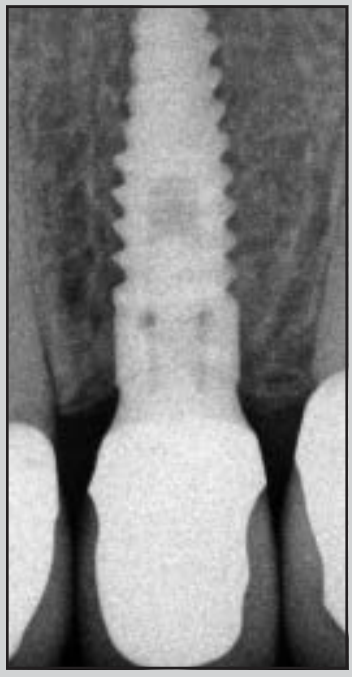

© 2015 BY QUINTESSENCE PUBLISHING CO, INC. PRINTING OF THIS DOCUMENT IS RESTRICTED TO PERSONAL USE ONLY.
NO PART MAY BE REPRODUCED OR TRANSMITTED IN ANY FORM WITHOUT WRITTEN PERMISSION FROM THE PUBLISHER.

Influence of a Laser-Lok Surface on Immediate Functional Loading of Implants in Single-Tooth Replacement: Three-Year Results of a Prospective Randomized Clinical Study on Soft Tissue Response and Esthetics



Renzo Guarnieri, MD, DDS[1]
Maurizio Grande, DDS[2]
Stefano Ippoliti, DDS[3]
Vincenzo Iorio-Siciliano, DDS, PhD[4]
Francesco Riccitiello, MD[5]*/Davide Farronato, DDS, PhD*[6]

The purpose of the present prospective randomized study was to evaluate the influence of Laser-Lok microtextured surface on soft tissue peri-implant parameters and esthetics around immediate, functionally loaded implants for single-tooth replacement in the esthetic zone. This study included 77 patients divided into two groups based on different implants used: the control group had BioHorizons tapered internal non-Laser-Lok–type implants (NLL; n = 39) and the test group had BioHorizons tapered internal Laser-Lok–type implants (LL; n = 39). Outcome measures were survival, radiographic marginal bone–level changes, soft tissue parameters, and esthetics. One implant was lost in the test group and one in the control group, for a total survival rate of 96.1% after 3 years. Radiographically, mean crestal bone loss ± standard deviation was 0.59 ± 0.27 mm in the LL group compared with 1.17 ± 0.31 mm in the NLL group. A mean gain in papilla level of 0.41 ± 0.34 mm and 0.17 ± 0.36 mm was observed in the LL and the NLL groups, respectively, while the level of the midfacial peri-implant mucosa remained stable in both groups with no statistically significant differences (0.08 ± 0.42 mm for the LL group vs 0.06 ± 0.36 mm for the NLL group). The mean probing depth values in the LL and NLL groups were 0.58 ± 0.2 mm and 1.89 ± 0.3 mm, respectively. Within the limitations of this study, it was demonstrated that the clinical and esthetic outcome of immediate functional loading was more favorable for LL implants than for NLL implants. (Int J Periodontics Restorative Dent 2015;35:865–875. doi: 10.11607/prd.2273)

[1]Private Practice in Implant and Periodontal Dentistry; Freelance Researcher, SCS Scientific Consulting Services, Rome, Italy.
[2]Private Practice in Implant Dentistry, Rome, Italy.
[3]Private Practice in Prosthetics, Rome, Italy.
[4]Assistant Professor, Department of Periodontology, University of Napoli Federico II, Naples, Italy.
[4]Department of Restorative Dentistry, University of Napoli Federico II, Naples, Italy.
[5]Assistant Professor, Department of Biomaterial Sciences, Insubria University, Varese, Italy.

Correspondence to: Dr Renzo Guarnieri, via Deserto di Gobi 85/A/2, 00144 Rome, Italy.
Email: renzoguarnieri@gmail.com

©2015 by Quintessence Publishing Co Inc.

Single implant treatment in the esthetic zone is considered highly predictable and successful, at least in terms of implant survival and hard tissue remodeling after conventional implant surgery.[1] In recent years, high clinical success rates with the original treatment protocol have given clinicians confidence to further develop and refine the osseointegration technique. Shorter treatment periods, to allow immediate or early loading of implants, have been advocated even for single implant treatments in the esthetic zone.[2,3] *Immediate and early loading* are defined as the application of a load by means of an occluding or nonoccluding restoration within 48 hours of implant placement.[4] However, because the applied load is often reduced or even absent in single tooth replacement, it has also been proposed to use the term *immediate/early function* rather than immediate/early loading.[5] Even though a number of reports are available on immediate single implant treatment in the esthetic zone, few prospective studies have been published with data on soft tissue dynamics and esthetics.[3,6–9] Therefore, the aim of this study was to compare the clinical and esthetic outcome of immediate nonocclusal loading, using two different implants to replace missing anterior teeth. Both types of

© 2015 BY QUINTESSENCE PUBLISHING CO, INC. PRINTING OF THIS DOCUMENT IS RESTRICTED TO PERSONAL USE ONLY.
NO PART MAY BE REPRODUCED OR TRANSMITTED IN ANY FORM WITHOUT WRITTEN PERMISSION FROM THE PUBLISHER.

implants have the same design and the same surfaces treated with resorbable blast media, with the exception that the Laser-Lok implant has a dual bioaffinity collar consisting of two types of laser microtexturing grooves (8 μm and 12 μm). The first published clinical data on this kind of surface reported a consistent difference in marginal bone loss, probing depth (PD), and mucosal recession between the implant pairs with and without the laser-microtextured implant collar treatment.[10–15] Thus, the research hypothesis of this study was that the laser-microtexturing collar surface on the implant neck may influence esthetic outcomes and soft tissue responses using an immediate loading protocol. Two-year data on marginal bone loss and clinical parameters, including clinical attachment level, Plaque Index (PI), and bleeding on probing (BoP) have been previously reported.[15]

Method and materials

This randomized, prospective, clinical trial was approved by the institutional review board of the University of Naples (Italy) (protocol #7413). All patients considered for inclusion in the study were examined between January 2008 and December 2012 in dental clinics located in Italy; all clinics had extensive experience in implant treatment of patients. Treatments were performed in accordance with the Helsinki Declaration. All patients were informed that two different implants were used and gave their informed consent to the treatment. The study group included 78 implants that were placed in 77 patients (36 men and 41 women; mean age: 49.3 years; range: 45–65 years) referred for implant therapy, who required single-tooth rehabilitation in the middle to anterior area of the maxilla and the middle to anterior area of the mandible. Patients were recruited and treated by three different clinicians/centers, using similar and standardized procedures. One clinician/center was supposed to treat 27 patients, and two clinicians/centers 25 patients each. The implant sites were randomly allocated to one of the treatment groups. In the control group, BioHorizons tapered internal non–Laser-Lok-type (NLL; n = 39) implants were used, and in the test group BioHorizons tapered internal Laser-Lok–type (LL; n= 39) implants were used. A randomization protocol was produced from a computer-generated list for the assignment of subjects to the two treatment groups. Minimization was used for the age variables (≤ 30 years, 31–60 years, and > 60 years). The preoperative assessments included clinical and radiographic examinations using intraoral radiographs and sometimes panoramic radiographs and/or computed tomography scans. Patients were selected for this study according to the following criteria: *(1)* no contraindications for treatment, such as systemic diseases (eg, diabetes), pregnancy, regular use of prescription medications, or consumption of recreational drugs; *(2)* single tooth loss with neighboring teeth in normal occlusion; recipient sites for implants that had healed for > 3 months after tooth extraction; *(3)* teeth adjacent to the implant area (mesially and distally) had to be present and free of overhanging or insufficient restoration margins and/or caries (restorations and carious lesions were repaired during the initial professional oral hygienic therapy); *(4)* adequate bone of at least 9 mm length and 3.8 mm width; and *(5)* minimal peak insertion torque of 35 Ncm. Bruxism, the presence of a "deep bite" in the superior central incisors, and periodontal disease were considered only as risk factors. Patients with periodontitis were treated before implant surgery.

The exclusion criteria were *(1)* noncompensated diseases; *(2)* poor oral hygiene; and *(3)* smoking > 10 cigarettes a day. Patients received detailed information on the two kinds of implant (described later herein) and a full description of the surgical procedures and possible risks of immediate loading.

For every patient, diagnostic casts were made and mounted on a semiadjustable articulator using a face-bow and a bite registration. Occlusal analysis was performed, diagnostic wax-ups were prepared on the articulated casts, and restorative treatment needs were determined. Demographic data, medical and dental health history, and smoking status were obtained by questionnaire. Periodontal status was determined by a comprehensive periodontal examination. All patients demonstrated good oral hygiene and compliance (mean ± standard deviation PD, 1.8 ± 0.7 mm; BoP, 4%; PI, 6%].

© 2015 BY QUINTESSENCE PUBLISHING CO, INC. PRINTING OF THIS DOCUMENT IS RESTRICTED TO PERSONAL USE ONLY.
NO PART MAY BE REPRODUCED OR TRANSMITTED IN ANY FORM WITHOUT WRITTEN PERMISSION FROM THE PUBLISHER.

Implants

The two different implants used—LL and NLL—had the same design and the same surfaces treated with resorbable blast media (roughness between 0.72 and 1.34 mm), with the exception that LL had a dual bioaffinity collar with an implant neck consisting of two types of microgrooves. The LL implant neck is composed of a 0.3-mm turned surface, 0.7-mm microgrooves with an 8-μm pitch, and 0.8-mm microgrooves with a 12-μm pitch.

Surgery

All implants were placed in healed sites at least 3 months after tooth removal, allowing the extraction site to heal. Implant sites were primarily free from clinical signs of inflammation. Implants were placed using a one-stage surgical approach. Surgical access was carried out with a full-thickness flap at the level of keratinized mucosa with a minimally extended release incision to expose the crest and the vestibular limit of the bone. The site was prepared, and the implant was placed in its final position with a torque driver (Precise Adjustable Torque Wrench, BioHorizons). Inclusion criterion was a final torque of at least 35 Ncm. No patient was dropped from the study because of lack of final torque. The receiving sites were prepared with cylindrical burs of increasing diameter, according to the recommendations of the manufacturer. Bone quality and quantity were assessed according to the Lekholm and Zarb criteria.[16] In the presence of soft bone (type 3 to 4), an underpreparation technique was performed using a specific thinner bur.

Implant loading

After complete positioning of the implants, sterile impression transfers were connected and the flaps were sutured where needed. Impressions were taken with an open tray using Impregum NF (ESPE), and the jaw relationship was recorded. Temporary acrylic crowns were fabricated the same day and cemented with temporary cement (Temp Bond, Kerr). Fixed final prostheses of porcelain casted on golden alloy or zirconia were made after 4 to 6 months (66 after 4 months, 5 after 5 months, and 7 after 6 months).

Medication and postoperative care

Patients scheduled for surgery were prescribed an analgesic (ibuprofen, 600 mg, immediately after the surgical intervention and after 8 hours), a systemic antibiotic (amoxicillin/clavulanic acid, 1 g, twice a day for 7 days), and a chlorhexidine digluconate solution 0.12% rinse (twice daily for 1 minute). Sutures were left in place for 10 days. During the healing period, patients received oral hygiene instructions and debridement, if necessary, at monthly appointments with the dental hygienist. At the time of definitive crown placement, patients were enrolled in a maintenance program consisting of semiannual follow-up appointments.

Outcome measures

The primary outcome measures of this study were implant survival, radiographic marginal bone level changes, amount of plaque using the modified PI, BoP using the modified sulcus bleeding index, volume of the interproximal papilla using the papilla index, width of attached mucosa using the "attached mucosa index," pocket PD measured to the nearest 1 mm using a manual periodontal probe (CP 12, Hu-Friedy), and esthetics using the pink esthetic score (PES).[17] Both the implant and the adjacent teeth were analyzed.

Radiographic examination

For every patient, periapical radiographs (Ultra-speedA, Eastman Kodak) by means of a 65-kV dental radiographic unit equipped with a long cone (Oralix 65 S, Gendex Dental Systems) were exposed at implant surgery and temporary crown placement, and after 1 (T_1), 2 (T_2), and 3 (T_3) years. For the radiographic procedures, a silicone index material was fixated to the upper dentition and a radiograph holder was constructed for each patient. The radiographs were then digitized using a dedicated scanner (HP 3000) with a resolution of 2,048 × 3,072 lines and converted into .jpg files. A software package (AutoCAD 2000) was used to calibrate the image at

© 2015 BY QUINTESSENCE PUBLISHING CO, INC. PRINTING OF THIS DOCUMENT IS RESTRICTED TO PERSONAL USE ONLY.
NO PART MAY BE REPRODUCED OR TRANSMITTED IN ANY FORM WITHOUT WRITTEN PERMISSION FROM THE PUBLISHER.

a 1:1 ratio, referring to the implant length and diameter, and to take measurements. The distance from the connection of the implants to the first bone to implant contact was measured parallel to the major axis of the fixture. The delta between the measured length at T_3 and the baseline length defines the marginal bone loss as an average between the two sides of the implant.

Success rating

Criteria for success were applied according to Albrektsson and colleagues.[18] Failure was defined as implant removal for any reason.

Esthetic assessments

The esthetic outcomes of the peri-implant mucosa were objectively rated by a blinded clinician who had not been involved in the treatment using digital photographs (FinePix S3 Pro camera, Fujifilm) to determine the PES.[17] Digital photographs were taken at baseline and T_3. For calibration of the photographs, a calibrated probe was held in close contact and parallel to the long axis of a tooth adjacent to the implant. Full-screen analysis of the photographs was performed using Adobe Photoshop (Adobe Photoshop CS3 Extended, Adobe Systems). To assess the reliability of the photographic examination, 20 photographs (10 from each study group) were randomly selected and measured by the examiner twice with a 2-week interval. The intraobserver agreement of the photographic examination was tested earlier and reported as good, with a mean difference of 0.11 ± 0.02 mm between both times of measurements.

Data analysis

For between-group comparisons of numeric and normally distributed variables (assessed using the Kolmogorov-Smirnov test), *t* tests were used. Variables that were not normally distributed were statistically explored using the Mann-Whitney test. The Friedman test was applied for several within-group comparisons and Wilcoxon signed-rank test to compare two dependent conditions. Categorical variables were statistically explored with the chi-square test or the Fisher exact test. In all analyses, a significance level of .05 was chosen. Data were analyzed using SPSS software version 16.0 (SPSS).

Results

The present study describes the longitudinal observation of 78 implants divided into two groups: 39 LL implants in the test group and 39 NLL in the control group. Among the patients, 42 implants were placed in the maxilla (22 LL and 20 NLL), and 36 implants were placed in the mandible (17 LL and 19 NLL). Two implants (3.9% of all implants placed) were lost and not included in the final study group. The implant failures presented with a sudden onset of pain, suppuration of exudates, and mobility. The two implant groups showed no difference in implant failures (LL: 3.9% vs NLL: 3.9%; $P > .05$, chi-square test). The variables of sex, age, smoking, jaw, and position showed no significant influence on implant removal ($P > .05$; chi-square test).

Clinical and esthetic outcome

The implants lost in the NLL group (5 weeks after placement) and in the LL group (3 weeks after placement) were not included in the final radiographic and clinical data analyses. In Figs 1 and 2 are reported the frequency distribution of papilla and bleeding index at the 3-year follow-up. Table 1 summarizes the radiographic and clinical outcomes.

At the 3-year follow-up (T_3), the level of the midfacial peri-implant mucosa remained stable in both study groups without statistical differences (0.08 ± 0.42 mm for the LL group vs 0.06 ± 0.36 mm for the NLL group) ($P > .05$), and a mean gain in papilla level of 0.41 ± 0.34 mm and 0.17 ± 0.36 mm was observed in the LL and the NLL group, respectively (Table 1). The mean papilla level in the NLL group was significantly lower compared with the mean level in the LL group ($P < .05$). The clinical assessments also yielded significant differences between both the groups for pocket PD and papillae index but no significant differences were found between the study groups regarding PI, bleeding index, and width of attached mucosa. At T_3, a PI score of 1 was assigned to six implants in the LL study groups and to seven

© 2015 BY QUINTESSENCE PUBLISHING CO, INC. PRINTING OF THIS DOCUMENT IS RESTRICTED TO PERSONAL USE ONLY.
NO PART MAY BE REPRODUCED OR TRANSMITTED IN ANY FORM WITHOUT WRITTEN PERMISSION FROM THE PUBLISHER.

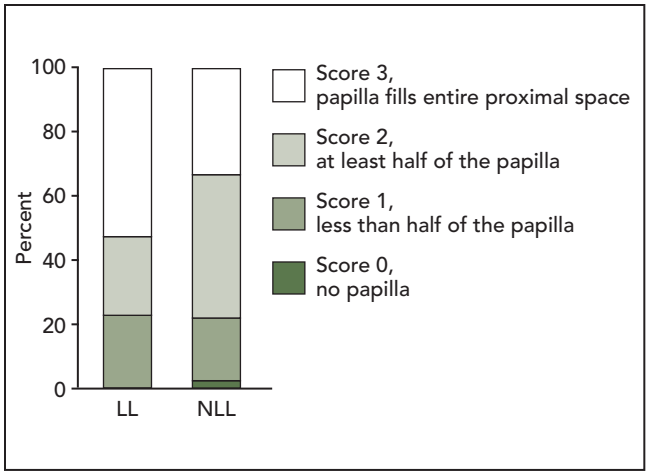

Fig 1 *Frequency distribution of Papilla Index scores at 3 years. LL = Laser-Lok; NLL= no Laser-Lok.*

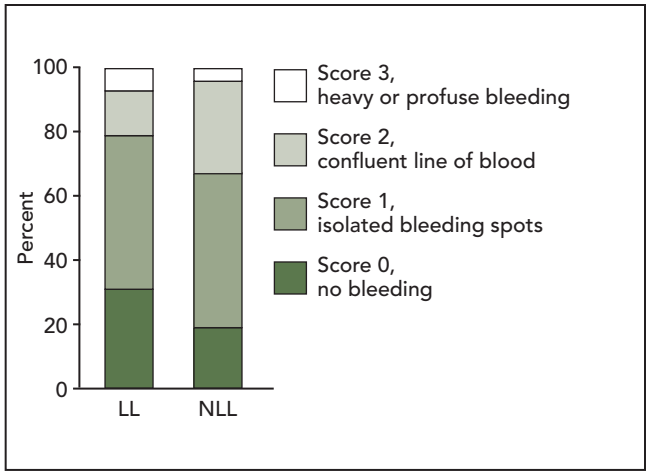

Fig 2 *Frequency distribution of Bleeding Index scores at 3 years. LL = Laser-Lok; NLL = no Laser-Lok.*

implants in the NLL group. The remaining implants did not show any plaque. Within-group analysis revealed lower plaque scores for the adjacent teeth at T_3 compared with preoperative values ($P < .05$). The height of the keratinized epithelium around implants in both groups was > 2 mm, with no statistically significant differences. Mean PESs were 11.72 ± 0.48 for the LL group and 11.2 ± 0.57 for the NLL group. Figs 3 and 4 show two examples of soft tissue dynamics recorded for LL and NLL implants. Tables 2 and 3 report the pink esthetic score values.

Marginal bone level change

The mean marginal bone loss (mesial and distal implant sides combined) from implant placement (baseline) to T_3 was 1.24 ± 0.28 mm in the NLL group and 0.65 ± 0.22 mm in the LL group. Results showed a statistically significant correlation between two groups ($P < .05$) (Table 1). Figs 5 and 6 show two examples of marginal bone remodeling recorded for LL and NLL implants.

Table 1 Changes in the marginal bone level and marginal soft tissue level at implant and tooth sides from baseline to 3 years*

	LL†	NLL†	*P*
Marginal bone-level changes (mm)			
Mesial side of implant	–0.61 ± 0.34	–1.24 ± 0.35	< .05
Distal side of implant	–0.70 ± 0.11	–1.38 ± 0.26	< .05
Mesial side of tooth	–0.22 ± 0.31	–0.26 ± 0.22	> .05
Distal side of tooth	–0.24 ± 0.15	–0.18 ± 0.14	> .05
Marginal soft tissue-level changes (mm)			
Distal side of implant papilla	0.48 ± 0.17	0.13 ± 0.24	< .05
Mesial side of implant papilla	0.35 ± 0.52	0.22 ± 0.49	< .05
Midfacial side of implant	0.08 ± 0.42	0.06 ± 0.36	> .05
Mesial side of tooth	–0.24 ± 021	–0.31 ± 0.23	> .05
Distal side of tooth	–0.28 ± 0.39	–0.27 ± 0.40	> .05
Probing pocket depth (mm)			
Mesial side of implant	0.56 ± 0.33	1.80 ± 0.30	< .05
Distal side of implant	0.61 ± 0.29	1.98 ± 0.41	< .05
Midfacial side of implant	0.48 ± 0.32	1.73 ± 0.54	< .05
Proximal side of teeth‡	0.84 ± 0.37	1.81 ± 0.18	< .05
Midfacial side of teeth	0.91 ± 0.44	1.93 ± 0.33	< .05

*At implant placement for bone levels, at temporary crown placement for gingival levels, and at definitive crown placement for pocket depths.
†Data are means ± standard deviations.
‡Mesial and distal sides combined.

© 2015 BY QUINTESSENCE PUBLISHING CO, INC. PRINTING OF THIS DOCUMENT IS RESTRICTED TO PERSONAL USE ONLY.
NO PART MAY BE REPRODUCED OR TRANSMITTED IN ANY FORM WITHOUT WRITTEN PERMISSION FROM THE PUBLISHER.



Fig 3 *Example of soft tissue dynamics recorded around an LL implant during the study period.* (a) *Baseline (at temporary crown placement);* (b) *1-year follow-up;* (c) *2-year follow-up;* (d) *3-year follow-up.*



Fig 4 *Example of soft tissue dynamics recorded around an NLL implant during the study period.* (a) *Baseline (at temporary crown placement);* (b) *1-year follow-up;* (c) *2-year follow-up;* (d) *3-year follow-up.*

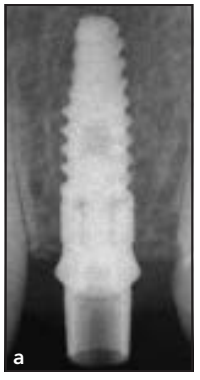



Fig 5 *Example of marginal bone remodeling recorded around LL during the study period.* (a) *Baseline (at implant placement);* (b) *3-years follow-up.*



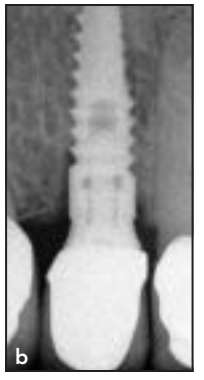

Fig 6 *Example of marginal bone remodeling recorded around NLL during the study period.* (a) *Baseline (at implant placement);* (b) *3-year follow-up.*

© 2015 BY QUINTESSENCE PUBLISHING CO, INC. PRINTING OF THIS DOCUMENT IS RESTRICTED TO PERSONAL USE ONLY.
NO PART MAY BE REPRODUCED OR TRANSMITTED IN ANY FORM WITHOUT WRITTEN PERMISSION FROM THE PUBLISHER.

Fig 7 (left) *Scanning electron microscopic image of laser-microtextured implant collar surface.*

Fig 8 (right) *Scanning electron microscopic image of resorbable blast textured implant collar surface.*





Table 2 **Summarized pink esthetic scores of the implants included in relation to baseline* recorded at 3-year follow-up**

	LL			NLL		
Groups	**Value 0**	**Value 1**	**Value 2**	**Value 0**	**Value 1**	**Value 2**
Mesial papilla	1	7	31	3	7	29
Distal papilla	1	9	29	4	9	26
Midfacial mucosa level	2	9	28	2	10	27
Midfacial contour	1	12	26	1	12	26
Alveolar process deficiency	3	6	30	3	6	30
Soft tissue color	1	6	32	2	5	32
Soft tissue texture	2	6	31	2	7	30

*at the temporary crowns placement.
LL = Laser-Lok; NLL = no Laser-Lok.

Table 3 **Pink esthetic score**

	Mesial papilla		Distal papilla		Midfacial mucosa level		Midfacial contour		Alveolar process deficiency		Soft tissue color		Soft tissue texture		Total score (maximum 14)	
	LL	**NLL**	**LL**	**NLL**	**LL**	**NLL**	**LL**	**NLL**	**LL**	**NLL**	**LL**	**NLL**	**LL**	**NLL**	**LL**	**NLL**
Maximum	2		2		2		2		2		2		2		14	
Minimum	0		0		0		0		0		0		0		6	
Mean	1.69	1.46	1.59	1.48	1.66	1.64	1.64	1.60	1.69	1.67	1.74	1.69	1.71	1.66	11.72	11.20
SD	0.52	0.61	0.51	0.62	0.66	0.57	0.53	0.53	0.60	0.60	0.54	0.56	0.55	0.56	0.48	0.57
Significance	$P < .05$		$P < .05$		$P > .05$		$P > .05$		$P > .05$		$P > .05$		$P > .05$		$P > .05$	

LL = Laser-Lok; NLL = no Laser-Lok; SD = standard deviation.

Discussion

Studies on immediate loading often rely on implant survival rates. However, in the anterior zone, the success of implant therapy is also determined by the long-term quality of survival, which is dictated by a mixture of several factors, including esthetics. One factor affecting the long-term quality of survival is the level of peri-implant marginal bone loss. This is because peri-implant bone loss may induce pocket formation and could be unfavorable

© 2015 BY QUINTESSENCE PUBLISHING CO, INC. PRINTING OF THIS DOCUMENT IS RESTRICTED TO PERSONAL USE ONLY.
NO PART MAY BE REPRODUCED OR TRANSMITTED IN ANY FORM WITHOUT WRITTEN PERMISSION FROM THE PUBLISHER.

for the long-term health of the peri-implant tissues.[19] In the present study, radiographic measurements at the mesial and distal sites revealed statistically significant differences in marginal bone loss around the LL implants and the NLL implants (0.61 ± 0.34 mm vs 1.24 ± 0.35 mm on the mesial side, and 0.70 ± 0.11 mm vs 1.38 ± 0.26 mm on the distal side). Radiographic results of this study are aligned with those of previous studies that compared implants with a laser microtextured collar with those receiving another surface treatment.[10–15]

The influence of the implant collar surface on marginal bone loss around implants has been discussed only recently, and has received little attention compared with other factors.[20,21] Several studies proposed that bone retention elements such as microthread and microgrooves at the implant neck might help to stabilize the marginal bone.[21–25] These studies suggested that the retention elements would counteract marginal bone resorption.

Using a three-dimensional mathematical model and axisymmetric finite element analysis to determine the ideal rough surface, Hansson[22] hypothesized that the surface roughness or the retentive elements could increase the resistance of marginal bone to bone loss with the interlocking force between the implant surface and the crestal bone. In that study, the author showed that when an axial load is applied to an implant, the peak interfacial shear stress in the marginal bone can be reduced by providing retention elements all the way up to the crest of the implant.

Retention elements on the implant collar can be created with the addition of machine-tooled microthreads or laser-ablated microgrooves. Unlike machine-tooled microthreads, laser microgrooves are smaller in dimension by an order of magnitude. Moreover, the nanotopography of laser microgrooves is more pronounced, having knobs with rounded edges and some undercuts (Fig 7), while blasted surfaces (Fig 8) on machine-tooled microthreads show random nanoroughness and somewhat sharp edges.

However, the influence of surface geometry and structure on bone-to-implant interface against the marginal bone resorption around the implant neck or cervical area may be explained by many other factors. One of these is represented by the significant effect of the mechanical substrate supporting biologic tissue and its nanofeatures on cell growth, development, behavior, and the strength of adhesion through filopodial sensing.[26–28] Some in vitro studies[29,30] evaluating the effect of surface microgeometry with regard to attachment, spreading, orientation, and growth of fibroblasts reported that cultured fibroblasts grown on microgrooved surfaces become oriented and channeled in line with the grooves, whereas cells grown on nongrooved surfaces showed random growth. Furthermore, laser-ablated microgrooves promote oriented cell filipodial contact and fibrin fibril orientation.[31] These in vitro results have provided the hypothesis that laser-microtextured surfaces could be used to control soft tissue responses to implant surfaces. It has in fact been suggested that on dental collar implants, the laser microtextured surface might act to establish a predetermined site to attract a physical connective tissue attachment. Histologic research in an animal model[32–34] and in humans[35–37] has subsequently confirmed this hypothesis, documenting the presence of a physical connective tissue attachment onto laser-produced microgrooves on implant and abutment surfaces. The most important aspects of this physical connective tissue attachment may be the fact that its position is determined by the layout of the laser microgrooves, with the connective tissue fibers perpendicularly oriented to the implant surface; these fibers act as a seal to apical migration of gingival epithelial cells and fibroblasts.

Based on these data, one might speculate that repetitive nanosize surface features created with a laser on the implant collar have the ability to allow fibroblasts to form a physical connective tissue attachment. As is the case around natural teeth, in which collagen bundles inserted into the root cementum deter the downgrowth migration of the overlying epithelium, epithelial downgrowth around implants could be impeded by firm physical attachment between the soft connective tissue and the implant. The laser-microtextured surface, although not analogous to the cemental surface of the natural teeth, seems to act in establishing a predetermined site to attract a physical connective tissue attachment, to restrict apical migration of gingival

© 2015 BY QUINTESSENCE PUBLISHING CO, INC. PRINTING OF THIS DOCUMENT IS RESTRICTED TO PERSONAL USE ONLY.
NO PART MAY BE REPRODUCED OR TRANSMITTED IN ANY FORM WITHOUT WRITTEN PERMISSION FROM THE PUBLISHER.

epithelium, and thus to preserve the coronal level of bone. In light of the significant influence that the laser-microtextured collar surface has on marginal bone loss, it would be reasonable to assume that this kind of surface may provide greater soft tissue support to the implant.

It has been suggested that the level of the peri-implant marginal bone determines the level of the peri-implant mucosa.[38,39] Furthermore, marginal bone loss may induce pocket formation, which could be unfavorable for the long-term health of the peri-implant tissues.[40,41] In the present study, the mean PD values in the LL group and the NLL group were 0.58 ± 0.2 mm and 1.89 ± 0.3 mm, respectively, while the volume of the papillae, expressed in papilla index scores, increased significantly during follow-up in the LL group compared with the NLL group (a score of 3 was found in 52% of the LL group vs 33% of the NLL group). These results are in agreement with published data reporting a consistent difference in PD and peri-implant mucosal recession between the implant pairs with and without the laser microtexturing treatment.[11,13,15]

The fact that implants with a laser-microtextured collar yield minimal bone loss could be an explanation for the peri-implant tissue results observed in the present study. As is the case around the teeth, epithelium seems to play an important role in implant function by sealing dental implants from contaminants in the external environment.[42] Around implants, epithelial downgrowth could be impeded by firm attachment of the connective tissue to the implant, with cells and fibers attached to the implant surface, as is the case with Sharpey fibers around natural teeth. In the case of a dental implant, smooth collars do not permit connective tissue attachment, hence stability of the peri-implant soft tissue is lacking.[43]

Because it is known that the proximal bone level next to the adjacent teeth is highly relevant for the level of the proximal papillae of the implant,[43–46] in the present study these bone levels were also taken into consideration as an important predictor of the esthetic outcome. In both study groups, only a small amount of bone loss at the adjacent teeth was noticed during follow-up. The LL group showed a higher gain of the papillae than the NLL group, so it might be reasonable to assume that the Laser-Lok surface may provide higher soft tissue support to the implant. However, it should be recognized that single tooth replacement implant therapy is not without consequences for the midfacial level of the adjacent teeth, showing a recession of about 0.25 mm in both groups. When using the PES as an instrument to express soft-tissue esthetics, no significant differences between LL and NLL implants were observed in overall results, even if a statistically significant lower value of the distal and mesial implant papilla was observed in the NLL group compared with the LL group. The same applied to the volume of the papilla assessed with the papilla index.

Conclusions

Within the limitations related to sample size and follow-up duration, this prospective study demonstrated that:

- Immediate functional loading of implants in single-tooth replacement in the esthetic zone may be considered a valuable and predictable option.
- Immediate functional loading of a single implant in the maxillary esthetic zone leads to a short-term treatment outcome that is more favorable with LL implants than with NLL implants.

However, more prospective studies monitoring soft tissue dynamics over longer periods and with greater sample size are needed to establish if a laser-microtextured implant collar surface might preserve peri-implant hard and soft tissue when using an immediate provisionalization protocol.

Acknowledgments

The authors reported no conflict of interests related to this study. Materials used in this study were funded by Classimplant SRL, Rome, Italy.

References

1. Jung RE, Pjetursson BE, Glauser R, Zembic A, Zwahlen M, Lang NP. A systematic review of the 5-year survival and complication rate of implant-supported single crowns. Clin Oral Implants Res 2008;19,119–130.

© 2015 BY QUINTESSENCE PUBLISHING CO, INC. PRINTING OF THIS DOCUMENT IS RESTRICTED TO PERSONAL USE ONLY.
NO PART MAY BE REPRODUCED OR TRANSMITTED IN ANY FORM WITHOUT WRITTEN PERMISSION FROM THE PUBLISHER.

2. Nkenke E, Fenner M. Indications for immediate loading of implants and implant success. Clin Oral Implants Res 2006;17:19–34.
3. den Hartog L, Huddleston Slater JJR, Vissink A, Meijer HJA, Raghoebar GM. Treatment outcome of immediate, early and conventional single-tooth implants in the aesthetic zone: A systematic review to survival, bone level, soft-tissue, aesthetics and patient satisfaction. J Clin Periodontol 2008;35:1073–1086.
4. Laney WR. Glossary of Oral and Maxillofacial Implants. Berlin: Quintessence, 2007.
5. Cochran DL, Morton D, Weber HP. Consensus statements and recommended clinical procedures regarding loading protocols for endosseous dental implants. Int J Oral Maxillofac Implants 2004;19(suppl):109–113.
6. Glauser R, Zembic A, Hammerle CH. A systematic review of marginal soft tissue at implants subjected to immediate loading or immediate restoration. Clin Oral Implants Res 2006;17 (suppl 2):82–92.
7. van Kesteren CJ, Schoolfield J, West J, Oates T. A prospective randomized clinical study of changes in soft tissue position following immediate and delayed implant placement. Int J Oral Maxillofac Implants 2010;25:562–570.
8. Raes F, Cosyn J, Crommelinck E, Coessens P, De Bruyn H. Immediate and conventional single implant treatment in the anterior maxilla: One-year results of a case series on hard and soft tissue remodeling and aesthetics. J Clin Periodontol 2011;38:385–394.
9. den Hartog L, Raghoebar GM, Stellingsma K, Vissink A, Meijer HJA. Immediate nonocclusal loading of single implants in the aesthetic zone: A randomized clinical trial. J Clin Periodontol 2011;38:186–194.
10. Shapoff CA, Lahey B, Wasserlauf PA, Kim DM. Radiographic analysis of crestal bone levels around Laser-Lok collar dental implants. Int J Periodontics Restorative Dent 2010;30:129–137.
11. Pecora GE, Ceccarelli R, Bonelli M, Alexander H, Ricci JL. Clinical evaluation of laser microtexturing for soft tissue and bone attachment to dental implants. Implant Dent 2009;18:57–66.
12. Botos S, Yousef H, Zweig B, Flinton R, Weiner S. The effect of laser microtexturing of the dental implant collar on crestal bone levels and peri-implant health. Int J Oral Maxillofac Implants 2011;26: 492–498.
13. Guarnieri R, Serra M, Bava L, Farronato D, Iorio Siciliano V, Grande M. The impact of laser microtexturing collar designs on crestal bone level, and clinical parameters under various placement and loading protocols. Int J Oral Maxillofac Implants 2014;29:354–63.
14. Guarnieri R, Placella R, Testarelli L, Iorio-Siciliano V, Grande M. Clinical, radiographic, and esthetic evaluation of immediately loaded laser microtextured implants placed into fresh extraction sockets in the anterior maxilla: A 2-year retrospective multicentric study. Implant Dent 2014;23:144–154.
15. Farronato D, Mangano F, Briguglio F, Iorio-Siciliano V, Riccitiello F, Guarnieri R. Influence of Laser-Lok surface on immediate functional loading of implants in single-tooth replacement: A 2-year prospective clinical study. Int J Periodontics Restorative Dent 2014;34:79–89.
16. Lekholm U, Zarb GA. Patient selection. In: Brånemark P-I, Zarb GA, Albrektsson T (eds). Tissue-Integrated Prostheses: Osseointegration in Clinical Dentistry. Chicago: Quintessence, 1985:199–209.
17. Belser UC, Grutter L, Vailati F, Bornstein MM, Weber HP, Buser D. Outcome evaluation of early placed maxillary anterior single-tooth implants using objective esthetic criteria: A cross-sectional, retrospective study in 45 patients with a 2- to 4-year follow-up using pink and white esthetic scores. J Periodontol 2009;80: 140–151.
18. Albrektsson T, Hansson T, Lekholm U. Osseointegrated dental implants. Dent Clin North Am 1986;30:151–174.
19. Heydenrijk K, Meijer HJ, van der Reijden WA, Raghoebar GM, Vissink A, Stegenga B. Microbiota around root-form endosseous implants: A review of the literature. Int J Oral Maxillofac Implants 2002;17:829–838.
20. Bateli M, Att W, Strub JR. Implant neck configurations for preservation of marginal bone level: A systematic review. Int J Oral Maxillofac Implants. 2011;26: 290–303.
21. Ketabi M, Deporter D. The effects of laser microgrooves on hard and soft tissue attachment to implant collar surfaces: A literature review and interpretation. Int J Periodontics Restorative Dent 2013;33:e145–e152.
22. Hansson S. The implant neck: Smooth or provided with retention elements. A biomechanical approach. Clin Oral Implants Res 1999;10:394–405.
23. Shin YK, Han CH, Heo SJ, Kim SJ, Chun HJ. Radiographic evaluation of marginal bone level around implants with different neck designs after 1 year. Int J Oral Maxillofac Implants 2006;21:789–794.
24. Lee DW, Choi YS, Park KH, Kim CS, Moon IS. Effect of microthread on the maintenance of marginal bone level: A 3-year prospective study. Clin Oral Implants Res 2007;18:465–470.
25. Nickenig HJ, Wichmann M, Schlegel KA, Nkenke E, Eitner S. Radiographic evaluation of marginal bone levels adjacent to parallel-screw cylinder machined-neck implants and rough-surfaced microthreaded implants using digitized panoramic radiographs. Clin Oral Implants Res 2009;20:550–554.
26. Brunette DM. The effect of implant surface topography on the behavior of cells. Int J Oral Maxillofac Implants 1998; 3:231–246.
27. Dalby MJ, Riehle MO, Johnstone H, Affrossman S, Curtis AS. Investigating the limits of filopodial sensing: A brief report using SEM to image the interaction between 10 nm high nano-topography and fibroblast filopodia. Cell Biol Int 2004; 28:229–236.
28. Wang RC, Hsieh MC, Lee TM. Effects of nanometric roughness on surface properties and fibroblast's initial cytocompatibilities of Ti6Al4V. Biointerphases 2011;6:87.
29. Ricci JL, Grew JC, Alexander H. Connective-tissue responses to defined biomaterial surfaces. I. Growth of rat fibroblast and bone marrow cell colonies on microgrooved substrates. J Biomed Mater Res A 2008;85:313–325.
30. Grew JC, Ricci JL, Alexander H. Connective-tissue responses to defined biomaterial surfaces. II. Behavior of rat and mouse fibroblasts cultured on microgrooved substrates. J Biomed Mater Res A 2008;85:326–335.
31. Dumas V, Rattner A, Vico L, et al. Multiscale grooved titanium processed with femtosecond laser influences mesenchymal stem cell morphology, adhesion, and matrix organization. J Biomed Mater Res A 2012;100:3108–3116. doi: 10.1002/jbm.a.34239.
32. Nevins M, Kim DM, Jun SH, Guze K, Schupbach P, Nevins ML. Histologic evidence of a connective tissue attachment to laser microgrooved abutments: A canine study. Int J Periodontics Restorative Dent 2010;30:245–255.

© 2015 BY QUINTESSENCE PUBLISHING CO, INC. PRINTING OF THIS DOCUMENT IS RESTRICTED TO PERSONAL USE ONLY.
NO PART MAY BE REPRODUCED OR TRANSMITTED IN ANY FORM WITHOUT WRITTEN PERMISSION FROM THE PUBLISHER.

33. Shin SY, Han DH. Influence of micro-grooved collar design on soft and hard tissue healing of immediate implantation in fresh extraction sites in dogs. Clin Oral Impl Res 2010;21:804–814.
34. Iglhaut G, Becker K, Golubovic V, Schliephake H, Mihatovic I. The impact of dis-/reconnection of laser microgrooved and machined implant abutments on soft- and hard-tissue healing. Clin Oral Impl Res 2013;24:391–397.
35. Nevins M, Nevins ML, Camelo M, Boyesen JL, Kim DM. Human histologic evidence of a connective tissue attachment to a dental implant. Int J Periodontics Restorative Dent 2008;28:111–121.
36. Nevins M, Camelo M, Nevins ML, Schupbach P, Kim DM. Reattachment of connective tissue fibers to a laser-microgrooved abutment surface. Int J Periodontics Restorative Dent 2012; 32:e131–e134.
37. Geurs NC, Vassilopoulos PJ, Reddy MS. Histologic Evidence of Connective Tissue Integration on Laser Microgrooved Abutments in Humans. Clin Adv Periodontics 2011;1:29–33.
38. Bengazi F, Wennström JL, Lekholm U. Recession of the soft tissue margin at oral implants. A 2-year longitudinal prospective study. Clin Oral Implants Res 1996;7:303–310.
39. Chang M, Wennström JL, Odman P, Andersson B. Implant supported single-tooth replacements compared to contralateral natural teeth. Crown and soft tissue dimensions. Clin Oral Implants Res 1999;10:185–194.
40. Hermann JS, Buser D, Schenk RK, Schoolfield JD, Cochran DL. Biologic width around one- and two-piece titanium implants. Clin Oral Implants Res 2001; 12:559–571.
41. Rams TE, Roberts TW, Tatum H Jr, Keyes PH. The subgingival microbial flora associated with human dental implant. J Prosthet Dent 1984;51:529–534.
42. Listgarten MA, Lang NP, Schroeder HE, Schroeder A. Periodontal tissues and their counterparts around endosseous implants. Clin Oral Implants Res 1991;2:1–19.
43. Cochran DL, Hermann JS, Schenk RK, Higginbottom FL, Buser D. Biologic width around titanium implants. A histometric analysis of the implanto-gingival junction around unloaded and loaded nonsubmerged implants in the canine mandible. J Periodontol 1997;68: 186–198.
44. Choquet V, Hermans M, Adriaenssens P, Daelemans P, Tarnow DP, Malevez C. Clinical and radiographic evaluation of the papilla level adjacent to single-tooth dental implants. A retrospective study in the maxillary anterior region. J Periodontol 2001;72:1364–1371.
45. Kan JY, Rungcharassaeng K, Umezu K, Kois JC. Dimensions of peri-implant mucosa: An evaluation of maxillary anterior single implants in humans. J Periodontol 2003;74,557–562.
46. Block MS, Mercante DE, Lirette D, Mohamed W, Ryser M, Castellon P. Prospective evaluation of immediate and delayed provisional single tooth restorations. J Oral Maxillofac Surg 2009;67: 89–107.

© 2015 BY QUINTESSENCE PUBLISHING CO, INC. PRINTING OF THIS DOCUMENT IS RESTRICTED TO PERSONAL USE ONLY.
NO PART MAY BE REPRODUCED OR TRANSMITTED IN ANY FORM WITHOUT WRITTEN PERMISSION FROM THE PUBLISHER.