

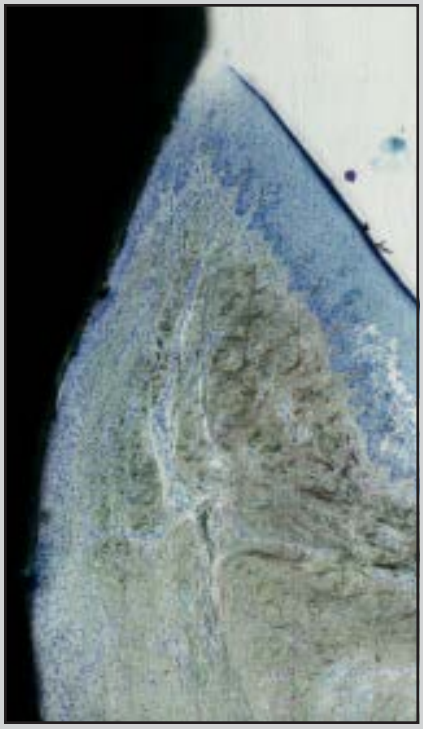

© 2016 BY QUINTESSENCE PUBLISHING CO, INC. PRINTING OF THIS DOCUMENT IS RESTRICTED TO PERSONAL USE ONLY.
NO PART MAY BE REPRODUCED OR TRANSMITTED IN ANY FORM WITHOUT WRITTEN PERMISSION FROM THE PUBLISHER.

The Effect of Laser-Etched Surface Design on Soft Tissue Healing of Two Different Implant Abutment Systems: An Experimental Study in Dogs



Rodrigo Neiva, DDS, MS[1]/Nick Tovar, PhD[2]
Ryo Jimbo, DDS, PhD[3]/Luiz F. Gil, DDS, MS[4]
Paula Goldberg, BS[2]/Joao P.M. Barbosa, DDS[2]
Thomas Lilin, DVM[5]/Paulo G. Coelho, DDS, PhD[2]

This study describes the early soft tissue morphology around two different implant systems that received either smooth or laser-etched abutments in a beagle dog model. Implants were placed in the healed mandibular molar region of eight beagle dogs and allowed to heal for 7 weeks. When the most apical aspect of the junctional epithelium (JE) was above or within the upper half of the laser-etched region, fibers were oriented perpendicular to the abutment surface. In contrast, JE positioned within the lower half of the laser-etched region or within or below the implant-abutment gap level presented fibers oriented parallel to the abutment surface. Int J Periodontics Restorative Dent 2016;36:673–679. doi: 10.11607/prd.2940

[1]Department of Periodontology, University of Florida College of Dentistry, Gainesville, Florida, USA.
[2]Department of Biomaterials and Biomimetics, New York University College of Dentistry, New York, New York, USA.
[3]Department of Prothodontics, Malmö University, Malmö, Sweden.
[4]Department of Dentistry, Division of Oral and Maxillofacial Surgery, Federal University of Santa Catarina, Florianópolis, Santa Caterina, Brazil.
[5]École Nationale Vétérinaire D'Alfort, Maisons-Alfort, France.

Correspondence to: Dr Paulo G. Coelho, Associate Professor of Biomaterials and Biomimetics, 433 1st Ave Room 844, New York, NY 10010, USA.
Email: pgcoelho@nyu.edu

©2016 by Quintessence Publishing Co Inc.

Clinical application of osseointegrated metallic implants has become one of the most successful treatment modalities in dentistry. While success rates have been high, a demand still exists to further improve their performance and constant research has been conducted to meet this demand. Although many factors influence the success of the treatment, one of the major factors that significantly influences establishment and maintenance of the periimplant tissue is implant design.[1]

Implant design can be further classified according to length scales such as macro-, micro-, or nanolevels, and it has been suggested that the interplay between the different levels of implant geometries regulates osteogenesis.[1,2] A modification that has shown unique biologic response is laser etching of the implant surface.[3,4] For instance, when such length scale features were added to the coronal portion of the metallic implants, osseointegration was achieved regardless of the drilling procedures, suggesting high osteoconductivity.[5] In accordance with the aforementioned study, other laboratory in vivo and clinical retrieval studies concerning laser-etched abutment and implant surfaces have shown direct bone-to-implant contact with laser-etched surfaces.[6-8]

While studies have unequivocally demonstrated that laser etching

© 2016 BY QUINTESSENCE PUBLISHING CO, INC. PRINTING OF THIS DOCUMENT IS RESTRICTED TO PERSONAL USE ONLY.
NO PART MAY BE REPRODUCED OR TRANSMITTED IN ANY FORM WITHOUT WRITTEN PERMISSION FROM THE PUBLISHER.

is biocompatible and osteoconductive, the literature has also indicated that this length scale can be used for peri-implant soft tissue establishment and maintenance around implants relative to machined[9] or microscale textured surfaces.[10] Some studies even suggest that this feature may contribute to improvement of the soft tissue seal,[6–8] a lack of which has been regarded as a weakness of the peri-implant structure. The laser-etched surface has been shown to create apical soft tissue attachment and minimize crestal bone loss in preclinical studies,[6–8] and clinical evidence[11–14] has pointed out that such technology may assist in prevention of the onset of peri-implantitis.[8,15]

The unique soft tissue configuration obtained following placement of laser-etched implants (cervical region) was first histologically described by Nevins et al, who demonstrated that these surfaces guided cell migration and orientation, restricting apical migration of the junctional epithelium (JE).[8] When observed in greater detail, the establishment of connective tissue attachment in a perpendicular fashion to the surface was noted. This has not been the case around conventional transmucosal implant components.[8] Since the connective seal pattern ultimately influences the stability of the underlying marginal bone, the authors suggested that the modification could be of great clinical significance.[6–8] Clinical studies have validated the hypothesis through the assessment of reduced clinical attachment levels and crestal bone loss relative to controls or published data in clinical studies.[11–14]

While the published evidence strongly suggests that laser etching of both abutment and implant surfaces results in osseointegration and improved soft tissue sealing relative to standard smooth abutments, the current body of literature concerns devices fabricated by one manufacturer and investigations using different implant systems are warranted. The objective of the present study was to morphologically evaluate the early soft tissue healing around two different implant systems that bilaterally received standard smooth abutments and laser-etched abutments in a preclinical laboratory model.

Materials and Methods

Materials

For this study, two different implant systems were used (n = 16 implants each). The first implant type was Zimmer Tapered Screw-Vent Implants of 3.75-mm diameter and 11-mm length (Zimmer Dental), and the other was Nobel Tapered Groovy of 3.5-mm diameter and 11-mm length (Nobel Biocare). For each implant system, two different abutment types were evaluated: regular machined abutments and abutments with cervical Laser-Lok grooves. For the Zimmer implants, Zimmer Hex-Lok short abutments with a 2-mm cuff height (SA342 with SAHEAL4) (n = 8) were used in the control group and Laser-Lok 3.5-mm Simple Solutions Abutments with 4-mm chimney height and 1.8-mm margin (PY4018L, BioHorizons) were used in the experimental group. For the Nobel Biocare system, Snappy Abutments NP with a 4-mm chimney height and a 1.5-mm cuff height (36829) were the control abutments and Laser-Lok Simple Solutions Abutments with a 4 mm-chimney height and a 1.8-mm margin (NB-35966) were the experimental abutments.

Methods

Laboratory *In Vivo* model

For the laboratory in vivo model, eight adult male beagle dogs of approximately 1.5 years old were acquired after the approval of the Ethics Committee for Animal Research at École Nationale Vétérinaire D'Alfort. The animals were housed for a period of 2 weeks for acclimatization prior to surgical procedures. All surgical procedures were conducted under general anesthesia.

Prior to general anesthesia, intramuscular atropine sulfate (0.044 mg/kg) and xylazine chlorate (8 mg/kg) were administered. A 15-mg/kg dose of ketamine chlorate was then used to achieve general anesthesia, and anesthesia was maintained by 2% to 3% halothane.

Bilateral extractions of the mandibular molar were performed. Buccal and lingual full-thickness mucoperiosteal flaps were elevated, followed by sectioning of the teeth in a buccolingual direction to allow for nontraumatic individual root extractions by means of root elevators and extraction forceps. Approximation of the flaps was achieved through standard suturing techniques, and the extraction sites were allowed to heal for 8 weeks.

© 2016 BY QUINTESSENCE PUBLISHING CO, INC. PRINTING OF THIS DOCUMENT IS RESTRICTED TO PERSONAL USE ONLY.
NO PART MAY BE REPRODUCED OR TRANSMITTED IN ANY FORM WITHOUT WRITTEN PERMISSION FROM THE PUBLISHER.



Fig 1 (a) *Low-magnification histologic section of an implant and surrounding peri-implant tissues, and* (b) *higher magnification of a representative histologic section depicting the region of interest used for quantification.*

At the end of the healing period, one implant in each group was placed (following manufacturers' recommendations and standard osteotomy preparation) at the region of the mesial and distal socket location in a split-mouth design to allow direct comparison per location in the arch between implants presenting standard machined abutments and Laser-Lok abutments. To evaluate the two different abutment types in an equal distribution per site, the implant types were alternated through the mesial and distal sites resulting in a uniform distribution of implants per animal per site. Following implant placement, both Zimmer and Nobel Biocare implants received either standard machined or Laser-Lok abutments. Soft tissue approximation was performed using standard suturing procedures, and occlusion was adjusted with diamond burs to avoid contact with the upper teeth. No hygiene procedures were performed throughout the course of the study. The implants remained in vivo for 7 weeks prior to animal sacrifice.

After sacrifice, the arches were reduced to blocks containing the implants, surrounding bone, and soft tissue, and were immersed in 10% buffered formalin solution for 24 hours. The blocks were then washed in running water for 24 hours and gradually dehydrated in a series of alcohol solutions ranging from 70% to 100% ethanol. Following dehydration, the samples were embedded in a methacrylate-based resin. The blocks were cut into slices (~300 µm thick), aiming for the center of the implant along its long axis, with a precision diamond saw (IsoMet 2000, Buehler), and glued to acrylic plates with an acrylate-based cement. A 24-hour setting time was allowed prior to grinding and polishing. The sections were then reduced to a final thickness of ~30 µm by means of a series of SiC abrasive papers (400, 600, 800, 1200, and 2400, Buehler) in a grinding/polishing machine (MetaServ 3000, Buehler) under water irrigation. The sections were then stained with Stevenel blue and van Gieson picrofuchsin stains. The histologic samples were evaluated at ×50 to ×200 magnification (Leica DM2500 M, Leica Microsystems), and high-resolution micrographs were obtained through a digital scanner (Aperio, Leica Biosystems).

Soft tissue evaluation around the implant abutment regions was performed and quantified according to the position of the most apical component of the JE at both lingual and buccal flanges (Fig 1) as follows:

1. Most apical component of the JE cervical to the abutment Laser-Lok region (Fig 2a)
2. Most apical component of the JE positioned within the abutment Laser-Lok region (Fig 2b)
3. Most apical component of the JE positioned at or below the implant-abutment gap (Fig 2c)

For statistical analysis, positive and negative outcomes were computed. Outcomes were considered positive if the most apical position of the JE was observed cervical to or within the Laser-Lok region. An outcome was considered negative when the JE was positioned at or

© 2016 BY QUINTESSENCE PUBLISHING CO, INC. PRINTING OF THIS DOCUMENT IS RESTRICTED TO PERSONAL USE ONLY.
NO PART MAY BE REPRODUCED OR TRANSMITTED IN ANY FORM WITHOUT WRITTEN PERMISSION FROM THE PUBLISHER.

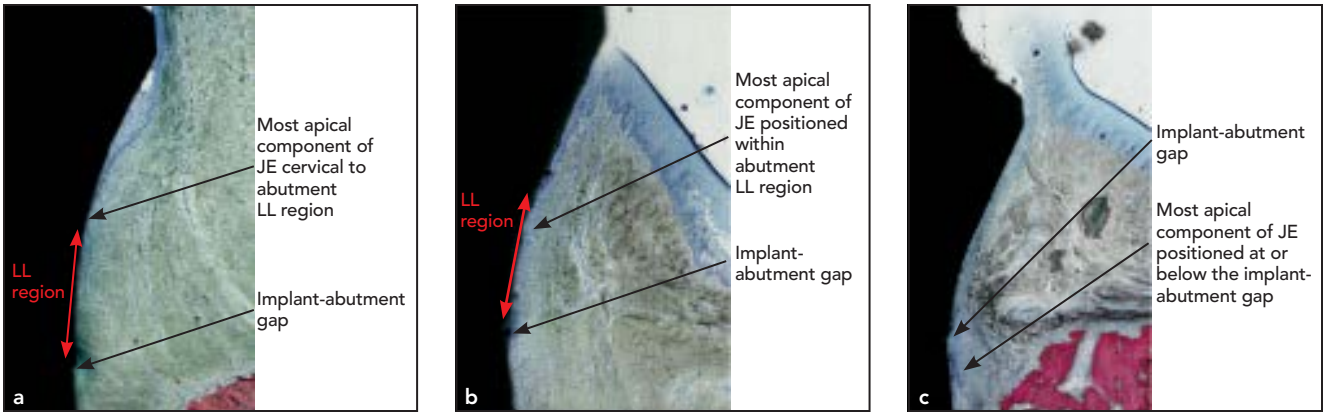

Fig 2 *Soft tissue evaluation around the implant/abutment regions was performed and quantified according to the position of the most apical component of the junctional epithelium at both lingual and buccal flanges.* (a) *Most apical component of JE cervical to the abutment Laser-Lock region.* (b) *Most apical component of the JE positioned within the abutment Laser-Lok region.* (c) *Most apical component of JE positioned at or below the implant-abutment gap. JE = junctional epithelium; LL = Laser-Lok.*

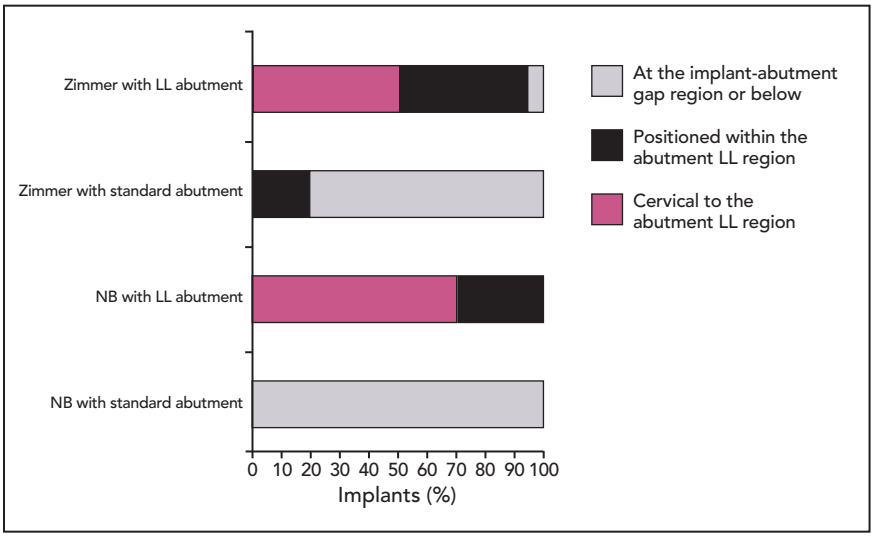

Fig 3 *Summary histogram for the most apical component of the JE position when considering both buccal and lingual flange assessments.*

below the implant-abutment gap. Following determination and quantification of JE position at both the buccal and lingual flanges, statistical analysis was performed by multiple Yates' corrected chi-square tests with $\alpha = .05$.

Results

Postoperative clinical assessment showed uneventful soft tissue healing around the abutments after placement. Clinical evaluation one week after implantation showed no clinical evidence of inflammation or signs of infection despite the lack of hygiene control. The healing period was uneventful for all animals.

The histograms presenting positive (presented in black and gray) and negative (presented in pink) JE position outcomes when the buccal and lingual flange measurements were combined, as well as outcomes for the buccal and lingual flange separately, are presented in Figs 3 to 5. Irrespective of implant system, all histograms depict a notable difference in the number of negative outcomes for implants that were not covered with abutments that were lased in the cervical region. Relative to the buccal flange (Fig 4), the lingual flange (Fig 5) presented the highest number of observations for the best case scenario (JE above the abutment-lased region). The number of negative outcomes was identical for the lingual and buccal flanges when nonlased abutments were considered (Figs 4 and 5), and a small fraction of negative outcomes were observed for lased abutments on the buccal flange (Fig 4).

© 2016 BY QUINTESSENCE PUBLISHING CO, INC. PRINTING OF THIS DOCUMENT IS RESTRICTED TO PERSONAL USE ONLY.
NO PART MAY BE REPRODUCED OR TRANSMITTED IN ANY FORM WITHOUT WRITTEN PERMISSION FROM THE PUBLISHER.

Statistical analysis showed significant differences within implant systems when the junctional epithelium position was considered for lased and nonlased abutments. A significantly higher number of positive outcomes were observed for the Zimmer and Nobel groups with lased abutments when compared to their nonlased counterparts. The Yates' corrected chi squared and *P* values for comparisons within implant systems are presented in Table 1.

The histologic sections obtained from the implant/peri-implant tissues showed that all implants presented bone in intimate contact with the implant endosteal component irrespective of group.

Despite the different configurations between implant systems and the presence or absence of cervically lased abutment regions, a stratified squamous epithelium was observed at the free, marginal, and gingival sulcus regions (Figs 1 and 2). Irrespective of implant system and experimental group, tissue morphology was consistent with noninflamed tissue, presenting a connective tissue layer without inflammatory infiltrate underlying a parakeratinized epithelial layer. The parakeratinized tissue presented its basal and spinous layers, no granular layer, and keratin cells presenting nuclei (Figs 1 and 2). A morphologic difference was noted, however, when the JE was positioned above the lased abutment region, where perpendicularly oriented connective tissue fibers were observed in proximity with the lased abutment region (Fig 2a). A similar morphology was observed for lased abutment implants where the most apical JE was observed within the upper half of the lased region, and a parallel collagen orientation in the connective tissue was observed when the most apical component of the JE was observed in the lower half of the lased abutment region (Fig 2b). When the most apical component of the JE was at or below the implant-abutment gap, a parallel collagen orientation in the connective tissue was observed irrespective of implant system and abutment group (Fig 2c).

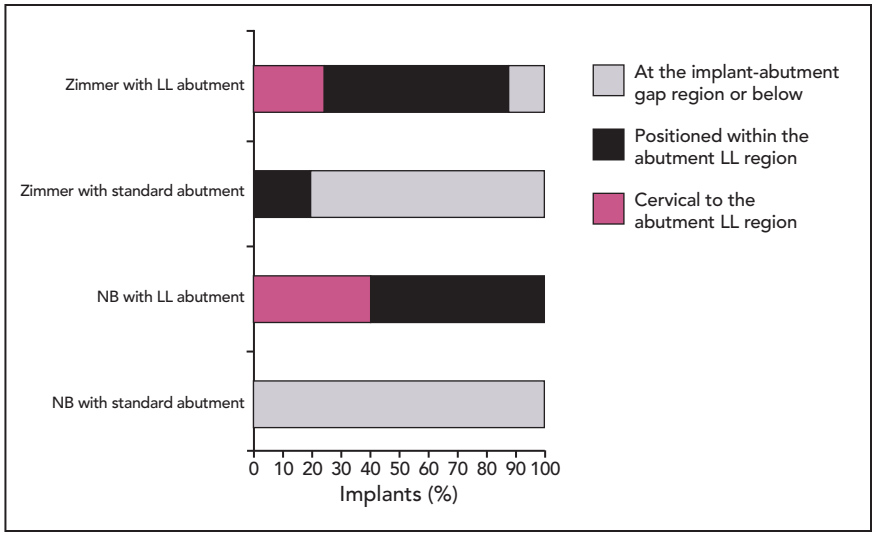

Fig 4 *Summary histogram for the JE position when considering the buccal flange assessment.*

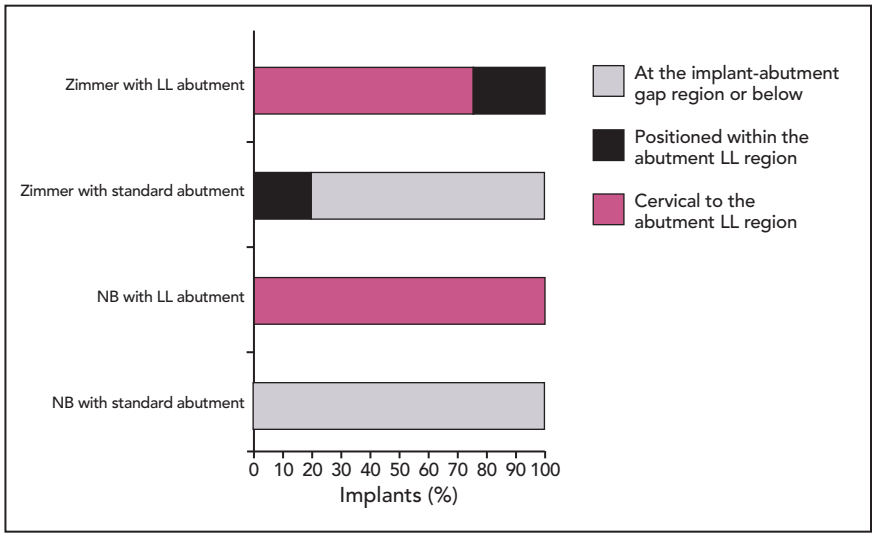

Fig 5 *Summary histogram for the JE position when considering the lingual flange assessment.*

© 2016 BY QUINTESSENCE PUBLISHING CO, INC. PRINTING OF THIS DOCUMENT IS RESTRICTED TO PERSONAL USE ONLY.
NO PART MAY BE REPRODUCED OR TRANSMITTED IN ANY FORM WITHOUT WRITTEN PERMISSION FROM THE PUBLISHER.

Table 1 **Statistical analysis summary comparing presence of lased vs nonlased abutment for Zimmer and Nobel groups[a]**

	Buccal and lingual flanges	Buccal flange	Lingual flange
Zimmer with lased abutment vs Zimmer with nonlased abutment			
Chi-square	12.88	4.43	5.87
P	< .001	.035	.015
Nobel with lased abutment vs Nobel with nonlased abutment			
Chi-square	16.2	6.4	6.4
P	< .001	.011	.011

[a]Yates' corrected chi-square and *P* values.

Discussion

The stability of the peri-implant soft tissue seal or biologic width has been considered one of the most significant factors in the maintenance of peri-implant crestal bone levels.[15] The stability of the peri-implant seal has been shown to be negatively influenced by unstable implant-abutment connections leading to abutment micromovement during function, and by creation of a favorable environment for the colonization and proliferation of anaerobic bacteria that ultimately affect soft tissue health and rupture the peri-implant soft tissue seal.[16,17]

Other factors have been shown to further contribute to this process, such as the presence of foreign materials within the peri-implant crevice (ie, cement), overcontoured or undercontoured restorative abutments and restorations, the type and quality of the existing peri-implant soft tissues, and excessive occlusal load.[18–21] Advancements in implant surface treatment, restorative materials and techniques, and more rigid and passive implant-abutment connections have been shown to minimize these predisposing factors that disrupt the peri-implant soft tissue seal with the oral cavity and, as a consequence, assist in the prevention of progressive bone loss that could ultimately result in the loss of the implant-supported rehabilitation. Since these manmade errors could lead to clinical complications or even implant failures, efforts should be made to prevent or minimize the risk for such unwanted consequences.[8]

The type of soft tissue attachment and consequent formation of the peri-implant soft tissue seal to titanium is considered one of the most significant predisposing factors related to peri-implant bone loss in the presence of inflammation or injury. The lack of connective tissue fiber insertion seen in traditional implant abutments and cervical regions limits soft tissue attachment to titanium.[15,22]

Soft tissue attachment to smooth titanium surfaces takes place via hemidesmosomal and basal lamina and formation of a long JE, which creates a less than ideal barrier for bacteria and inflammation.[6–8] Titanium surface treatments that could promote not only a more stable epithelial attachment but also connective tissue fiber insertion into either the implant cervical region or the base of the abutment should lead to a more stable and protective peri-implant soft tissue seal and subsequent maintenance of peri-implant crestal bone levels could result in more favorable clinical prognoses.[11–14] Previous preclinical histologic studies have shown that laser-etched titanium implants and abutments of one particular dental implant system were able to improve soft tissue seal around dental implants.[6–8] The advantages of such a feature include not only prevention of progressive peri-implant bone loss, but also esthetic maintenance.

The present study aimed to test the hypothesis that laser-etched restorative abutments connected to commercially available dental implants without laser-etched surface treatment would promote the formation of a peri-implant seal in a more coronal position compared with the seal found when regular stock abutments were used and/or similar to the peri-implant seal previously observed when laser-etched implants or a combination of laser-etched implants and laser-etched abutments were used.[6–8] The results have unequivocally demonstrated that this technology is applicable to standard transmucosal components connected to nonlased implants, suggesting that the major benefit of this surface treatment is

© 2016 BY QUINTESSENCE PUBLISHING CO, INC. PRINTING OF THIS DOCUMENT IS RESTRICTED TO PERSONAL USE ONLY.
NO PART MAY BE REPRODUCED OR TRANSMITTED IN ANY FORM WITHOUT WRITTEN PERMISSION FROM THE PUBLISHER.

at the level of the restorative abutment collar rather than the implant body. Hence, standard implants are capable of developing more stable peri-implant seals once restorative abutments with laser-etched cervical collars are used.

One potential limitation of this study was that bacterial plaque was not controlled either mechanically or chemically. Future studies should test whether these abutments are capable of maintaining this peri-implant seal when inflammation is induced. It is also important to determine the ideal timing for the application of this technology, since the peri-implant crevice starts to form as soon as the implant is exposed to the oral cavity and final restorative abutments cannot always be connected at the time of implant abutment surgery or immediately following implant placement.

Conclusions

Despite the limitations of this study, it can be concluded that laser-etched restorative abutments are effective even used without laser-etched dental implants. This technology may also be applicable to other types of dental implants with standard surface treatments.

Acknowledgments

The present study was partially funded by Biohorizons, USA. The authors reported no conflicts of interest related to this study.

References

1. Coelho PG, Jimbo R. Osseointegration of metallic devices: Current trends based on implant hardware design. Arch Biochem Biophys 2014;561:99–108.
2. Coelho PG, Jimbo R, Tovar N, Bonfante EA. Osseointegration: Hierarchical designing encompassing the macrometer, micrometer, and nanometer length scales. Dent Mater 2015;31:37–52.
3. Tian Y, Chen C, Li S, Huo Q. Research progress on laser surface modification of titanium alloys. Applied Surface Science 2005;242:177–184.
4. Yue T, Yu J, Mei Z, Man H. Excimer laser surface treatment of Ti–6Al–4V alloy for corrosion resistance enhancement. Materials Letters 2002;52:206–212.
5. Jimbo R, Tovar N, Yoo DY, Janal MN, Anchieta RB, Coelho PG. The effect of different surgical drilling procedures on full laser-etched microgrooves surface-treated implants: An experimental study in sheep. Clin Oral Implants Res 2014; 25:1072–1077.
6. Nevins M, Kim DM, Jun SH, Guze K, Schupbach P, Nevins ML. Histologic evidence of a connective tissue attachment to laser microgrooved abutments: A canine study. Int J Periodontics Restorative Dent 2010;30:245–255.
7. Nevins M, Nevins M, Gobbato L, Lee HJ, Wang CW, Kim DM. Maintaining interimplant crestal bone height via a combined platform-switched, Laser-Lok implant/abutment system: A proof-of-principle canine study. Int J Periodontics Restorative Dent 2013;33:261–267.
8. Nevins M, Nevins ML, Camelo M, Boyesen JL, Kim DM. Human histologic evidence of a connective tissue attachment to a dental implant. Int J Periodontics Restorative Dent 2008;28:111–121.
9. Collins JR, Berg RW, Rodríguez M, Rodríguez I, Coelho PG, Tovar N. Evaluation of human periimplant soft tissues around nonsubmerged machined standard and platform-switched abutments. Implant Dent 2015;24:57–61.
10. Collins JR, Sued MR, Rodriguez IJ, Berg R, Coelho PG. Evaluation of human peri-implant soft tissues around alumina-blasted/acid-etched standard and platform-switched abutments. Int J Periodontics Restorative Dent 2013;33: e51–e57.
11. Farronato D, Mangano F, Briguglio F, Iorio-Siciliano V, Riccitiello F, Guarnieri R. Influence of Laser-Lok surface on immediate functional loading of implants in single-tooth replacement: A 2-year prospective clinical study. Int J Periodontics Restorative Dent 2014;34:79–89.
12. Gopalakrishnan D, Joshi V, Romanos GE. Soft and hard tissue changes around laser microtexture single tooth implants—A clinical and radiographic evaluation. Implant Dent 2014;23:570–575.
13. Pecora GE, Ceccarelli R, Bonelli M, Alexander H, Ricci JL. Clinical evaluation of laser microtexturing for soft tissue and bone attachment to dental implants. Implant Dent 2009;18:57–66.
14. Shapoff CA, Lahey B, Wasserlauf PA, Kim DM. Radiographic analysis of crestal bone levels around Laser-Lok collar dental implants. Int J Periodontics Restorative Dent 2010;30:129–137.
15. Nevins M. What are the implications of peri-implantitis? Int J Periodontics Restorative Dent 2015;35:451.
16. Ericsson I, Persson LG, Berglundh T, Marinello CP, Lindhe J, Klinge B. Different types of inflammatory reactions in peri-implant soft tissues. J Clin Periodontol 1995;22:255–261.
17. Hermann JS, Buser D, Schenk RK, Higginbottom FL, Cochran DL. Biologic width around titanium implants. A physiologically formed and stable dimension over time. Clin Oral Implants Res 2000; 11:1–11.
18. Duyck J, Vandamme K. The effect of loading on peri-implant bone: A critical review of the literature. J Oral Rehabil 2014; 41:783–794.
19. Hsu YT, Mason SA, Wang HL. Biological implant complications and their management. J Int Acad Periodontol 2014; 16:9–18.
20. Pellegrini G, Canullo L, Dellavia C. Histological features of peri-implant bone subjected to overload. Ann Anat 2016;206:37–63.
21. Renvert S, Polyzois I, Persson GR. Treatment modalities for peri-implant mucositis and peri-implantitis. Am J Dent 2013;26:313–318.
22. Nevins M, Camelo M, Nevins ML, Schupbach P, Kim DM. Connective tissue attachment to laser-microgrooved abutments: A human histologic case report. Int J Periodontics Restorative Dent 2012;32:385–392.

© 2016 BY QUINTESSENCE PUBLISHING CO, INC. PRINTING OF THIS DOCUMENT IS RESTRICTED TO PERSONAL USE ONLY.
NO PART MAY BE REPRODUCED OR TRANSMITTED IN ANY FORM WITHOUT WRITTEN PERMISSION FROM THE PUBLISHER.