



© 2016 BY QUINTESSENCE PUBLISHING CO, INC. PRINTING OF THIS DOCUMENT IS RESTRICTED TO PERSONAL USE ONLY.
NO PART MAY BE REPRODUCED OR TRANSMITTED IN ANY FORM WITHOUT WRITTEN PERMISSION FROM THE PUBLISHER.

Clinical Use of Laser-Microtextured Abutments: A Case Series



Cary A. Shapoff, DDS[1]
Jeffrey A. Babushkin, DDS[2]
David J. Wohl, DDS[3]

This article discusses the clinical use of laser-microtextured abutments on dental implant restorations. Four cases are presented, each using one of the four commercially available laser-microtextured abutment styles. Numerous preclinical and clinical studies have shown the positive effects of laser microtexturing on the implant platform in limiting crestal bone loss and benefiting soft tissue stability. Other histologic studies of laser microtexturing on the implant abutment have demonstrated the ability of this specific feature to block epithelial downgrowth and provide a functional connective tissue attachment to the abutment surface. Other abutment designs, styles, and materials have only demonstrated a soft tissue seal with epithelial adhesion and a circular ring of connective tissue fibers around the abutment without direct contact. This article presents clinical and radiographic case examples from a private practice perspective on the long-term successful use of microtextured abutments with respect to crestal bone levels, exceptional soft tissue health, and stability with minimal sulcular depth.
Int J Periodontics Restorative Dent 2016;36:655–662. doi: 10.11607/prd.2854

[1]Private Practice Limited to Periodontics and Dental Implants, Fairfield, Connecticut, USA.
[2]Private Practice, Trumbull, Connecticut, USA.
[3]Private Practice, Fairfield, Connecticut, USA.

Correspondence to: Dr Cary A. Shapoff, 71 Beach Road, Fairfield, CT 06824, USA
Fax: (203) 255-5753. Email: cas@shapoff.com

©2016 by Quintessence Publishing Co Inc.

The esthetic replacement of missing teeth with implant restorations is predicated on the maintenance of the gingival architecture.[1] The transmucosal component of the prosthesis can either enhance or detract from the stability of this soft tissue interface. The addition of a laser-microtextured feature to this abutment has been shown to provide a predetermined site for soft tissue attachment. This collagenous network of attached fibers has been demonstrated to provide a biologic seal in histologic studies in dogs and humans. The attachment prevented apical epithelial migration and maintained the underlying crestal bone. These fibers were shown to have a perpendicular orientation under polarized light, and scanning electron microscopy (SEM) demonstrated collagen fibers attaching to the laser-microtextured abutment surface.[2–5]

In another clinical study, implant abutments with laser-microtextured surfaces were removed with the surrounding soft tissue at 6 weeks after placement and evaluated by histology and SEM. The authors noted that the most apical epithelium was found coronal to the laser-microtextured surface. The connective tissue contained collagen fibers with a perpendicular orientation to the surface, and intimate contact was seen between the connective tissue and the abutment surface. They

© 2016 BY QUINTESSENCE PUBLISHING CO, INC. PRINTING OF THIS DOCUMENT IS RESTRICTED TO PERSONAL USE ONLY.
NO PART MAY BE REPRODUCED OR TRANSMITTED IN ANY FORM WITHOUT WRITTEN PERMISSION FROM THE PUBLISHER.

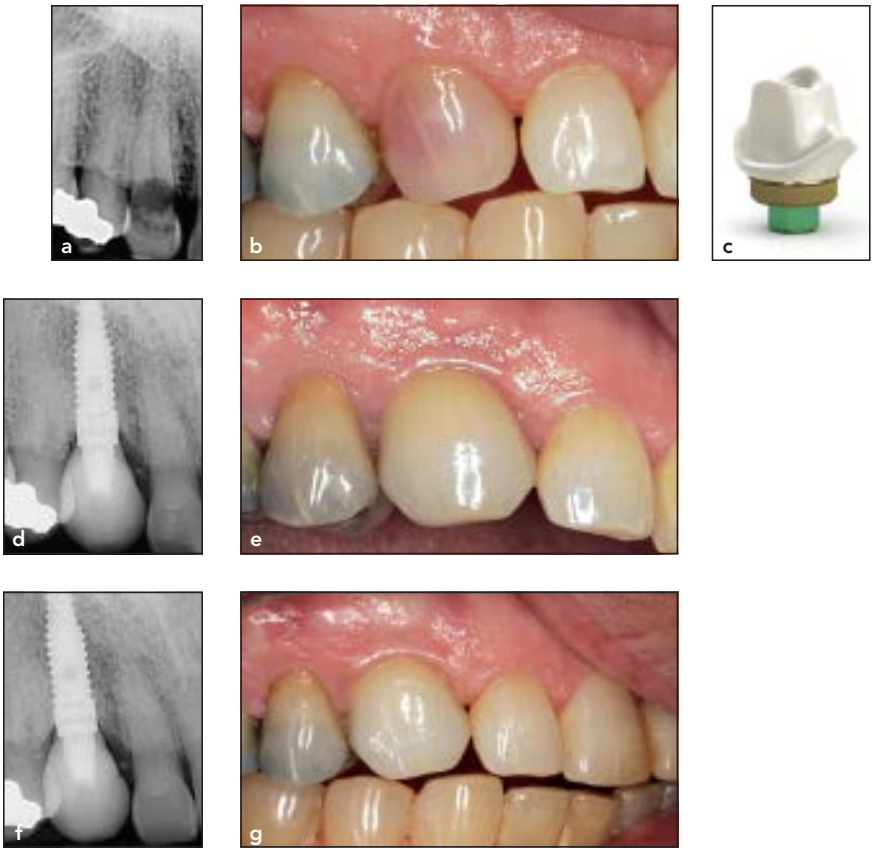

Fig 1 Case 1. (a) *Preoperative radiograph exhibiting nonrestorable external resorption.* (b) *Clinical photograph of tooth with external resorption.* (c) *Schematic of a laser-microtextured Ti base abutment with mesostructure.* (d) *Radiograph at time of final restoration.* (e) *Clinical photograph at time of final restoration.* (f) *Radiograph at 4.5 years postrestoration.* (g) *Clinical photograph at 4.5 years postrestoration.*

concluded that the abutments showed connective tissue integration with fibers functionally oriented to the laser-microtextured surface.[6]

These clinical studies demonstrated that this attachment phenomenon occurred during the initial healing response of implant and abutment placement. Subsequent research demonstrated that it would recur after removal of adjacent sulcular epithelium when a laser-microtextured component was replaced.[7,8]

Other abutment designs and abutment-implant connections may have a positive effect on limiting crestal bone loss over time. Various histologic studies demonstrate the parallel arrangement of collagen fibers to a variety of abutment surface materials, smooth and machined titanium, gold, zirconia, and other ceramics.[9–12] This arrangement creates a circumferential cuff only attached to the abutment by epithelial hemidesmosomes. Laser-microtextured features on abutments are quite different and provide a more robust perpendicular collagen fiber attachment.

The protocol followed in this case series included either placement of these abutments at time of implant placement, at second-stage surgery, or with a de-epithelialization protocol. The placement of these abutments at stage 1 or 2 necessitates the one-abutment, one-time strategy. Many times it is not possible to place the final abutment at stage 1 or 2 as the soft tissue architecture needs to be developed using a provisional. The de-epithelialization protocol allows for a bleeding site after the development of the proper gingival scallop and papilla formation by the provisional. The surgery for all cases was performed by C.A.S. The restorations were performed by D.J.W. (Case 2) and J.A.B. (Cases 1, 3, and 4).

Four different laser-microtextured abutments are currently available: a titanium base hybrid abutment, a precontoured esthetic abutment, a Simple Solutions abutment, and a millable titanium abutment. Four cases will be described using each of these abutments.

Case 1: Titanium base abutment with Laser-Lok

A 65-year-old man presented with a chief complaint of a tooth turning pink, and a diagnosis was made of nonrestorable external resorption (Figs 1a and 1b). The tooth was extracted and the site grafted with mineralized allograft bone (MinerOss, Biohorizons) as the dimensions

© 2016 BY QUINTESSENCE PUBLISHING CO, INC. PRINTING OF THIS DOCUMENT IS RESTRICTED TO PERSONAL USE ONLY.
NO PART MAY BE REPRODUCED OR TRANSMITTED IN ANY FORM WITHOUT WRITTEN PERMISSION FROM THE PUBLISHER.

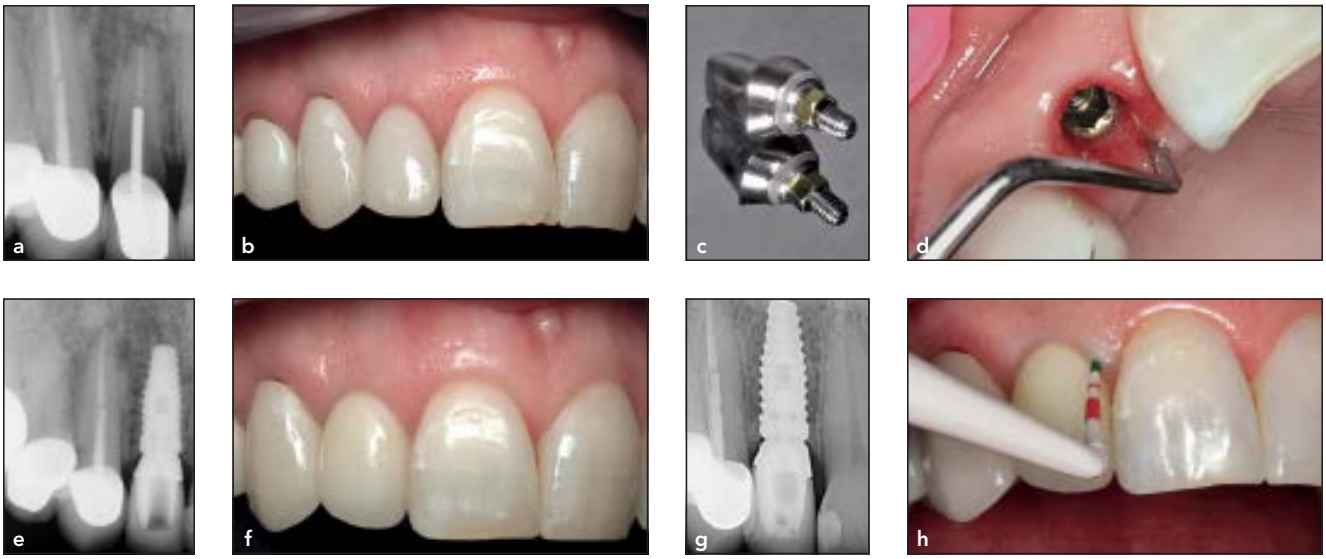

Fig 2 Case 2. (a) *Preoperative radiograph.* (b) *Preoperative clinical photograph.* (c) *Photograph of custom-milled Laser-Lok Ti abutment.* (d) *Photograph of de-epithelization of sulcus with bladed instrument.* (e) *Radiograph at initial placement of final restoration.* (f) *Clinical photograph at initial placement of final restoration.* (g) *Radiograph at 2.5 years postrestoration.* (h) *Clinical photograph at 2.5 years postrestoration.*

of the socket were large and the initial stability of the proposed dental implant was not anticipated.

A resin-bonded provisional tooth replacement with a slightly ovate pontic design was placed to support the gingival tissues. The site was allowed to heal for 4 months. A 4.6 × 15-mm tapered dental implant (BioHorizons Tapered Internal) was placed using a tooth-supported surgical guide and a flapless approach.

A screw-retained provisional was fabricated using a 3-in-One abutment and triad composite resin. The contours of the provisional were developed to sculpt the tissue to the proper free gingival margin position with the papillae filling the gingival embrasures.

The patient returned 1 month later, and proper soft tissue contour was verified. An open-tray impression was taken with a custom transfer coping. A lab-fabricated mesostructure of lithium disilicate was prescribed over a Laser-Lok titanium base (Ti-base) abutment (Fig 1c).

The Laser-Lok Ti-base was placed on a protective sleeve with Teflon tape to prevent the bonding materials from affecting the microgrooved collar. The mesostrucure was then treated with hydrofluoric acid and bonded to the Ti-base with resin cement. A full-coverage lithium disilicate crown was fabricated.

Upon removal of the screw-retained provisional, the healed, nonkeratinized, sulcular epithelium was removed with diamond-tipped cotton pliers to allow for a bleeding site, which is necessary for a blood clot to form adjacent to the microgrooved surface. The Laser-Lok Ti-base abutment was then torqued to 32 Ncm, and a radiograph was taken to verify complete seating. The crown was cemented with resin-modified, glass-ionomer luting cement (Relyx plus luting cement, 3M ESPE) using a replica die technique to minimize excess cement. A postoperative radiograph was taken, the occlusion was adjusted, and the restoration was polished (Figs 1d and 1e).

At 4.5 years following placement of the dental implant and restoration, the crestal bone level and soft tissue marginal stability have been maintained (Figs 1f and 1g). Probing depth around the restoration at the 4.5-year reevaluation was 3 mm interproximally and 2 mm midfacial and midpalatal.

Case 2: Milled titanium abutment

A 54-year-old woman presented with recurrent caries under the crown of an endodontically treated maxillary right lateral incisor (Figs 2a and 2b). The gingival biotype

© 2016 BY QUINTESSENCE PUBLISHING CO, INC. PRINTING OF THIS DOCUMENT IS RESTRICTED TO PERSONAL USE ONLY.
NO PART MAY BE REPRODUCED OR TRANSMITTED IN ANY FORM WITHOUT WRITTEN PERMISSION FROM THE PUBLISHER.

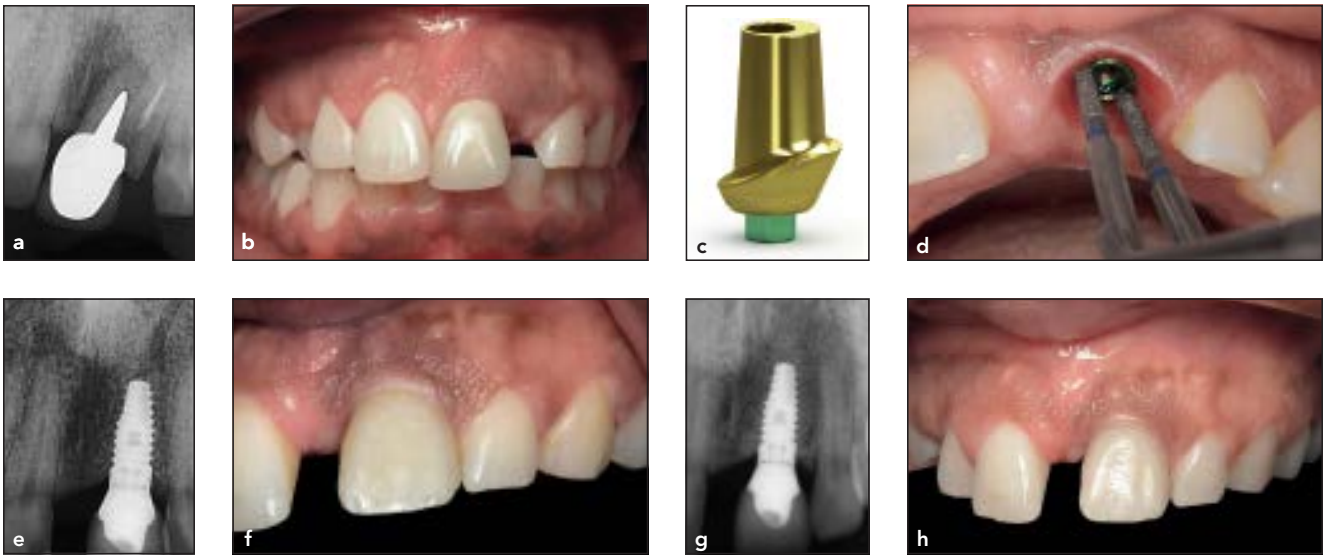

Fig 3 Case 3 (a) *Preoperative radiograph.* (b) *Preoperative clinical photograph.* (c) *Schematic of prepable Laser-Lok Esthetic abutment.* (d) *Sulcular epithelium removed with diamond-coated pliers.* (e) *Radiograph at initial placement of final restoration.* (f) *Clinical photograph at initial placement of final restoration.* (g) *Radiograph at 4 years postrestoration.* (h) *Clinical photograph at 4 years postrestoration.*

was considered normal to thick, and the CBCT demonstrated adequate palatal bone and root dimension to consider extraction with simultaneous placement and immediate provisionalization. A BioHorizons Tapered Internal Laser-Lok Plus (4.6 × 12-mm implant body; 3.5-mm platform) was placed after atraumatic extraction along the palatal socket wall, and insertion torque of 40 Ncm was achieved. The implant platform was positioned 3 mm apical to the intended facial gingival margin.

After placement of the implant, the patient was seen for an immediate provisional crown. A 3.5-mm platform, PEEK Temporary Abutment (BioHorizons) was placed, and a screw-retained provisional was fabricated and tightened with finger pressure.

Following a 5-month healing phase, a scan body (Core3dcentres) was placed and verified by radiograph. A digital scan was secured (triOS, 3shape), and a custom-milled, Laser-Lok abutment was milled from a BioHorizons Ti abutment (Fig 2c). A layered e.max (Ivoclar Vivadent) crown was fabricated (Oral Arts Dental Lab, Atlanta, Georgia, USA). The sulcus was de-epithelialized with a bladed instrument at a level adjacent to the Laser-Lok microchannels to enhance tissue attachment (Fig 2d). The abutment was seated, verified, and torqued to 30 Ncm. Cotton was placed in the abutment chamber and cemented with TempBond NE (Kerr) (Figs 2e and 2f).

Figures 2g and 2h show a radiograph and a clinical photograph taken 2.5 years after restoration demonstrating stable crestal bone levels adjacent to the Laser-Lok implant collar. Stable, healthy marginal tissue is demonstrated by nonbleeding, shallow periodontal probing depths of 2 mm or less around all surfaces of the restoration.

Case 3: Use of a precontoured laser-microtextured esthetic abutment to replace a left maxillary central incisor

A 25-year-old woman presented for treatment of a vertically fractured maxillary central incisor. The radiographs revealed a large area of alveolar bone loss associated with the fractured root segments (Fig 3a). The fractured root segment and

© 2016 BY QUINTESSENCE PUBLISHING CO, INC. PRINTING OF THIS DOCUMENT IS RESTRICTED TO PERSONAL USE ONLY.
NO PART MAY BE REPRODUCED OR TRANSMITTED IN ANY FORM WITHOUT WRITTEN PERMISSION FROM THE PUBLISHER.

crown portion had pathologically migrated into the space created by the anterior diastema (Fig 3b). Restoration using a maxillary fixed bridge was not considered because of the natural diastema and replacement; restoration with a single dental implant was planned after an initial phase of extraction and alveolar ridge reconstruction. Following debridement, the partially contained bony defect (16 × 10 mm) was filled with a composite graft of cortical and cancellous mineralized allograft (MinerOss, Biohorizons) and DBBA (Bio-Oss, Geistlich) and allowed to heal for 5 months. The selection of this bone graft combination was based on the large size of the defect requiring dense graft particles to assist in flap support during the healing period. A 12-mm BioHorizons Tapered Internal implant (4.5-mm platform) was placed using a surgical guide designed to recreate the crown with the natural diastema spacing. After 5 months, second stage surgery was accomplished with a tissue punch approach and a screw-retained provisional was placed to shape the gingival tissue. A laser-microtextured precontoured esthetic abutment (Fig 3c) was placed and the margins prepared with a diamond bur and copious irrigation. An e.max lithium disilicate crown was fabricated, stained, glazed, and crystalized. The abutment was ultrasonically cleaned with Enzymax (Hu-Friedy) for 15 minutes prior to delivery. The apical portion of the sulcular epithelium was removed by lightly abrading the sulcus with diamond-coated pliers and the abutment was torqued into place (Fig 3d). The crown was cemented using Multilink Implant resin cement, and a postoperative radiograph (Fig 3e) and clinical photograph (Fig 3f) were taken.

The radiographic crestal bone levels (Fig 3g) and clinical tissue stability (Fig 3h) are demonstrated at 4 years following placement of the initial implant and restoration.

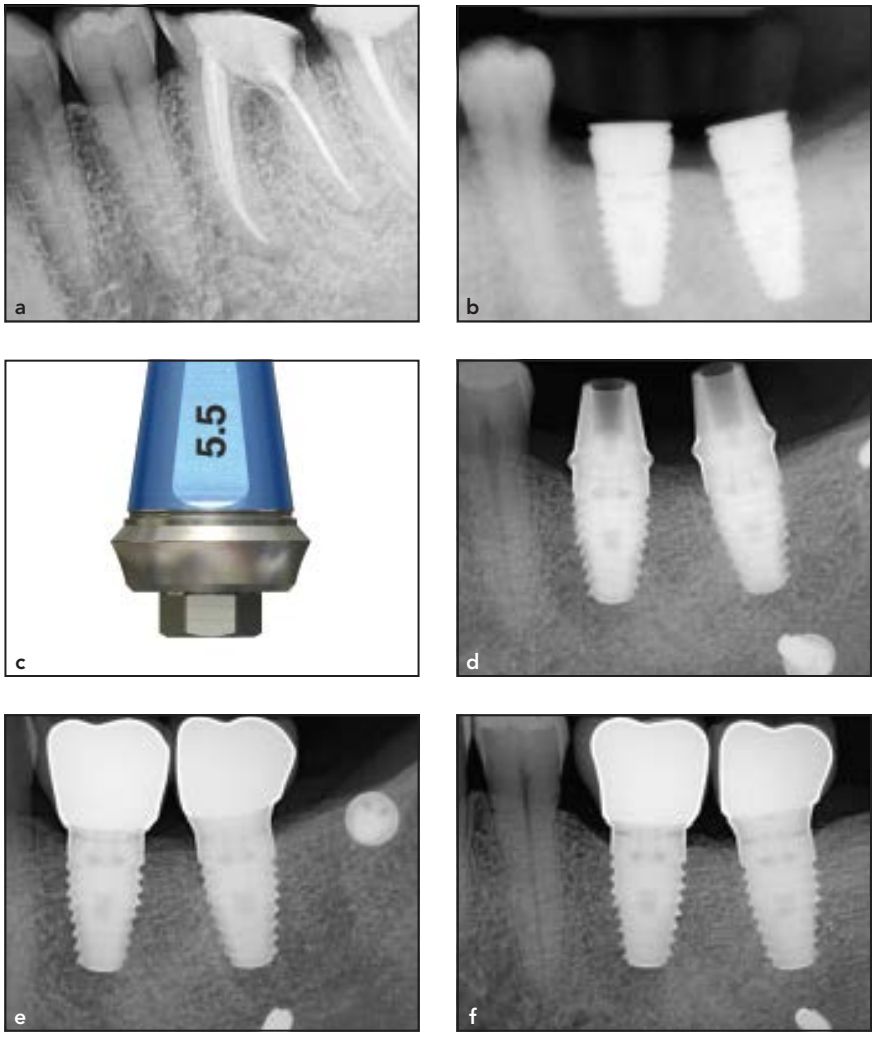

Fig 4 Case 4. (a) *Preoperative radiograph.* (b) *Surgical implant postoperative radiograph: single-stage placement.* (c) *Schematic of Simple Solutions abutment.* (d) *Radiograph: placement of Simple Solutions abutment.* (e) *Radiograph after placement of final restoration.* (f) *Radiograph at 18 months after final restoration.*

Case 4: Simple solutions abutment with Laser-Lok

A 38-year-old man presented with the chief complaint of a toothache in the mandibular left quadrant. The first and second molars had had prior endodontic treatment, and the clinical crowns were fractured and decayed (Fig 4a). The

© 2016 BY QUINTESSENCE PUBLISHING CO, INC. PRINTING OF THIS DOCUMENT IS RESTRICTED TO PERSONAL USE ONLY.
NO PART MAY BE REPRODUCED OR TRANSMITTED IN ANY FORM WITHOUT WRITTEN PERMISSION FROM THE PUBLISHER.

teeth were extracted and the sockets were debrided and grafted with a mixture of cancellous and cortical allograft bone (MinerOss, Biohorizons). The grafting procedure was necessary to prevent or minimize postextraction ridge resorption as the socket dimensions were large. After 4 months of healing, two 5.8 × 10.5-mm tapered dental implants (BioHorizons Tapered Internal) were placed using a prosthetically designed surgical guide (Fig 4b).

The patient returned for the final restoration 4 months after implant placement. The standard healing abutments were removed and the sulcus depth was measured. Laser-microgrooved Simple Solutions abutments with a 1.8-mm transmucosal collar and a 5.5-mm vertical height were selected (Fig 4c). The sulcular epithelium was removed with a coarse diamond bur in a high-speed handpiece to initiate a bleeding wound. The Simple Solutions abutments were then placed and torqued to 30 Ncm. A radiograph was taken to verify complete seating (Fig 4d). Impression caps were snapped into place and a closed-tray, abutment-level impression was taken. At delivery, the final crowns were tried in, the marginal fit verified, and the occlusion checked.

The crowns were cemented with resin-modified, glass-ionomer luting cement (Relyx plus luting cement, 3M ESPE). Postoperative radiographs of the Laser-Lok Simple Solutions abutment and final restoration were taken (Fig 4e). An 18-month follow-up radiograph demonstrates stable crestal bone levels (Fig 4f).

Discussion

Numerous abutment choices are available for all popular implant systems. These abutments are generally Ti, gold, zirconia, or a hybrid of ceramic on a Ti base. The subgingival portion of these stock, custom, or computer-aided design/computer-assisted manufacture (CAD/CAM) abutments is commonly polished and smooth.[13]

The histologic appearance of connective tissue around both machined Ti and zirconia abutments was in a parallel circular fiber arrangement as demonstrated by Berglundh et al.[10] Approximately 89% of the fibers were unattached and circumferential in arrangement. The formation of this biologic width relies on a hemidesmosomal attachment of junctional epithelium to the polished surface.

Nevins et al, however, in a series of human and animal histologic studies, have demonstrated a different connective tissue arrangement when using prosthetic abutments with a 1-mm band of 8-μ, laser-microtextured, horizontal grooves on the apical portion of the abutment.[3–5] The majority of the connective tissue fiber arrangement was perpendicular to the abutment surface as demonstrated with polarized light microscopy. These fibers appeared attached to the nanotextured surface within the 8-μ grooves. This functional attachment arrangement mimicked the Sharpey fiber arrangement seen with the natural tooth. More significantly, the apical migration of the epithelial cells appeared to be blocked by the horizontally arranged, nonrandom microchannels. Ricci et al have also demonstrated that these laser-microtextured grooves inhibited epithelial migration.[14–16] This phenomenon of connective tissue attachment demonstrated by the Nevins et al studies coronal to the implant-abutment interface has significant clinical implications. Limiting the epithelial downgrowth along an implant-abutment surface can result in shallower sulcular depth on an implant restoration.[17] In addition, blocking the epithelial downgrowth with a functionally oriented attachment of connective tissue may provide protection to the crestal bone, resulting in reduced crestal bone loss.[18]

As improvements in implant surface texturing have made osseointegration more predictable, the emphasis has shifted to soft tissue stability. Numerous techniques have evolved for maintaining soft tissue health around dental implants. Rompen et al[19] have described a converging subgingival implant-abutment design to thicken the sulcular soft tissue to improve gingival stability. The smooth metal abutment collar is altered to promote the formation of a fibrous ring of soft tissue in the transmucosal tissue. This smooth metal surface allows for a long junctional adhesion. This technique is not always a plausible solution as it is based on an implant placement that is both apical and palatal enough to accommodate the design. Implant placement that deviates in a facial or coronal position will not allow for this emergence profile.

© 2016 BY QUINTESSENCE PUBLISHING CO, INC. PRINTING OF THIS DOCUMENT IS RESTRICTED TO PERSONAL USE ONLY.
NO PART MAY BE REPRODUCED OR TRANSMITTED IN ANY FORM WITHOUT WRITTEN PERMISSION FROM THE PUBLISHER.

Numerous authors have described techniques to increase soft tissue stability around dental implants by performing biotype conversion procedures. Kan et al and Tsuda et al describe a technique of subepithelial connective tissue grafting at the time of implant placement as a means of improving soft tissue stability.[20,21] They report less facial gingival change with grafting than on the nongrafted control samples.

The current platform-switched designs offered by many implant companies are another attempt to improve the thickness of the soft tissue and reduce the loss of marginal bone around the implants. The benefits of improved crestal stability have been documented by numerous authors.[22–25] However, the detrimental effects of using narrower wall prosthetics have not been elucidated.

The de-epithelialization techniques used in these four cases were chosen by the two restorative clinicians. The implant manufacturer has developed and is currently testing an instrument to safely remove the sulcular epithelium immediately adjacent to the abutment Laser-Lok surface. However, each method used for the restorative phase appeared to result in similar outcomes. When using these de-epithelialization methods, it is advised to place the cover screw on the implant to avoid damage to the edge of the implant platform.

The ability to form a series of connective tissue attachments above the implant-abutment junction may allow a biologic seal to help preserve not only the free gingival margin and the papilla but also the underlying crest of bone. This may translate to a shallow and stable sulcular depth that allows for predictable implant crown marginal placement.

Conclusions

This article presents the clinical application of nonrandom, nanotextured microchannels on the subgingival surface of various abutment styles in a private practice setting. All cases demonstrated stable crestal bone levels and clinically healthy subgingival tissues with shallow sulcular depth. Although only four cases demonstrating an example of each available abutment with laser microtexturing were presented, the authors have restored many more implants with these abutments with similar successful outcomes. These cases represent the earliest use of each abutment style. Continued case follow-up and a larger sample size would be necessary to further verify the unique and beneficial effects of the laser-microtextured abutments.

Acknowledgments

Honoraria have been provided to the authors for speaking at BioHorizons-sponsored programs. The authors reported no conflicts of interest related to this study.

References

1. Belser UC, Grütter L, Vailati F, Bornstein MM, Weber HP, Buser D. Outcome evaluation of early placed maxillary anterior single-tooth implants using objective esthetic criteria: A cross-sectional, retrospective study in 45 patients with a 2- to 4-year follow-up using pink and white esthetic scores. J Periodontol 2009; 80:140–151.
2. Nevins M, Nevins ML, Camelo M, Boyesen JL, Kim DM. Human histologic evidence of a connective tissue attachment to a dental implant. Int J Periodontics Restorative Dent 2008;28:111–121.
3. Nevins M, Kim DM, Jun SH, Guze K, Schupbach P, Nevins ML. Histologic evidence of a connective tissue attachment to laser microgrooved abutments: A canine study. Int J Periodontics Restorative Dent 2010;30:245–255.
4. Nevins M, Camelo M, Nevins ML, Schupbach P, Kim DM. Connective tissue attachment to laser-microgrooved abutments: A human histologic case report. Int J Periodontics Restorative Dent 2012; 32:385–392.
5. Nevins M, Camelo M, Nevins ML, Shcupbach P, Kim DM. Reattachment of connective tissue fibers to a laser-microgrooved abutment surface. Int J Periodontics Restorative Dent 2012;32: e131–e134.
6. Geurs N, Vassilopoulos PJ, Reddy MS. Histological evidence of connective tissue integration on laser microgrooved abutments in humans. Clin Adv Periodontics 2011;11:29–33.
7. Geurs N, Geisinger M, Vassilopoulos P, O'Neal S, Reddy, M. Optimizing connective tissue integration on laser-ablated implant abutments. Clin Adv Periodontics (in press).
8. Neiva R, Tovar N, Jimbo R, et al. Guidelines for clinical management of laser-etched (Laser-Lok) abutments in two different clinical scenarios: A preclinical soft tissue laboratory assessment study. Int J Restorative Dent 2016;36:339–345.
9. Çomut AA, Weber HP, Shortkroff S, Wi FZ, Spector M. Connective tissue orientation around dental implants in a canine model. Clin Oral Implants Res 2001; 12:433–440.
10. Berglundh T, Lindhe J, Ericsson I, Marinello CP, Liljenberg B, Thomsen P. The soft tissue barrier at implants and teeth. Clin Oral Implants Res 1991;2:81–90.

© 2016 BY QUINTESSENCE PUBLISHING CO, INC. PRINTING OF THIS DOCUMENT IS RESTRICTED TO PERSONAL USE ONLY.
NO PART MAY BE REPRODUCED OR TRANSMITTED IN ANY FORM WITHOUT WRITTEN PERMISSION FROM THE PUBLISHER.

11. Tetè S, Mastrangelo F, Bianchi A, Zizzari F, Scarano A. Collagen fiber orientation around machined titanium and zirconia dental implant necks: An animal study. Int J Oral Maxillofac Implants 2009; 24:52–58.
12. Welander M, Abrahamsson I, Berglundh T. The mucosal barrier at implant abutments of different materials. Clin Oral Implants Res 2008;19:635–641.
13. Drago C, Lazzara RJ. Guidelines for implant abutment selection for partially edentulous patients. Compend Contin Educ Dent 2010;31:14–27.
14. Ricci JL, Grew JC, Alexander H. Connective-tissue responses to defined biomaterial surfaces. I. Growth of rat fibroblast and bone marrow cell colonies on microgrooved substrates. J Biomed Mater Res A 2008;85:313–325.
15. Grew JC, Ricci JL, Alexander H. Connective-tissue responses to defined biomaterial surfaces. II. Behavior of rat and mouse fibroblasts cultured on microgrooved substrates. J Biomed Mater Res A 2008;85:326–335.
16. Ricci JL, Alexander H. Laser microtexturing of implant surfaces for enhanced tissue integration. Key Engineering Materials 2000;198:179–202.
17. Pecora GE, Ceccarelli R, Bonelli M, Alexander H, Ricci JL. Clinical evaluation of laser microtexturing for soft tissue and bone attachment to dental implants. Implant Dent 2009;18:57–66.
18. Shapoff CA, Lahey B, Wasserlauf PA, Kim DM. Radiographic analysis of crestal bone levels around Laser-Lok collar dental implants. Int J Periodontics Restorative Dent 2010;30:129–137.
19. Rompen E, Raepsaet N, Domken O, Touati B, Van Dooren E. Soft tissue stability at the facial aspect of gingivally converging abutments in the esthetic zone: A pilot clinical study. J Prosthet Dent 2007;97:S119–S125.
20. Kan JY, Rungcharassaeng K, Morimoto T, Lozada J. Facial gingival tissue stability after connective tissue graft with single immediate tooth replacement in the esthetic zone: Consecutive case report. J Oral Maxillofac Surg 2009;67:40–48.
21. Tsuda H, Rungcharassaeng K, Kan JY, Roe P, Lozada JL, Zimmerman G. Peri-implant tissue response following connective tissue and bone grafting in conjunction with immediate single-tooth replacement in the esthetic zone: A case series. Int J Oral Maxillofac Implants 2011; 26:427–436.
22. Canullo L, Pelligrini G, Allievi C, Trombelli L, Annibali S, Dellavia C. Soft tissues around long-term platform switching implant restorations: A histologic human evaluation. Preliminary results. J Clin Periodontol 2011;38:86–94.
23. Canullo L, Fedele GR, Iannello G, Jepsen S. Platform switching and marginal bone-level alterations: The results of a randomized-controlled trial. Clin Oral Implants Res 2010;21:115–121.
24. Atieh MA, Ibrahim HM, Atieh AH. Platform switching for marginal bone preservation around dental implants: A systematic review and meta-analysis. J Periodontol 2010;81:1350–1366.
25. Rodríguez X, Vela X, Calvo-Guirado JL, Nart J, Stappert CF. Effect of platform switching on collagen fiber orientation and bone resorption around dental implants: A preliminary histologic animal study. Int J Oral Maxillofac Implants 2012; 27:1116–1122.

© 2016 BY QUINTESSENCE PUBLISHING CO, INC. PRINTING OF THIS DOCUMENT IS RESTRICTED TO PERSONAL USE ONLY.
NO PART MAY BE REPRODUCED OR TRANSMITTED IN ANY FORM WITHOUT WRITTEN PERMISSION FROM THE PUBLISHER.