Optimizing Connective Tissue Integration on Laser-Ablated Implant Abutments

Nicolaas C. Geurs,* Maria L. Geisinger,* Philip J. Vassilopoulos,* S. Jean O'Neal,† Sandra J. Haigh,* and Michael S. Reddy*

Focused Clinical Question: The integration of connective tissue (CT) to a laser-ablated abutment with a microgrooved surface at the apical millimeter (LL) has been documented in both animal and human studies. How should the healing be influenced to optimize the CT integration on abutment surfaces?

Summary: When smooth machined titanium (ST) abutments were placed, epithelial attachment was found on abutments, but no CT integration was noted. On LL abutments, a zone of epithelial attachment and CT integration was noted. When an ST abutment was switched for an LL abutment, the soft tissue was inconsistent; however, when an LL abutment was placed after the removal of a prior LL abutment, CT integration was observed.

Conclusions: Consistent CT integration was observed on LL abutment surfaces after implant placement. Switching LL abutments with new LL abutments consistently led to CT integration. This was not consistent when an ST abutment was switched for an LL abutment. Plaque and gingival indices were comparable between teeth and abutments. Probing depth (PD) was lower around teeth. There was no difference in PD between abutments. CT integration on LL abutments was optimized by initial healing occurring on an LL abutment or by creation of a CT wound before insertion of the abutment. *Clin Adv Periodontics* 2016;6:153-159.

Key Words: Connective tissue; dental implants; epithelium; histology; microscopy, electron, scanning; wound healing.

Background

Modern endosseous implants are designed to be surgically embedded into alveolar bone, in which once osseointegration has occurred, they serve as long-term artificial replacements for roots of missing teeth or as anchors to stabilize and support full- or partial-arch prostheses.[1-5] Establishing soft tissue peri-implant attachment is essential to peri-implant health and long-term esthetics. Epithelial and connective tissue (CT) attachment to the tooth serves to protect the tooth from periodontal bone loss. The natural attachment apparatus of a tooth includes anchorage of gingival CT into the tooth root surface through fiber insertion. Attachment to a smooth machined surface titanium–implant abutment occurs through hemidesmosomes. This attachment is not as robust as a natural tooth, leading the scientific community to attempt to create an attachment of soft tissue to the abutment of an implant that mimics attachment to a natural tooth.

Innovation and technology, based on sound scientific knowledge, have melded with device design to develop implant body and abutment surfaces that encourage early cellular events in soft and bony tissue healing that may foster long-term tissue health and osseointegration.[6-9] Cell culture experiments,[6,7] animal studies,[10] and preliminary human trials[9] have illustrated the potential of implants and implant abutment surfaces to interact with cells and create a more stable tissue interface. In general, microtextured surfaces are thought to promote faster formation of new bone via osteogenesis, osteoconduction, and osteoinduction processes[6] and may have an effect on adhesion of the fibrin clot, adhesion of extracellular matrix components, and long-term interaction with cells to create a stable tissue interface.[11-13] CT integration has been reported on surfaces of implants retrieved in humans.[14] Integration of CT to the abutment surface has also been documented in both animal[10] and human[15,16] studies. However, how to manage the clinical environment to promote CT attachment has not been well established. The present study discusses requirements for wound creation and management of soft tissue healing phase to create CT attachment on abutment surfaces.

Decision Process

The clinical parameters for establishment of a zone of CT integration on an abutment need to be defined in clear protocols. The decision matrix presented here is based on findings of a trial conducted at the University of Alabama at Birmingham, Birmingham, Alabama. Western Institutional Review Boards, Puyallup, Washington, approved this study, and it was registered at ClinicalTrials.gov as NCT01822223. All participants provided written informed consent prior to treatment. The study was conducted from January 5, 2011 to November 29, 2011. Twenty patients were enrolled (five males and 15 females, aged 54 to 68 years [mean age: 57.60 years] and 36 to 69 years [mean age: 50.93 years], respectively). The

* *Department of Periodontology, School of Dentistry, University of Alabama at Birmingham, Birmingham, AL.*

† *Department of Restorative Sciences, School of Dentistry, University of Alabama at Birmingham.*

Submitted October 27, 2015; accepted for publication December 23, 2015

doi: 10.1902/cap.2016.150068

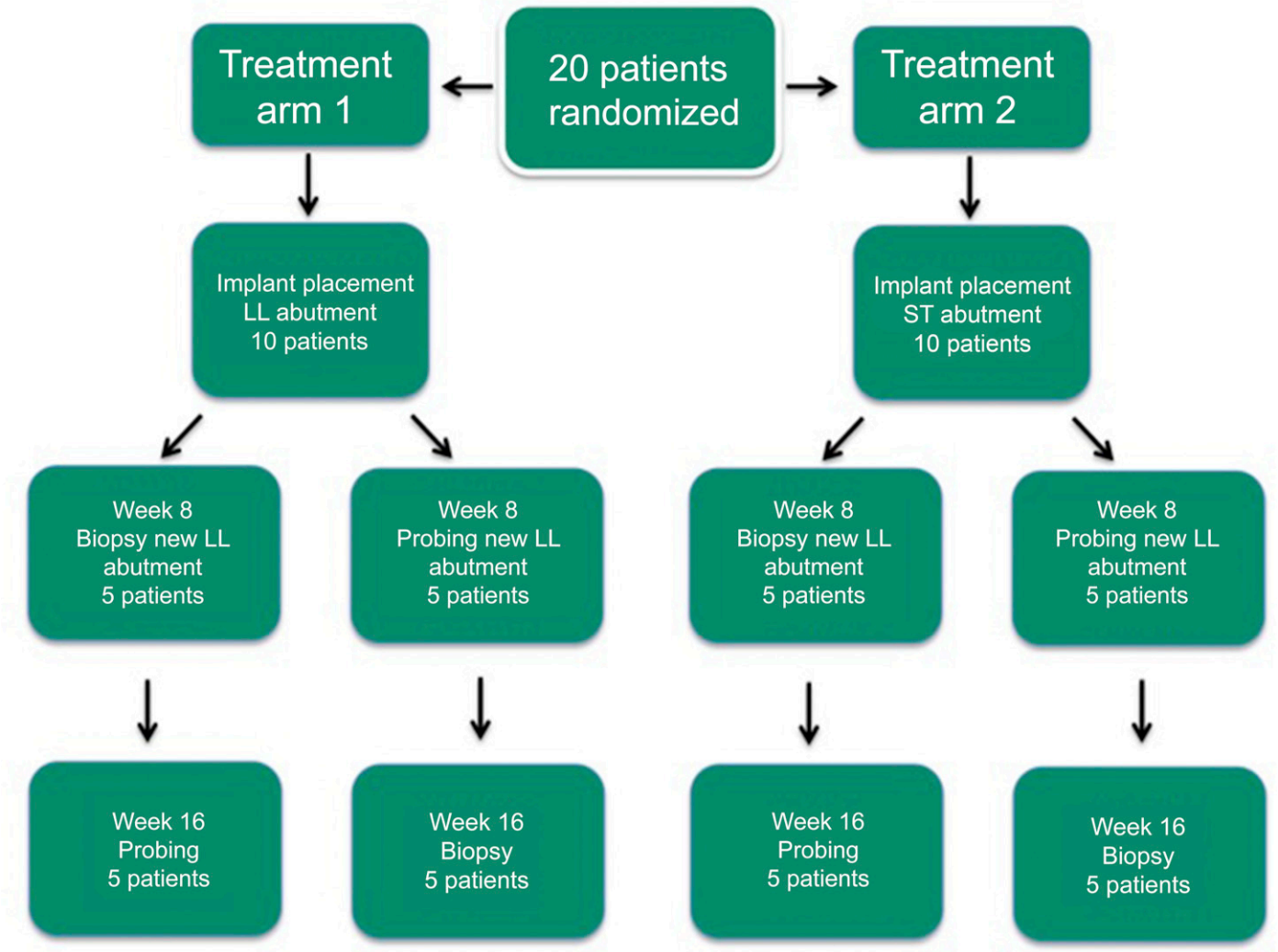

FIGURE 1 Study design.

study compared histologic and clinical results between two different implant abutments: 1) a laser-ablated abutment with a microgrooved surface at the apical millimeter (LL)[‡] and 2) a smooth machined titanium (ST) abutment.[§] Both devices were approved by the Food and Drug Administration. The abutments were analogous in design and material, except the test device had a laser-ablated surface. Both abutment types had a two-piece design and used an abutment screw to attach to the implant. A schematic representation of the study is presented in Figure 1.

A comprehensive treatment plan was developed through consultation between prosthodontic (SJO) and periodontal (NCG, MLG, PJV, and MSR) investigators. Participants received full-mouth oral prophylaxis before implant surgery. Implants were placed using a standard drilling technique. After thorough site irrigation, the implant was inserted directly into the prepared osteotomy. Following the computerized randomization scheme (Fig. 1), either LL or ST abutments were placed. At week 8, all abutments were harvested and replaced by LL abutments.

Five abutments per group were harvested for histologic analysis. Abutments were removed carefully with peri-abutment tissue attached using a soft tissue trephine. Harvesting soft tissue surrounding the abutments proved to be a challenging procedure. Soft tissue remained attached on the abutment surface on only five of 20 abutments harvested. For the other abutments, soft tissue was replaced on the abutment in correct tissue orientation. The shift in tissue location was taken into consideration during interpretation of histologic specimens.

The tissue–abutment construct was placed immediately in fixative, and vials were labeled appropriately. All biopsies were processed and analyzed by a research laboratory scientist, masked to abutment group assignment. Non-demineralized specimens were embedded in resin and polymerized. Blocks were sectioned in an axial direction. Slices were reduced by microgrinding and polishing to a final thickness of 30 to 40 µm. Sections were stained with toluidine blue/azure II stain.

The other five abutments per group were analyzed by scanning electron microscopy (SEM), prepared by dehydration through a graded series of acetones, and dried using carbon dioxide as a transitory fluid.

[‡] Laser-Lok, BioHorizons Implant Systems, Birmingham, AL.
[§] Laser-Lok, BioHorizons Implant Systems.

An adjacent tooth was compared to the implant-supported abutment in each patient. When comparing teeth to the two abutment types, there was no significant difference in mean plaque index (PI) ($P = 0.22$) or gingival index (GI) ($P = 0.29$) values between groups. Overall, all sites showed good mucosal health. There was a significant difference in mean probing depth (PD) values ($P < 0.001$) between groups. The least squares mean (lsmean) for teeth was significantly lower (lsmean = 2.4295) than that for LL (lsmean = 3.3419, $P < 0.001$) and ST (lsmean = 3.0789, $P < 0.001$) abutments. The difference in PDs between ST and LL abutments was not significant.

Clinical Scenario

Healing of CT Around ST Abutments

Figure 2a illustrates SEM and Figure 2b the histology of specimens harvested 8 weeks after placement of ST abutments and are representative of the healing of the soft tissue. Soft tissue appears to have shifted apically during harvesting or processing, and only a zone of epithelium was noted on the abutment surface; no zone of CT was noted on the abutment surface. No CT integration with the abutment surface was noted on 100% of the samples.



FIGURE 2a SEM of ST abutments harvested at 8 weeks. No CT integration with the abutment surface was noted. **2b** Histology of ST abutments harvested at 8 weeks. The soft tissue appears to have shifted apically during harvesting or processing. Only an epithelial zone is noted in tissue adjacent to the abutment (toluidine blue/azure II staining; original magnification ×200).

Healing of CT on LL Abutments

Healing 8 weeks after implant placement with an LL abutment is illustrated in Figure 3. A zone of epithelium adjacent to the abutment surface and a zone of CT on the abutment surface were apparent. Soft tissue attachment observed was a combination of epithelial attachment and CT attachment to the laser-ablated microgrooved surface. This finding was consistent in 100% of samples and showed CT integration.

Healing of CT on LL Abutments Inserted After the Removal of ST Abutments

Figure 4 illustrates SEM and histology of a specimen harvested 8 weeks after an abutment switch from ST to LL. CT integration is not observed, and oral biofilm is noted on the microgrooved surface. Figure 5 illustrates another

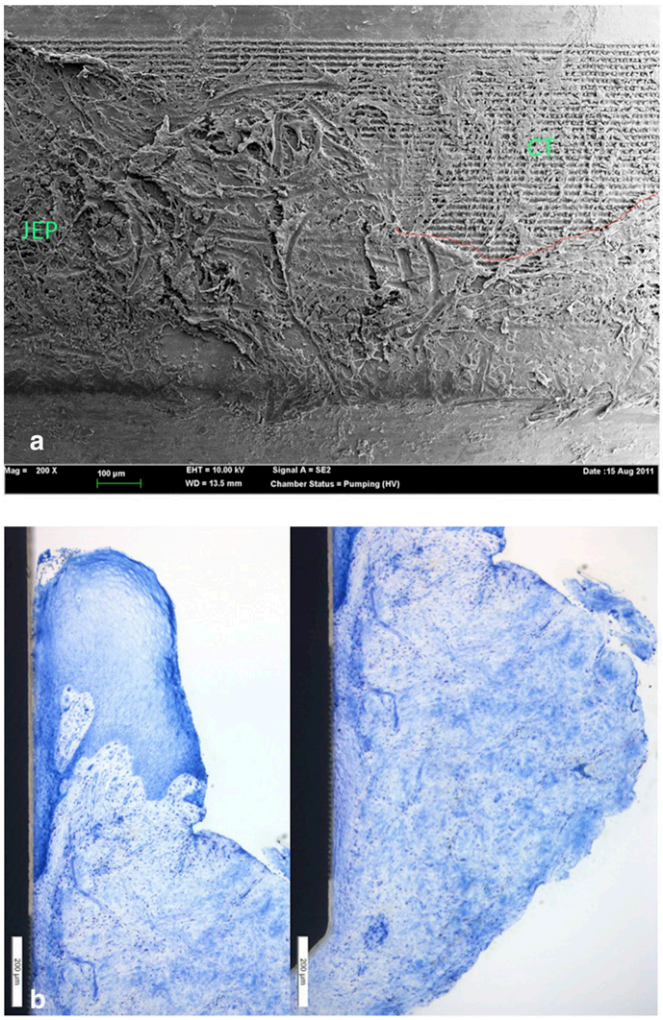

FIGURE 3a SEM of LL abutment harvested after 8 weeks. Soft tissue attachment observed was a combination of epithelial attachment and CT attachment to the laser-ablated microgrooved surface. JEP = junctional epithelium. **3b** Histology of LL abutment harvested after 8 weeks. A zone of epithelium adjacent to the abutment surface and a zone of CT on the abutment surface were apparent (toluidine blue/azure II staining; original magnification ×200).

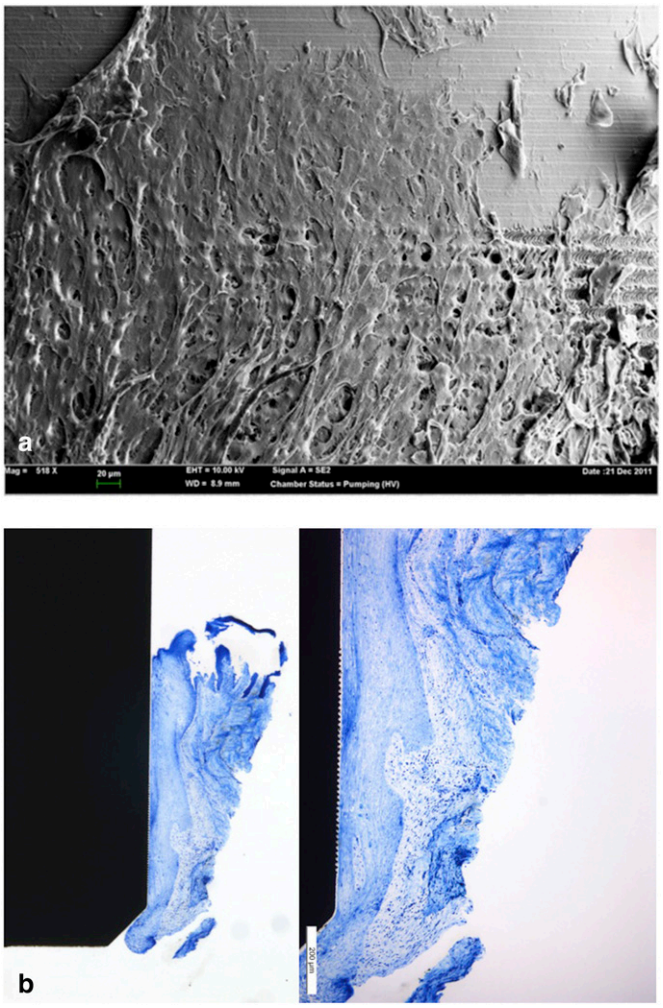

FIGURE 4a SEM of LL abutment 8 weeks after replacing ST abutment. Epithelium can be observed covering the LL surface. **4b** Histology of LL abutment 8 weeks after replacing ST abutment. Histology shows an epithelial zone adjacent to the abutment (toluidine blue/azure II staining; original magnification ×200).



FIGURE 5 SEM specimen of LL abutment 8 weeks after replacing ST abutment. Biofilm can be noted on the LL surface (toluidine blue/azure II staining; original magnification ×200).

SEM of a specimen harvested 8 weeks after an abutment switch from ST to LL and indicates areas of CT integration observed histologically. CT integration when the ST abutment was switched to an LL abutment was inconsistent, with few specimens demonstrating CT integration. When ST abutments were removed with a biopsy that removed soft tissue adjacent to the abutment, healing on the new LL abutment was similar to healing observed when LL was placed at the time of implant placement.

Healing of CT on LL Abutments Inserted After the Removal of LL Abutments

SEM and histology of a specimen harvested 8 weeks after switching from an LL to a new LL abutment is shown in Figure 6. A zone of epithelium adjacent to the abutment surface and a zone of CT on the abutment surface were evident. CT integration was consistently observed on 100% of

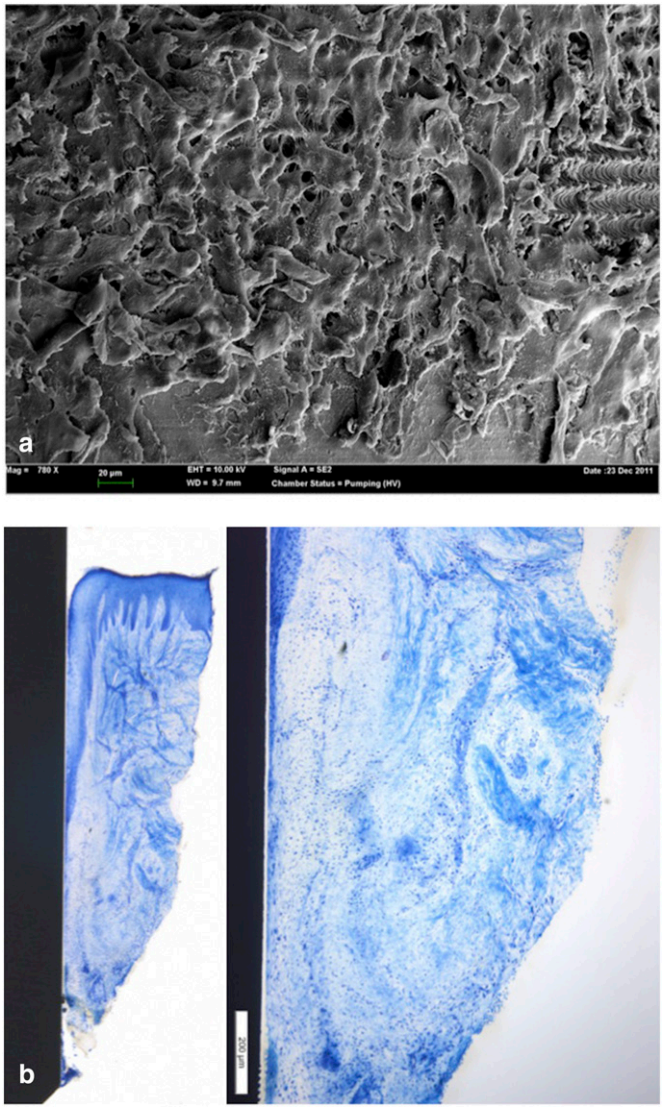

FIGURE 6a SEM of LL abutment 8 weeks after being switched from a previous LL abutment. Soft tissue integration is noted. **6b** Histology of LL abutment 8 weeks after being switched from a previous LL abutment. An epithelial zone and a CT zone on the abutment surface was observed (toluidine blue/azure II staining; original magnification ×200).

abutment surfaces. This was also observed in abutments in which soft tissue adjacent to the abutment was removed.

Discussion

Figure 7 presents the decision matrix to optimize CT healing on LL abutment surfaces. Healing of four different clinical scenarios was described. LL abutments were placed after implant placement and flap closure around the abutment. After an 8-week healing period, CT integration was observed in all specimens. CT integration on LL abutments was markedly different from healing that occurred around ST abutments placed in the same clinical scenario. Around ST abutments, an epithelial zone was noted, but no CT was found to be in contact with the implant surface.

CT integration found on LL abutment surfaces has been consistent with findings in previous studies in animals and humans.[10,15,16] Formation of the CT zone is proposed to be facilitated by inhibition of epithelial migration on the LL surface, providing an opportunity for CT to integrate with the LL surface.[7]

When ST abutments were removed and replaced with LL abutments, healing did not result in consistent formation of CT integration. It appears that when an epithelial zone was formed around an ST abutment, the LL surface did not have an opportunity to interact with CT. Healing was dictated by epithelium, and an epithelial zone was reestablished on the newly placed LL abutment.

When LL abutments replaced a previously placed LL abutment, CT integration was found consistently. It appears that disrupting integration that initially occurred allowed for CT to reintegrate with the abutment surface.

These findings have clinical significance in management of final abutment placement. When an ST abutment was placed at the time of implant placement and the final abutment was an LL abutment, epithelium needed to be removed to allow CT integration with a zone of CT on the abutment. Soft tissue facing the abutment may be de-epithelialized with either a diamond bur or surgical blade. With these techniques, care should be taken to prevent damage to the implant surface or surrounding soft tissue scaffold. A special tool could be developed for removal of the collar that would protect the implant surface and remove only the epithelial layer of the abutment sulcus.

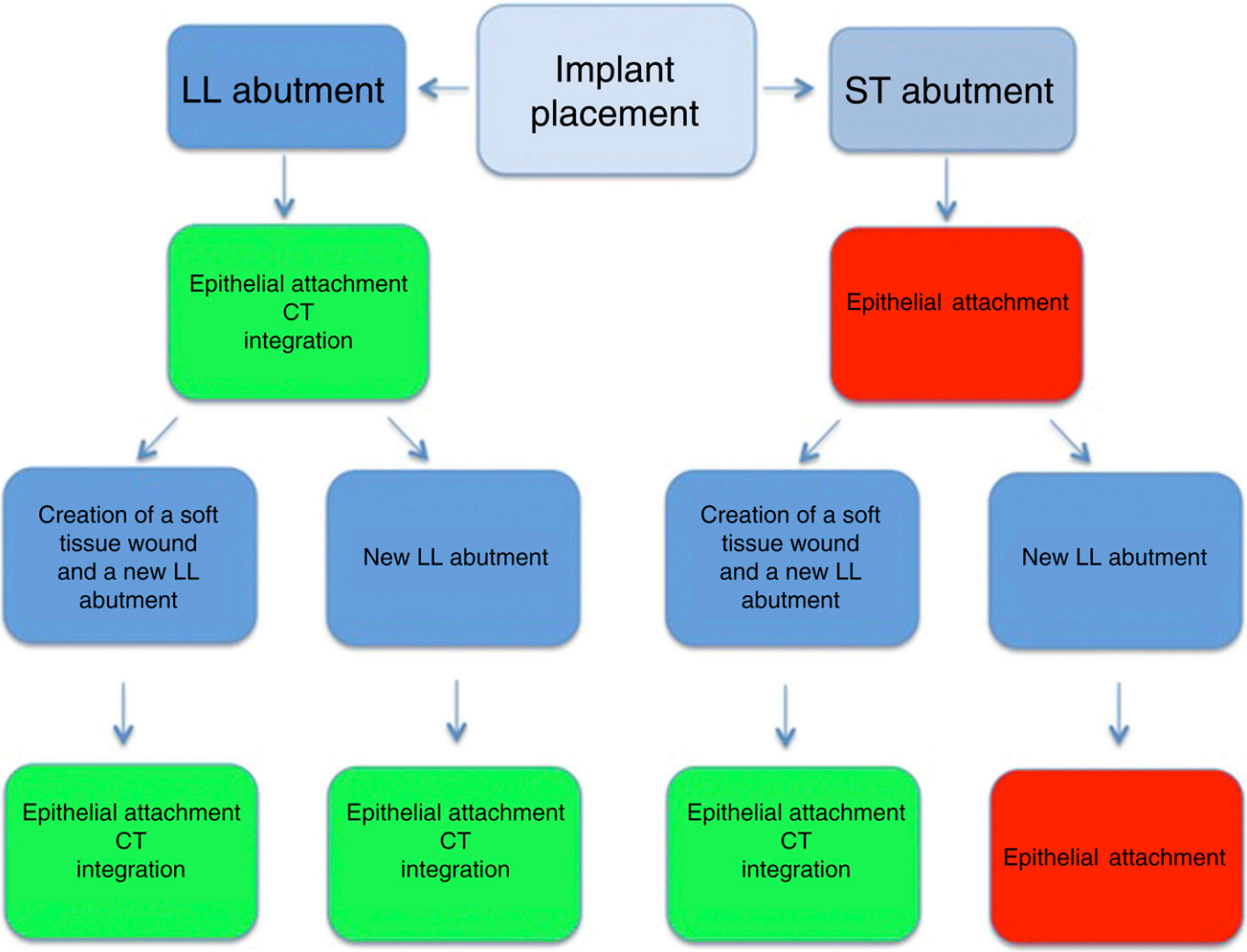

FIGURE 7 Decision matrix to optimize soft tissue integration onto LL abutments.

PDs around the natural adjacent teeth were less deep than measurements around implants with either type of abutment. This finding was supported by previous reports that found PD in general to be deeper around dental implants.[17,18]

PD measurements were similar for ST and LL abutments. Although a zone of CT integration was found surrounding LL abutments placed in the appropriate scenario, this was not reflected in PD data. The zone of laser-ablated surface on the LL abutments was only 0.7 mm and may have been too small to be measured given the inaccuracy of manual PD measurements around implants.[19] The CT zone may offer similar resistance to probing forces and therefore result in similar PD measurements.

No differences were found in plaque accumulation and inflammation around the teeth of the two abutment types. The healing period was short; during initial healing, patients were instructed to use chlorhexidine mouthrinse. Overall, teeth and implants were surrounded by healthy tissue, and patients were able to perform adequate oral hygiene measures. PI and GI are not very sensitive to small changes in plaque accumulation.

This was a short-term study of healing around abutments for two periods of 8 weeks. Long-term significance of the LL surface has not been established. In humans, implants with a laser-ablated microgrooved collar surface performed better than controls with a machined surface when comparing PDs and bone maintenance.[9,20-22] When combined with a beveled implant collar, bone healing and maintenance were found to be favorable in a canine study.[23]

Conclusions

Consistent CT integration was observed on LL abutment surfaces after implant placement. Switching LL abutments with new LL abutments consistently leads to CT integration. This was not consistent if an ST abutment was switched for an LL abutment. PI and GI were comparable between teeth and abutments. PD was lower around the teeth. There was no difference in PD between abutments.

The CT integration on LL abutments is optimized by initial healing occurring onto an LL abutment or creation of a CT wound before insertion of the abutment. Clinicians need to facilitate healing onto the LL surfaces by removing epithelium that would interface with the abutment surfaces. ■

Acknowledgments

This study was funded by BioHorizons Implant Systems (Birmingham, Alabama) for the authors to present the data at national meetings. Drs. Geurs and O'Neal have received lecture fees from BioHorizons. Dr. Geisinger has received salary and research support from BioHorizons, Straumann USA (Andover, Massachusetts), Zimmer Dental (Carlsbad, California), and DENTSPLY International (York, Pennsylvania). Ms. Haigh and Dr. Reddy report no conflicts of interest related to this study.

CORRESPONDENCE:
Dr. Nicolaas C. Geurs, University of Alabama at Birmingham, School of Dentistry, Department of Periodontology, 1720 2nd Ave. S., SDB 412, Birmingham, AL 35294-0007. E-mail: ngeurs@uab.edu.

References

1. Adell R, Lekholm U, Rockler B, Brånemark PI. A 15-year study of osseointegrated implants in the treatment of the edentulous jaw. *Int J Oral Surg* 1981;10:387-416.
2. Adell R, Eriksson B, Lekholm U, Brånemark PI, Jemt T. Long-term follow-up study of osseointegrated implants in the treatment of totally edentulous jaws. *Int J Oral Maxillofac Implants* 1990;5:347-359.
3. Wataha JC. Materials for endosseous dental implants. *J Oral Rehabil* 1996;23:79-90.
4. Lacefield WR. Current status of ceramic coatings for dental implants. *Implant Dent* 1998;7:315-322.
5. Hench LL, Wilson J. Surface-active biomaterials. *Science* 1984;226:630-636.
6. Ricci J, Charvet J, Frenkel S, et al. Bone response to laser microtextured surfaces. In: Davies JE, ed. *Bone Engineering*. Toronto: Em2; 2000:282-294.
7. Ricci JL, Grew JC, Alexander H. Connective-tissue responses to defined biomaterial surfaces. I. Growth of rat fibroblast and bone marrow cell colonies on microgrooved substrates. *J Biomed Mater Res A* 2008;85:313-325.
8. Weiner S, Simon J, Ehrenberg DS, Zweig B, Ricci JL. The effects of laser microtextured collars upon crestal bone levels of dental implants. *Implant Dent* 2008;17:217-228.
9. Pecora GE, Ceccarelli R, Bonelli M, Alexander H, Ricci JL. Clinical evaluation of laser microtexturing for soft tissue and bone attachment to dental implants. *Implant Dent* 2009;18:57-66.
10. Nevins M, Kim DM, Jun SH, Guze K, Schupbach P, Nevins ML. Histologic evidence of a connective tissue attachment to laser microgrooved abutments: A canine study. *Int J Periodontics Restorative Dent* 2010;30:245-255.
11. Mustafa K, Silva Lopez B, Hultenby K, Wennerberg A, Arvidson K. Attachment and proliferation of human oral fibroblasts to titanium surfaces blasted with TiO2 particles. A scanning electron microscopic and histomorphometric analysis. *Clin Oral Implants Res* 1998;9:195-207.
12. Cooper LF. Biologic determinants of bone formation for osseointegration: Clues for future clinical improvements. *J Prosthet Dent* 1998;80:439-449.
13. Hansson S, Norton M. The relation between surface roughness and interfacial shear strength for bone-anchored implants. A mathematical model. *J Biomech* 1999;32:829-836.
14. Nevins M, Nevins ML, Camelo M, Boyesen JL, Kim DM. Human histologic evidence of a connective tissue attachment to a dental implant. *Int J Periodontics Restorative Dent* 2008;28:111-121.
15. Nevins M, Camelo M, Nevins ML, Schupbach P, Kim DM. Connective tissue attachment to laser-microgrooved abutments: A human histologic case report. *Int J Periodontics Restorative Dent* 2012;32:385-392.
16. Geurs NC, Vassilopoulos PJ, Reddy MS. Histologic evidence of connective tissue integration on laser microgrooved abutments in humans. *Clin Adv Periodontics* 2011;1:29-33.
17. Brägger U, Bürgin WB, Hämmerle CH, Lang NP. Associations between clinical parameters assessed around implants and teeth. *Clin Oral Implants Res* 1997;8:412-421.
18. Karoussis IK, Müller S, Salvi GE, Heitz-Mayfield LJ, Brägger U, Lang NP. Association between periodontal and peri-implant conditions: A 10-year prospective study. *Clin Oral Implants Res* 2004;15:1-7.
19. Quirynen M, van Steenberghe D, Jacobs R, Schotte A, Darius P. The reliability of pocket probing around screw-type implants. *Clin Oral Implants Res* 1991;2:186-192.
20. Gopalakrishnan D, Joshi V, Romanos GE. Soft and hard tissue changes around laser microtexture single tooth implants — A clinical and radiographic evaluation. *Implant Dent* 2014;23:570-575.
21. Iorio-Siciliano V, Matarasso R, Guarnieri R, Nicolò M, Farronato D, Matarasso S. Soft tissue conditions and marginal bone levels of implants with a laser-microtextured collar: A 5-year, retrospective, controlled study. *Clin Oral Implants Res* 2015;26:257-262.
22. Linkevicius T, Puisys A, Svediene O, Linkevicius R, Linkeviciene L. Radiological comparison of laser-microtextured and platform-switched implants in thin mucosal biotype. *Clin Oral Implants Res* 2015;26:599-605.
23. Nevins M, Nevins M, Gobbato L, Lee HJ, Wang CW, Kim DM. Maintaining interimplant crestal bone height via a combined platform-switched, Laser-Lok implant/abutment system: A proof-of-principle canine study. *Int J Periodontics Restorative Dent* 2013;33:261-267.