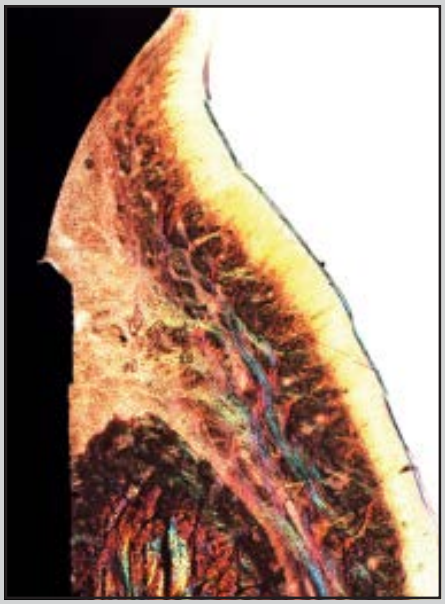

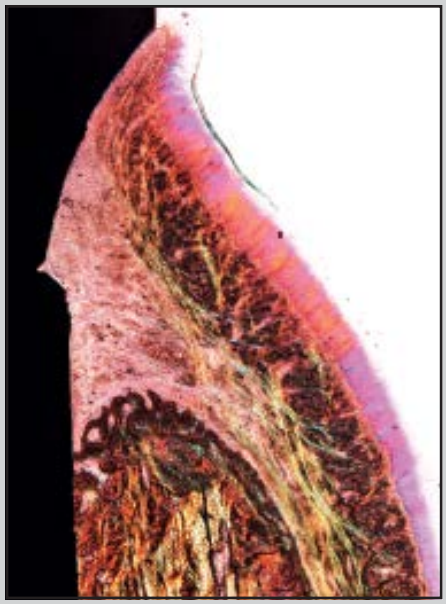

© 2016 BY QUINTESSENCE PUBLISHING CO, INC. PRINTING OF THIS DOCUMENT IS RESTRICTED TO PERSONAL USE ONLY.
NO PART MAY BE REPRODUCED OR TRANSMITTED IN ANY FORM WITHOUT WRITTEN PERMISSION FROM THE PUBLISHER.

Guidelines for Clinical Management of Laser-Etched (Laser-Lok) Abutments in Two Different Clinical Scenarios: A Preclinical Laboratory Soft Tissue Assessment Study



Rodrigo Neiva, DDS, MS[1]
Nick Tovar, PhD[2]
Ryo Jimbo, DDS, PhD[3]*/Luiz F. Gil, DDS, MS*[4]
Paula Goldberg, BS[2]*/Joao P.M. Barbosa, DDS*[2]
Thomas Lilin, DVM[5]*/Paulo G. Coelho, DDS, PhD*[6]

One-stage implants were placed in the mandibles of eight beagle dogs with laser-etched (LL) and machined abutments. After 4 weeks, half of the LL abutments were disconnected and reconnected after 10 minutes of saline storage, and the other half were replaced with a new LL abutment (impression simulation) with or without sulcus de-epithelialization. After abutment change, systems remained in vivo for 3 weeks. Results showed that LL abutments can be reconnected and that sulcus scoring prior to LL placement of one-stage implants receiving machined abutments may be beneficial. Int J Periodontics Restorative Dent 2016;36:339–345. doi: 10.11607/prd.2773

[1]Associate Professor, Department of Periodontology, University of Florida College of Dentistry, Gainesville, Florida, USA.
[2]Adjunct Professor, Department of Biomaterials and Biomimetics, New York University College of Dentistry, New York, New York, USA.
[3]Associate Professor, Department of Oral and Maxillofacial Surgery, Malmo University, Malmo, Sweden.
[4]Instructor, Department of Dentistry, Division of Oral and Maxillofacial Surgery, Federal University of Santa Catarina, Florianopolis, Santa Catarina, Brazil.
[5]Director, Department of Experimental Surgery, École Nationale Vétérinaire d'Alfort, Maisons-Alfort, France.
[6]Associate Professor of Biomaterials and Biomimetics, New York University College of Dentistry, New York, New York, USA.

Correspondence to: Dr Paulo G. Coelho, New York University College of Dentistry, 433 1st Ave, Room 844, New York, NY 10010, USA.
Email: pgcoelho@nyu.edu

©2016 by Quintessence Publishing Co Inc.

Laser-etched (LL) dental implants have been used in routine clinical practice for a number of years. More recently, this implant surface modification has been applied to healing and final restorative abutments.[1–4] The foundation for the use of such technology even for the soft tissue is based on a series of preclinical[3–5] and clinical studies[6–9] that unequivocally show establishment of unique soft tissue morphology during healing, leading to an improved soft tissue seal and consequent reduced peri-implant bone loss due to prevention of apical epithelium migration.

While the clinical application of the laser-abraded abutment is well accepted, there is a lack of sufficient evidence with regard to its optimal clinical usage and its optimal structure. Whether the surface treatment should be located at the cervical aspect of the implant body or the base of the healing and final restorative abutments has yet to be defined. For instance, it has been demonstrated in preclinical canine studies that use of the LL treatment on the base of the healing abutment resulted in an advanced coronal positioning of the junctional epithelium.[3,4] Based on this, the effects of the subsequent clinical procedures after the initial soft tissue healing must be considered. A clinical question remains as to whether the same

© 2016 BY QUINTESSENCE PUBLISHING CO, INC. PRINTING OF THIS DOCUMENT IS RESTRICTED TO PERSONAL USE ONLY.
NO PART MAY BE REPRODUCED OR TRANSMITTED IN ANY FORM WITHOUT WRITTEN PERMISSION FROM THE PUBLISHER.

LL-treated healing abutment can be reconnected after impression-taking procedures or a pristine LL-treated healing abutment should be connected afterward to reestablish soft tissue attachment to the base of the healing abutment. Another clinical scenario involves the influence of the LL treatment on soft tissue healing if standard smooth abutments were initially connected and then, after their removal (due to impression taking, for example), LL-treated abutments were connected.

Thus, the objective of this preclinical study was to address the following clinically relevant questions with regard to the use of LL abutments:

1. Should a new LL abutment be used after a one-stage LL abutment is removed for impression purposes?
2. Can clinicians benefit from the installation of LL restorative abutments after initial healing has taken place around traditional smooth healing abutments?
3. Is it necessary to de-epithelialize the healed sulcus before connecting abutments with LL surfaces to promote connective tissue attachment in a more coronal position?

Materials and methods

For the laboratory preclinical in vivo model, eight adult male beagle dogs approximately 1.5 years old were acquired, after the approval of the Ethics Committee for Animal Research at École Nationale Veterinaire D'Alfort. The animals were housed for a period of 2 weeks for acclimation prior to surgical procedures. All surgical procedures were conducted under general anesthesia as previously described.[10] Bilateral extractions of the mandibular molars were performed. Buccal and lingual full-thickness mucoperiosteal flaps were elevated, followed by teeth sectioning in a buccolingual direction, allowing for nontraumatic individual root extractions by means of root elevators and extraction forceps. Approximation of the flaps was achieved through standard suturing techniques and the extraction sites were allowed to heal for 8 weeks. For this study, two different sequences were used and are presented in Fig 1.

All implants used in the study were 3.8 mm in diameter and 10.5 mm in length. Seven weeks prior to euthanasia, one tapered internal connection LL cervical + resorbable blast surface texture (RBT) implant (TLX) (BioHorizons) and one tapered internal connection without LL cervical with RBT surface treated in its entire length (TMR) (BioHorizons) were placed on each side of the mandible in a split-mouth fashion. A total of four implants were placed in each dog (16 TLX and 16 TMR). Following the single-stage protocol, TLX and TMR implants received LL and smooth abutments, respectively (Fig 1).

After 4 weeks of healing, the abutments of both TLX implants were removed. The right side abutment was returned to its implant after being kept for 10 minutes in a saline solution (elapsed time of a typical impression), and a new LL abutment was installed on the left side implant. Both smooth abutments were removed from the TMR implants and replaced with LL abutments, with the left side receiving no sulcus treatment and the right side sulcus being de-epithelialized (Fig 1). Three weeks later, the animals were sacrificed by anesthesia overdose. The implants in soft tissue and bone were then nondecalcified and processed for histology as previously described.[11,12] The sections were then stained using Stevenel's blue and van Gieson's picrofuchsin and were referred to optical microscopy. The histologic samples were evaluated at ×50 to ×200 magnification (Leica DM2500 M, Leica) and high-resolution micrographs were obtained through a digital scanner (Aperio, Leica). Soft tissue evaluation around the implant/abutment regions was performed and quantified according to the position of the most apical component of the junctional epithelium at both lingual and buccal flanges as follows:

1. Most apical component of junctional epithelium coronal to abutment LL region (Fig 2a)
2. Most apical component of junctional epithelium positioned within abutment LL region (Fig 2b)
3. Most apical component of junctional epithelium positioned at or below the implant-abutment gap (Fig 2c)

For statistical analysis, positive and negative outcomes were computed. An outcome was considered

© 2016 BY QUINTESSENCE PUBLISHING CO, INC. PRINTING OF THIS DOCUMENT IS RESTRICTED TO PERSONAL USE ONLY.
NO PART MAY BE REPRODUCED OR TRANSMITTED IN ANY FORM WITHOUT WRITTEN PERMISSION FROM THE PUBLISHER.

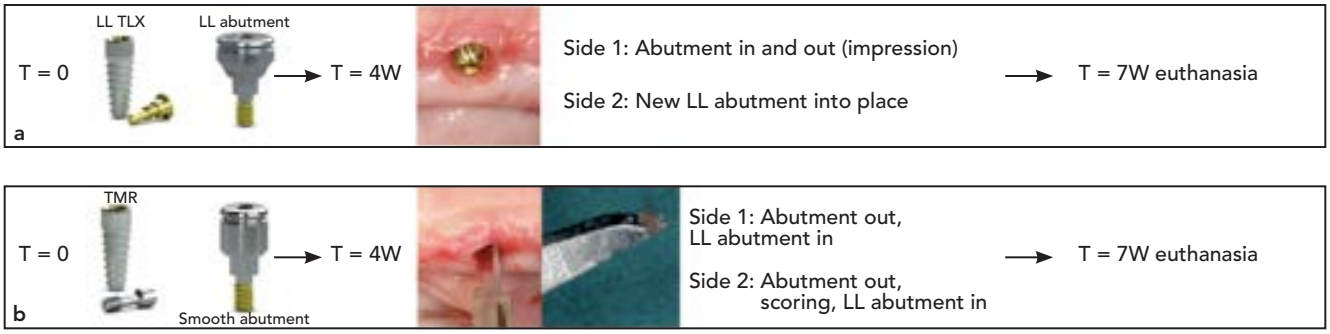

Fig 1 (a) *Impression simulation study arm sequence.* (b) *Sulcus treatment after placement of smooth healing abutment study arm.*

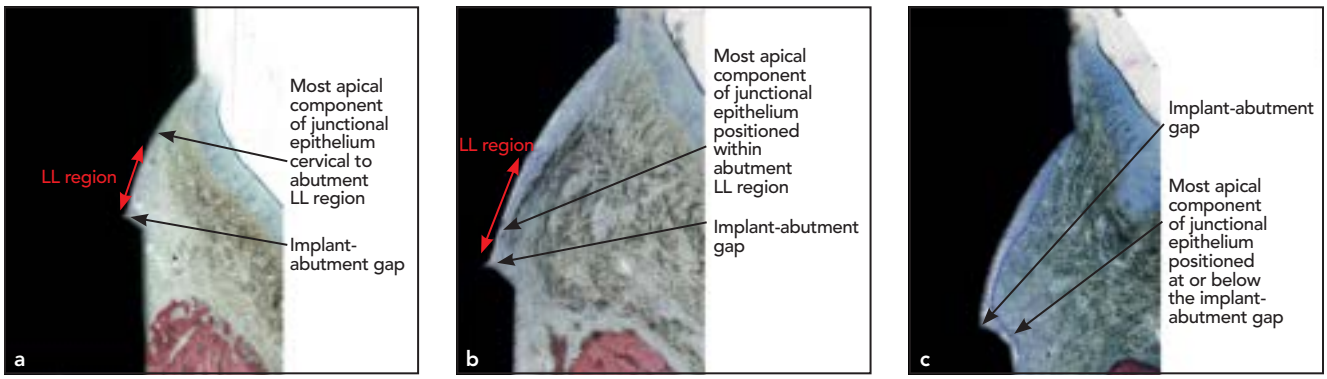

Fig 2 *Soft tissue evaluation around the implant-abutment region was performed and quantified according to the position of the most apical component of the junctional epithelium at both lingual and buccal flanges.* (a) *Most apical component of junctional epithelium coronal to LL region.* (b) *Most apical component of junctional epithelium positioned within LL region.* (c) *Most apical component of junctional epithelium positioned at or below the implant-abutment gap.*

positive if the most apical position of the junctional epithelium was observed coronal to or within the LL region and negative when the junctional epithelium was positioned at or below the implant-abutment gap. If no negative outcomes were observed when two groups were compared, a direct comparison between the number of instances where the most apical position of the junctional epithelium was above or within the LL region was performed. Following determination and quantification of junctional epithelium cumulative positive and negative outcomes for all implants at both buccal and lingual flanges as well as for all observations over both flanges, statistical analysis was performed by multiple Yates corrected chi-square tests with $\alpha = .05$.

Results

Postoperative clinical assessment showed uneventful soft tissue healing around the healing abutments after installation. Clinical evaluation 1 week after both surgical interventions showed no signs of inflammation or infection despite the absence of plaque control measures.

The histograms presenting positive and negative junctional epithelium position outcomes for the buccal and lingual flanges combined, for the buccal flange alone, and for the lingual flange alone are presented in Figs 3 and 4.

Figure 3 depicts the positive and negative outcomes for the sites where impression simulation was conducted. Negative outcomes were only observed around implants that had the existing healing abutments replaced by new ones. Statistical analysis showed no significant difference whether buccal and lingual flanges were analyzed together or individually (all $P > .28$).

Figure 4 depicts the outcomes for implants that had smooth abutments replaced by LL abutments with and without sulcus epithelial scoring. Since this group did not

© 2016 BY QUINTESSENCE PUBLISHING CO, INC. PRINTING OF THIS DOCUMENT IS RESTRICTED TO PERSONAL USE ONLY.
NO PART MAY BE REPRODUCED OR TRANSMITTED IN ANY FORM WITHOUT WRITTEN PERMISSION FROM THE PUBLISHER.

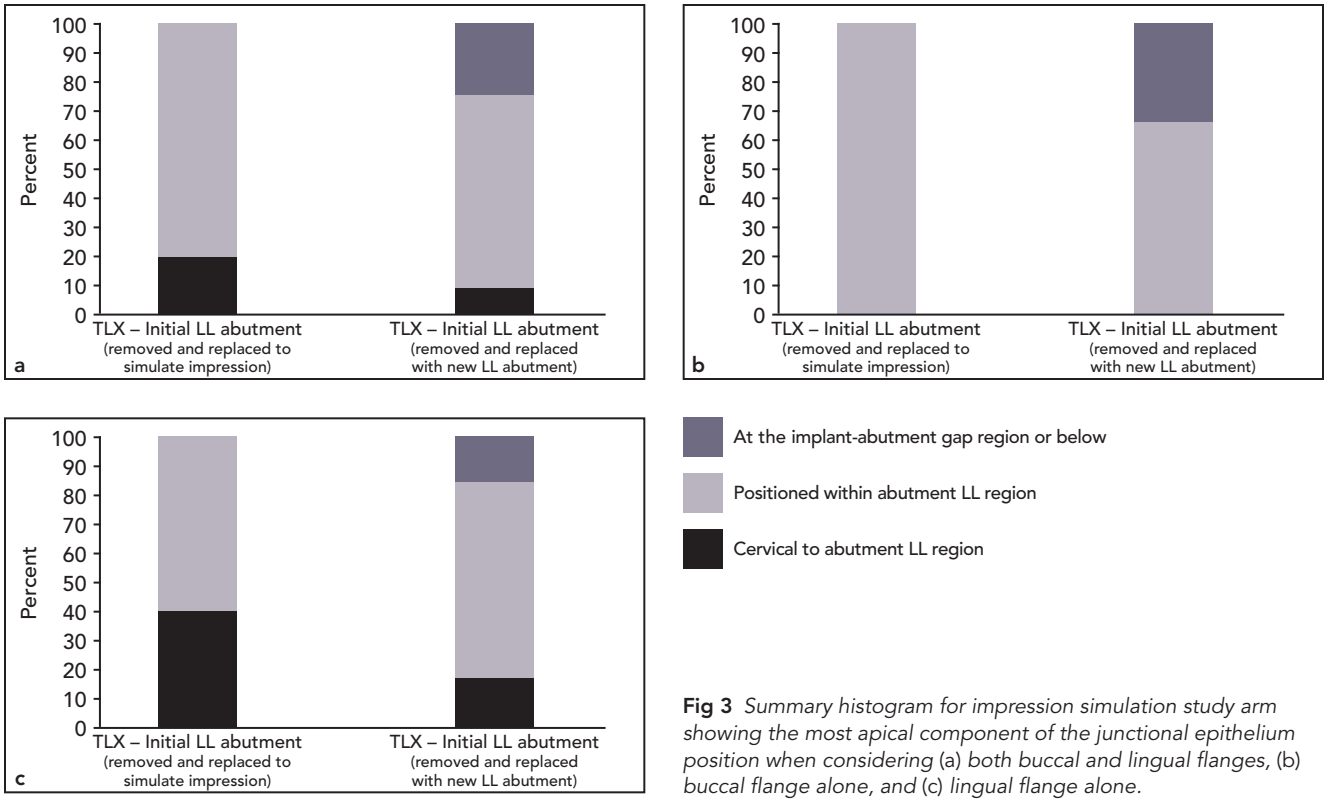

Fig 3 *Summary histogram for impression simulation study arm showing the most apical component of the junctional epithelium position when considering* (a) *both buccal and lingual flanges,* (b) *buccal flange alone, and* (c) *lingual flange alone.*

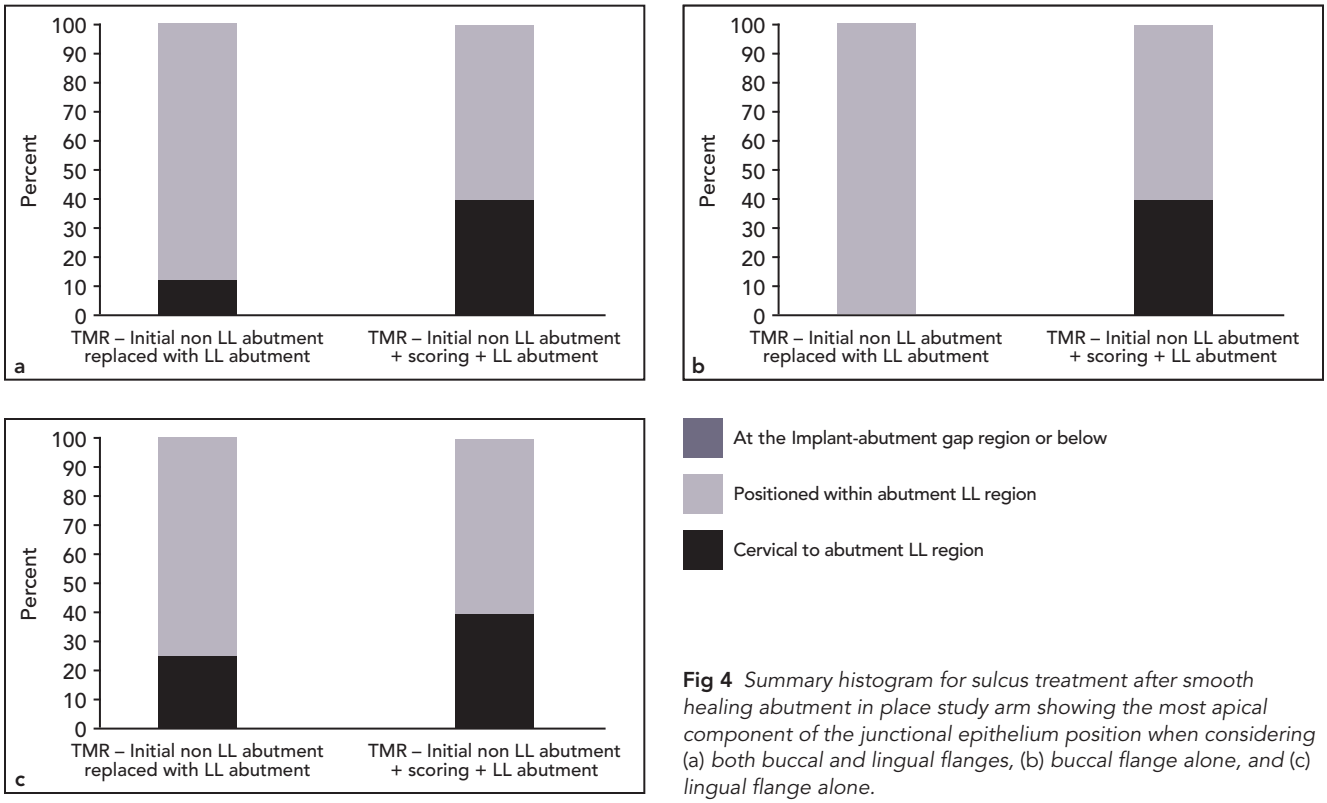

Fig 4 *Summary histogram for sulcus treatment after smooth healing abutment in place study arm showing the most apical component of the junctional epithelium position when considering* (a) *both buccal and lingual flanges,* (b) *buccal flange alone, and* (c) *lingual flange alone.*

© 2016 BY QUINTESSENCE PUBLISHING CO, INC. PRINTING OF THIS DOCUMENT IS RESTRICTED TO PERSONAL USE ONLY.
NO PART MAY BE REPRODUCED OR TRANSMITTED IN ANY FORM WITHOUT WRITTEN PERMISSION FROM THE PUBLISHER.

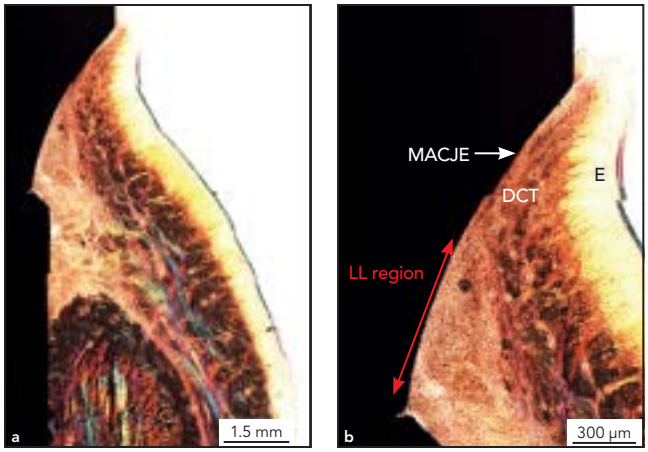

Fig 5 (a) *Survey and* (b) *higher magnification circularly polarized optical micrographs depicting the most apical component of the junctional epithelium (MACJE) positioned above the LL region. No parallel connective tissue fibers were observed. Occasional perpendicularly oriented connective tissue fibers were observed in proximity with the LL region, but in most cases the connective tissue between the implant-abutment and gingival dense connective tissue layer (DCT) and epithelium (E) had an immature, nonorganized appearance. This lack of organization was probably the result of the 3-week healing period, which did not allow reorganization of perpendicular collagen fibers observed below the microgaps of LL implants, where the soft tissue had not been disrupted.*

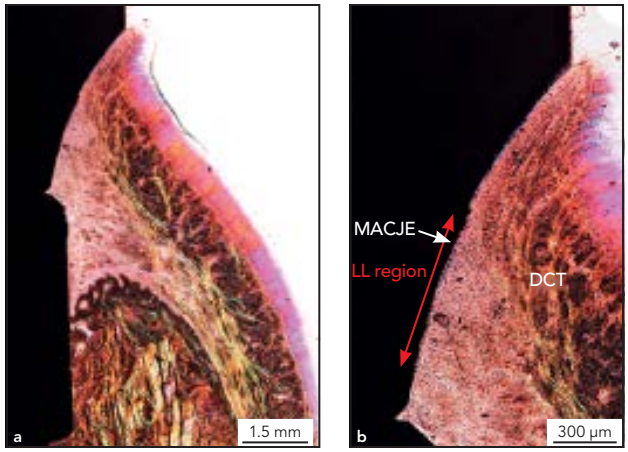

Fig 6 (a) *Survey and* (b) *higher magnification circularly polarized optical micrographs depicting the most apical component of the junctional epithelium (MACJE) positioned within the upper half of the LL region. No parallel connective tissue fibers were observed in proximity with the implant and abutment, and occasional perpendicularly oriented connective tissue fibers were observed in proximity with the laser-etched abutment region. In most cases the connective tissue between the implant-abutment and gingival dense connective tissue layer (DCT) and epithelium had an immature, nonorganized appearance. This lack of organization was probably the result of the 3-week healing period.*

present negative outcomes, the number of instances where the most apical component of the junctional epithelium was positioned above (best case scenario) or within (positive scenario) the LL abutment region was analyzed. Statistical analysis showed no significant differences when buccal and lingual flanges were analyzed individually (both $P > .4$). When buccal and lingual flanges were collapsed, a borderline significant difference occurred favoring outcomes for the implants that received LL abutments after sulcus scoring ($P = .055$).

Irrespective of implant type and experimental group, tissue morphology was consistent with noninflamed tissue, presenting a connective tissue layer without inflammatory infiltrate underlying a parakeratinized epithelial layer. The parakeratinized tissue presented basal and spinous layers, no granular layer, and keratin cells presenting nuclei. A notable morphologic difference was noted, however, when the junctional epithelium was positioned above the LL region. In these regions, no parallel connective tissue fibers were observed, and occasional perpendicularly oriented connective tissue fibers were observed in proximity with the LL region, but in most cases the connective tissue had an immature, nonorganized appearance (Fig 5). This lack of organization was probably the result of the 3-week healing period, which did not allow the reorganization of perpendicular collagen fibers that were observed below the microgaps of LL implants where the soft tissue had not been disrupted (Fig 5). A similar histomorphology was also observed for LL abutment implants where the most apical junctional epithelium was observed within the upper half of the LL region (Fig 6). When the most apical component of the junctional epithelium was at or below the implant-abutment gap, dense fibrous connective tissue was observed migrating apically in parallel orientation along with the junctional epithelium irrespective of implant system and abutment group (Fig 7).

Discussion

The stability of the peri-implant seal has been shown to be negatively influenced by unstable implant-abutment connections leading to

© 2016 BY QUINTESSENCE PUBLISHING CO, INC. PRINTING OF THIS DOCUMENT IS RESTRICTED TO PERSONAL USE ONLY.
NO PART MAY BE REPRODUCED OR TRANSMITTED IN ANY FORM WITHOUT WRITTEN PERMISSION FROM THE PUBLISHER.

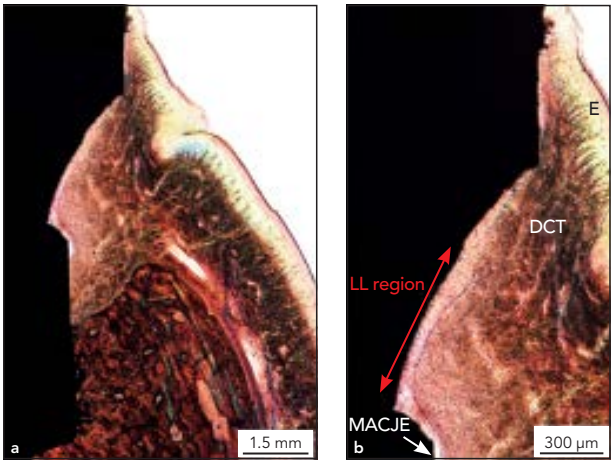

Fig 7 (a) *Survey and* (b) *higher magnification circularly polarized optical micrographs depicting the most apical component of the junctional epithelium (MACJE) positioned below the LL region. Dense fibrous connective tissue (DCT) was observed migrating apically in parallel orientation with the junctional epithelium and gingival epithelium (E).*

abutment micromovement during function,[13–15] as well as by creation of a favorable environment for the colonization and proliferation of anaerobic bacteria.[16–21] The type of soft tissue attachment and consequent formation of the peri-implant soft tissue seal to titanium that prevent apical migration of the junctional epithelium have been considered the most significant predisposing factors related to peri-implant bone loss in the presence of inflammation or injury.[5,17]

The lack of connective tissue fiber insertion seen in traditional implant abutments, especially in cervical regions, naturally limits soft tissue adhesion to their surface.[3] Soft tissue attachment takes place via hemidesmosomal and basal lamina and formation of a long junctional epithelium, which creates a less-than-ideal barrier for bacteria and inflammation. This is one of the biologic reasons the peri-implant bone underneath resorbs, since the bone tries to maintain its distance from the inflamed soft tissue layer. Hence, a titanium abutment surface modification that could promote not only a more stable epithelial attachment but also physical attachment through connective tissue fiber insertion into either the implant cervical region or the base of the abutment should lead to a more stable and protective peri-implant soft tissue seal and subsequent maintenance of peri-implant crestal bone levels. The LL surface has been shown to create apical soft tissue attachment and minimize crestal bone loss in preclinical studies,[3–5] and clinical evidence[6–9] has shown that such technology assists in preventing the onset of peri-implantitis.[5,22] Moreover, in promoting soft tissue integration, such technology naturally promotes enhanced esthetic outcomes.[1,4,23] However, the ideal timing for its application has not been properly determined, since the peri-implant crevice starts to form as soon as the implant is exposed to the oral cavity.

The aim of the present study was to evaluate whether LL healing abutments connected to implants at the time of implant placement should be replaced with new healing abutments after the impression procedures to maintain the quality of the peri-implant soft tissue seal. The results clearly suggest that when these LL abutments are disconnected and kept in a saline solution during impression procedures, they can be reused without compromise to the integrity of the peri-implant soft tissue seal. Since the differences were comparable when a new LL-treated healing abutment was used, it may be suggested that the peri-implant soft tissue seal that was developed using LL healing abutments could be transferred to final restorative abutments that would mimic the macro- and microarchitecture of the LL healing abutment used following implant placement.

Another aim of this study was to determine whether this biomimetic peri-implant seal could be established after the implant was allowed to heal in association with standard smooth surface healing abutments, and if de-epithelializing (scoring) the crevice would be necessary to promote the formation of

© 2016 BY QUINTESSENCE PUBLISHING CO, INC. PRINTING OF THIS DOCUMENT IS RESTRICTED TO PERSONAL USE ONLY.
NO PART MAY BE REPRODUCED OR TRANSMITTED IN ANY FORM WITHOUT WRITTEN PERMISSION FROM THE PUBLISHER.

an enhanced peri-implant soft tissue seal. The results demonstrated that scoring the sulcular epithelium prior to placement of LL healing or final restorative abutments leads to overall superior soft tissue attachment to the abutment surface.

Conclusions

Despite the limitations of this study, it can be concluded that healing abutments with LL surfaces can be reconnected after prosthetic procedures such as impression taking if they are kept in a saline solution. In addition, implants allowed to heal with standard smooth abutments would benefit from scoring of the sulcus prior to connection of LL healing or final restorative abutments. Finally, the most apical position of the junctional epithelium was found to be coronal to the LL abutment surfaces in most instances regardless of clinical sequence.

Acknowledgments

The present study was partially funded by Biohorizons, USA. The authors reported no conflicts of interest related to this study.

References

1. Guarnieri R, Belleggia F, Grande M. Immediate versus delayed treatment in the anterior maxilla using single implants with a laser-microtextured collar: 3-year results of a case series on hard- and soft-tissue response and esthetics. J Prosthodont 2016;25:135–145.
2. Linkevicius T, Puisys A, Svediene O, Linkevicius R, Linkeviciene L. Radiological comparison of laser-microtextured and platform-switched implants in thin mucosal biotype. Clin Oral Implants Res 2015;26:599–605.
3. Nevins M, Kim DM, Jun SH, Guze K, Schupbach P, Nevins ML. Histologic evidence of a connective tissue attachment to laser microgrooved abutments: A canine study. Int J Periodontics Restorative Dent 2010;30:245–255.
4. Nevins M, Nevins M, Gobbato L, Lee HJ, Wang CW, Kim DM. Maintaining interimplant crestal bone height via a combined platform-switched, Laser-Lok implant/abutment system: A proof-of-principle canine study. Int J Periodontics Restorative Dent 2013;33:261–267.
5. Nevins M, Nevins ML, Camelo M, Boyesen JL, Kim DM. Human histologic evidence of a connective tissue attachment to a dental implant. Int J Periodontics Restorative Dent 2008;28:111–121.
6. Farronato D, Mangano F, Briguglio F, Iorio-Siciliano V, Riccitiello F, Guarnieri R. Influence of Laser-Lok surface on immediate functional loading of implants in single-tooth replacement: A 2-year prospective clinical study. Int J Periodontics Restorative Dent 2014;34:79–89.
7. Gopalakrishnan D, Joshi V, Romanos GE. Soft and hard tissue changes around laser microtexture single tooth implants--a clinical and radiographic evaluation. Implant Dent 2014;23:570–575.
8. Pecora GE, Ceccarelli R, Bonelli M, Alexander H, Ricci JL. Clinical evaluation of laser microtexturing for soft tissue and bone attachment to dental implants. Implant Dent 2009;18:57–66.
9. Shapoff CA, Lahey B, Wasserlauf PA, Kim DM. Radiographic analysis of crestal bone levels around Laser-Lok collar dental implants. Int J Periodontics Restorative Dent 2010;30:129–137.
10. Teixeira HS, Marin C, Witek L, et al. Assessment of a chair-side argon-based non-thermal plasma treatment on the surface characteristics and integration of dental implants with textured surfaces. J Mech Behav Biomed Mater 2012;9:45–49.
11. Tovar N, Jimbo R, Marin C, et al. Bone regeneration around implants placed in fresh extraction sockets covered with a dual-layer PTFE/collagen membrane: An experimental study in dogs. Int J Periodontics Restorative Dent 2014;34:849–855.
12. Jimbo R, Anchieta R, Baldassarri M, et al. Histomorphometry and bone mechanical property evolution around different implant systems at early healing stages: An experimental study in dogs. Implant Dent 2013;22:596–603.
13. Nevins M, Camelo M, Nevins ML, Schupbach P, Kim DM. Reattachment of connective tissue fibers to a laser-microgrooved abutment surface. Int J Periodontics Restorative Dent 2012;32:e131–e134.
14. Nevins M, Camelo M, Nevins ML, Schupbach P, Kim DM. Connective tissue attachment to laser-microgrooved abutments: A human histologic case report. Int J Periodontics Restorative Dent 2012;32:385–392.
15. Nevins ML, Camelo M, Schupbach P, Kim SW, Kim DM, Nevins M. Human clinical and histologic evaluation of laser-assisted new attachment procedure. Int J Periodontics Restorative Dent 2012;32:497–507.
16. Ericsson I, Persson LG, Berglundh T, Marinello CP, Lindhe J, Klinge B. Different types of inflammatory reactions in peri-implant soft tissues. J Clin Periodontol 1995;22:255–261.
17. Hermann JS, Buser D, Schenk RK, Higginbottom FL, Cochran DL. Biologic width around titanium implants. A physiologically formed and stable dimension over time. Clin Oral Implants Res 2000;11:1–11.
18. Duyck J, Vandamme K. The effect of loading on peri-implant bone: A critical review of the literature. J Oral Rehabil 2014;41:783–794.
19. Hsu YT, Mason SA, Wang HL. Biological implant complications and their management. J Int Acad Periodontol 2014;16:9–18.
20. Pellegrini G, Canullo L, Dellavia C. Histological features of peri-implant bone subjected to overload [epub ahead of print 19 March 2015]. Ann Anat. doi: 10.1016/j.aanat.2015.02.011.
21. Renvert S, Polyzois I, Persson GR. Treatment modalities for peri-implant mucositis and peri-implantitis. Am J Dent 2013;26:313–318.
22. Nevins M. What are the implications of peri-implantitis? Int J Periodontics Restorative Dent 2015;35:451.
23. Guarnieri R, Placella R, Testarelli L, Iorio-Siciliano V, Grande M. Clinical, radiographic, and esthetic evaluation of immediately loaded laser microtextured implants placed into fresh extraction sockets in the anterior maxilla: A 2-year retrospective multicentric study. Implant Dent 2014;23:144–154.

© 2016 BY QUINTESSENCE PUBLISHING CO, INC. PRINTING OF THIS DOCUMENT IS RESTRICTED TO PERSONAL USE ONLY.
NO PART MAY BE REPRODUCED OR TRANSMITTED IN ANY FORM WITHOUT WRITTEN PERMISSION FROM THE PUBLISHER.