JOURNAL of
OSSEOINTEGRATION

M. GRANDE[1], A. CECCHERINI[2], M. SERRA[3], L. BAVA[4], D. FARRONATO[5], V. IORIO SICILIANO[6], R. GUARNIERI[7]

[1] Private Implant Practice Rome, Italy
[2] MD DDS, Implant Private Practice, Florence, Italy
[3] MD DDS, Private Implant Practice, Turin, Italy
[4] MD DDS, Private implant Practice, Turin, Italy
[5] DDs, PhD, PD, Department of Biomaterial Sciences, Insubria University, Varese, Italy
[6] DDS, PhD, Department of Periodontology, University of Naples Federico II, Naples, Italy
[7] MD, DDS, Freelance Researcher, SCS Scientific Consulting Services, Rome, Italy

Immediate occlusal loading of Tapered Internal Laser-Lok® implants in partial arch rehabilitations: a 24-months clinical and radiographic study

TO CITE THIS ARTICLE
Grande M, Ceccherini A, Serra M, Bava L, Farronato D, Iorio Siciliano V, Guarnieri R. Immediate occlusal loading of Tapered Internal Laser-Lok implants in partial arch rehabilitations: a 24-months clinical and radiographic study. J Osseointegr 2013;5(2):53-60.

ABSTRACT

Aim The purpose of this 2 year prospective clinical study was to clinically and radiographically evaluate an implant with laser microtextured collar surface placed for immediate loading of fixed prostheses in cases of partial posterior maxillary and/or mandibular edentulism.

Materials and methods Thirty-five partially edentulous patients who needed implant treatment and met inclusion criterias were consecutively enrolled at different study-centers in Italy. A total of 107 Tapered Internal Laser-Lok® implants (49 maxillary and 58 mandibular) were placed and immediately loaded. All provisional constructions were delivered within 1 hour, and the final constructions placed after 4 months. A total of 107 Tapered Internal Laser-Lok implants (49 maxillary and 58 mandibular) were placed and immediately loaded. All provisional restorations were delivered within 1 hour, and the final prosthesis placed after 4 months. A total of 32 prosthetic restorations, consisting of 10 two- units, 12 three-units, and 10 four-units fixed partial dentures were evaluated. Clinical and radiographic outcomes were monitored at follow-up examinations scheduled 6, 12, 24 months after implants placement.

Results Five implants were lost after loading (3 implants in a two-unit maxillary restorations, 1 implant in a two-unit mandibular restorations, and 1 implant in three-unit maxillary restorations)giving a survival rate of 95.4% after 24 months. Mean crestal bone loss at 6, 12, and 24 months after implant insertion was 0.42 +/- 1.1 mm, 0.52 +/- 0.9 mm, and 0.66 +/- 1.3 mm, respectively.

Conclusion Although limited bytheshort follow-up, immediate function with Tapered Internal Laser-Lok® implants seems to be a viable option to treat partially edentulous patients.

KEYWORDS Crestal bone loss; Immediate functional loading; Laser-Lok® microtextured collar surface.

INTRODUCTION

During the past decade, techniques of immediate and early loading of dental implants have gradually gained popularity (1). The rehabilitation of partially edentulous patients with immediately loaded standard diameter implants, in cases where suitable bone volume and quality is present, has been described by many authors (2-11). Various definitions for immediate or early implant loading can be found in the scientific literature (12). When the applied load is reduced, it may also be correct to use the term "immediate/early function" rather than "immediate/early loading" (13). Different publications have shown that with attention to specific factors, implant survival with immediate restoration in partially edentulous segments was comparable to the results of conventional protocols (14, 15). Factors that influence the outcomes of implant immediate loading can be divided into 4 categories (15) as follows.

- Surgery-related factors, pertaining to primary implant stability and a non-traumatic surgical technique.
- Host-related factors, pertaining to bone quantity and quality (density) and proper bone healing environment.
- Implant-related factors, pertaining to the influence of macro- (thread) and micro- (surface coating) structure of the implant.
- Occlusion-related factors, pertaining to the importance of occlusal forces and prosthetic design.

Implant primary stability has been identified by many authors as one of most important clinical factors influencing success of immediate loading (15-18),

because transmission of micro-movements to the implant body can cause crestal bone loss or failure of osseointegration. The literature data (19) suggest that the critical micro-movements threshold above which fibrous encapsulation prevails over osseointegration, lies somewhere between 50 and 150 µ.
Beside from bone density, primary stability seems to be related to the surgical technique (underpreparation of the site) and particularly to the geometry of the implant. Experimental data (20) reporting the initial implant stability by the insertion torque and the resonance frequency, showed that the positioning of slightly tapered fixture in a cylindrical site gives a greater stability compared to cylindrical implants. Furthermore, clinical studies documented that tapered implant's survival rate in soft bone was higher than the one obtained with cylindrical implants (21, 22).
Bone quantity and bone quality are also important determinants with a major influence on immediate loading protocols (23). Traditionally, a good quality bone is a dense, cortical bone which allows fixture primary stability preventing micro-movements due to its strength and elevated mineral component (24). Torque measurements have been shown to reflect bone density (25, 26), and the clinical assessment of stability is often based on torque resistance measurements at the time of implant placement. An insertion torque value from 30 to 40 Ncm before the implant is finally seated is considered a sufficient value indicating the required stability for success (27-31).
Although implant surface characteristics do not seem to play an important role in primary stability achievement nor influence it, it is essential for the acceleration of the osseointegration process (20, 21, 32). It is generally acknowledged that rough surface implants usually have better success rates when compared to smooth surface fixtures (33). Due to this, in recent years, implant manufacturers have progressively abandoned smooth surface machined implants for rough/treated surfaces. However, it has been noticed that when the microstructure (or surface coating) of an implant was assessed in relation to immediate implant loading, neither animal nor human studies have shown significant differences in implant success regardless of which type of surface coating was used (34-36).
The majority of studies showed that occlusal disorder is a contraindication for immediate loading (37-39)and "maximum interocclusal contact without any lateral contact" is the recommended occlusal scheme which an immediate loaded implant restoration should receive (33).
Prosthetic design and surgical planning are other factors of great importance in immediate loading protocol. Several studies showed that adequate implant position, parallelism among fixtures, and splinting of the implants in case of multiple implant restorations can decrease the risk of overloading to each implant because of the greater surface area and better biomechanical distribution of the applied forces (40-42).
Using the principles of tissue engineering, recently some strategies have been developed, in an effort to improve hard and soft tissue integration and to prevent crestal bone loss which may be beneficial in immediate loading. Laser-microtexturing of surfaces is one of them. Tissue culture studies have demonstrated osteoblast and fibroblast cellular attachment to laser-microgrooved surfaces (43,44), as well as histological studies have proved connective tissue fibers attachment to Laser-Lok® microtexturing surface of implants and abutments (45, 46). The first clinical data presented (47, 48) show that implants with laser-microtexuted collar surface reduced crestal bone loss and probing depth (PD) when compared to machined-collar-implants; however the biological and clinical impact of this novel kind of laser microtxtured implant collar surface has not yet been thoroughly investigated, especially using different protocols.
The purpose of the present study was to clinically evaluate the outcome of immediate functional loading of BioHorizons Laser-Lok® tapered internal implants in cases of partial posterior maxillary and/or mandibular edentulism, and to evaluate radiographically the influence of Laser-Lok® microtextured implant surface on crestal bone loss (CBL).

MATERIALS AND METHODS

This multicentric prospective clinical study was private-practice based. All patients considered for inclusion in the study were examined and treated between January 2008 and December 2011 in several private dental practices in Italy all having extensive experience in the implant treatment. All patients signed a written informed consent form and were selected according to the following criteria.

- No contraindications for treatment, such as systemic diseases (e.g., diabetes), pregnancy, regular use of prescription medications or consumption of recreational drugs.
- Need for rehabilitation with implant-supported prosthesis (two to four units) in a partially unilateral edentulous mandible or maxilla.
- Adequate amount of bone height for placement of an implant with a minimum length of 9 mm in an optimal prosthetic position.
- Healed bone sites free from infection (at least 5 months following extraction).
- Sufficient primary stability (minimal insertion torque of 35 Ncm.
- Minimal ISQ value of 60 (Osstell™, Osstell AB, Gothenburg, Sweden).
- Signed informed consent to participate and to follow a maintenance and observation program for 24



FIG. 1 BioHorizons Laser-Lok® Tapered Internal Implant (on the left magnification X 700).



FIG. 2 BioHorizons Laser-Lok® Tapered Internal implant collar comprised of a 0.3 mm turned surface, a 0.7 mm microgrooves with an 8µ pitch, and a 0.8 mm microgrooves with a 12µ pitch.

DIAMETER MM	LENGTH MM	MANDIBLE	MAXILLA	TOTAL NUMBER
3.8	9	4	2	6
3.8	10.5	6	4	10
3.8	12	8	6	14
3.8	15	7	5	12
4.6	9	12	8	20
4.6	10.5	8	14	22
4.6	12	7	8	15
4.6	15	6	2	8

TABLE 1 Length and Diameter of 107 Inserted Implants.

BONE QUALITY	BONE QUANTITY				TOTAL NUMBER
	1	2	3	4	
A	-	2	5	2	9
B	8	10	18	13	49
C	-	13	15(1)	7 (1)	35 (2)
D	1	6 (1)	3	4 (2)	14 (3)
TOTAL	9	31	41	26	107

TABLE 2 Bone Quality and Quantity (failure within the brackets).

months which included postoperative radiographs. Exclusion criteria were non compensated diseases, poor oral hygiene, severe maxilla-mandibular space discrepancies as well as presence of a "deep bite" and parafunctional habits (bruxism and clenching).
Periodontal status was assessed by a comprehensive periodontal examination, and patients with periodontitis were treated before implant surgery. A complete pre-surgical evaluation was performed for all patients, including a wax-up and fabrication of a surgical stent. All splinted provisional restorations were fabricated in the dental laboratory based on the wax-up. Each case was evaluated by examining diagnostic casts for the maxilla-mandibular relationship, intraoral radiographs or panoramic radiographs, and computed tomography scans. Demographic data, medical and dental health history, and smoking status were obtained by questionnaire.
BioHorizons Laser-Lok® Tapered Internal implants (Birmingam, AL, USA) were used in the study (Fig. 1). This implant is characterized by a positive tolerance, signified by a tapered geometry. It has a modified surface treated with resorbable blast media (roughness between 0.72 and 1.34 µ) and a dual bio-affinity collar with an implant neck consisting of two types of microgrooves. The implant neck is comprised of a 0.3 mm turned surface, a 0.7 mm microgrooves with an 8µm pitch, and a 0.8mm microgrooves with a 12 µm pitch (Fig. 2). A total of 107 implants with lengths of 9 to 15 mm and a diameter of 3,8 to 4,6 mm were inserted: 49 in maxillary posterior area and 58 in the posterior mandible (Table 1).

Surgical Treatment

Patients were given 2 g of amoxicillin (Zimox®, Pfizer, Italy Srl) before implant surgery. Under local anesthesia, the implant sites were exposed via a midcrestal incision followed by a releasing distal incision. A full thickness flap was elevated and the positions of the implants were marked with a round bur. Then, the receiving



FIG. 3



FIG. 4



FIG. 5



FIG. 6

FIG. 3-6 Example of three units mandibular restorations
FIG. 3 Implant placement and temporary abutments. FIG.4 Immediate temporary prosthesis made of acrylic with a metal reinforcement.
FIG. 5 Soft tissue healing 4 months after implants placement. FIG. 6 Final prosthesis made of porcelain casted on golden alloy.

sites were prepared with cylindrical burs of increasing diameter, according to the recommendations of the manufacture. In the presence of very soft bone, an under-preparation technique was used with a specific smaller final bur prepared by the manufacturer for each implant diameter. Bone quality and quantity were assessed according to Lekholm and Zarb's criteria (49) (Table 2).All surgical procedures were performed with the aid of a custom-made surgical stent. Every effort was made to maintain parallelism between the implants and the adjacent dentition. To obtain adequate primary stability, the implants had to achieve an initial torque value of at least 35 Ncm, which was facilitated by the tapered shape of the implants. After the final implant positioning, sterile impression coping were connected and the flaps were sutured. Impressions were taken with an open tray technique using Impregum NF® (ESPE, Seefeld, Germany). Following this, a provisional abutment was positioned (Fig. 3) on the implant, and a transducer was fixed on the abutment in order to analyze the resonance frequency (RFA). The implant stability (expressed in ISQ) measurements had to be above 60 (Ostell, Integration

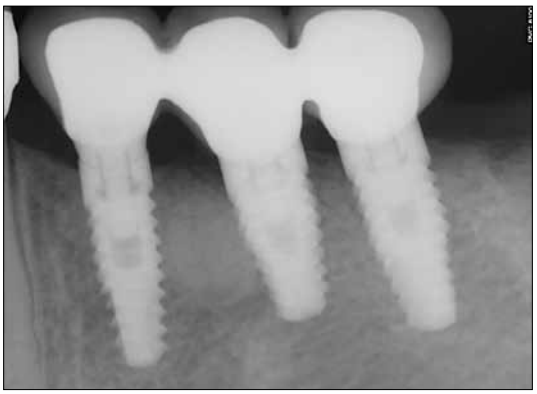

FIG. 7 Radiographs taken at 24 months follow-up (T3).

Diagnostic) to confirm primary stability. The ISQ stability values are determined by the rigidity of the implant/tissues interface and by the distance between the transducer and the first bone contact. Several studies have confirmed the correlation between the measurements with the resonance frequency and the

PARAMETERS	N	SUCCESS (%)	FAILURE (%)	EXPLANTATION
Implant	107	95.4	4.6	5
Gender				
Male	52	94.3	5.7	3
Female	55	96.4	3.6	2
Smokers				
Yes	67	94.1	5.9	4
No	40	97.7	2.3	1
Region				
Mandible	58	98.1	1.9	1
Maxilla	49	91.9	8.1	4

TABLE 3 Implant Success and Failure Rates.

	MANDIBLE	MAXILLA	TOTAL
Two units	5	6	11
Three units	6	5	11
Four units	7	6	13

TABLE 4 Prosthesis distribution according to the number of units.

rigidity of the implant in the bone tissue (50, 51), and a lower ISQ limit of 60 has been suggested for immediate implant loading (52).
Subsequently, a bite registration was taken in centric relation with occlusion waxes. The impressions were sent to the laboratory for the manufacturing of the temporary prosthesis. The patients were treated with a postsurgical antibiotic therapy (amoxicillin, Zimox®, Pfizer, Italy Srl), 1 g twice a day for 6 days, starting just before surgery, an anti-inflammatory therapy (nimesulide, Aulin®, Roche, Milan, Italy), twice a day for 4 days, and they were instructed to rinse with 0,2% solution of chlorexidine, twice a day for 10 days. Oral hygiene was limited to brushing around the implants with a soft toothbrush for the first 2 weeks. Thereafter, conventional brushing and flossing were re-established. Within 1 hour following surgery a temporary metal reinforced acrylic resin restoration was delivered and cemented with a temporary cement (Temp Bond, Kerr Co., Orange, CA, USA). No distal extensions were incorporated and a flattened cusp occlusal scheme was used as well as a platform switching design applied to the abutment (Fig. 4). Occlusion was in centric, with light contacts, possibly avoiding lateral and protrusion contacts. Occlusion marking paper had to leave lighter marks on the implant prosthesis compared to those of the adjacent teeth. After 4 to 6 months from implant placement (T1) (Fig. 5), provisional abutments and abutment screws were removed to assess implant stability by RFA. Final impressions were made directly on the abutments and a fixed final prosthesis made of porcelain casted on golden alloy was made and delivered (Fig. 6).

Radiographic Examinations

Intraoral radiographs were taken after implant insertion at baseline and then after 6 (T1), 12 (T2), and 24 (T3) months using a paralleling technique (Dentsply RINN, Elgin, IL, USA) for all radiographs (Fig. 7). Each radiograph was performed using a radiographic personalized stent for each patient, and examined by an independent radiologist. Radiographs were then digitalized using a dedicated scanner (HP 3000) with a resolution of 2,048 X 3,072 lines and converted into JPG files. A software package (AutoCAD 2000) was used to measure crestal bone loss (CBL). The program calculated vertical lines lengths, which represented CBL as the distance from the top of the implants to the crestal bone. Afterwards, CBL was calculated as the difference between follow-up and baseline value.

Implant Success Criteria

The following conditions were considered for implant success and recorded by a calibrated investigator for each implant: absence of fixture mobility, absence of peri-implant radiopacity/radiolucency at radiographic assessment, bone loss lower than 1.5 mm at 12 months radiographic exam, absence of suppuration, pain, infection and paresthesia. Failure was defined as removal of an implant due to any reasons.

Calibration of examiners

Examiners were calibrated by measuring the same 20 implants after 1 week, achieving an intraexamination reliability of 90% (data not shown). Examiners were recalibrated once after 6 months by measuring the same 10 implants following the initial protocol.

RESULTS

Five out of 107 implants were diagnosed as failed, giving a survival rate of 95.4% after 24 months, and were not included in the final study group (Tables 2 and 3). The failure occurred from 4 to 12 weeks after placement and interested 4 implants in the maxilla and 1 implant in the mandible. A total of 32 fixed partial dentures supported by 2 to 4 implants were fabricated (Table 4). Three failed implant were located in quality 4 bone, and 2 in quality 3 bone (Table 2). Three implants were

IMPLANT	SITE	LENGTH (MM)	DIAMETER (MM)	INSERTION TORQUE (NCM)	ISQ	N. OF UNITS	TIME AFTER SURGERY AND PROVISIONALISATION (WK)
1	15	12	3.8	35	80	2	6
2	26	10.5	4.6	35	78	2	4
3	16	10.5	4.6	35	84	2	8
4	46	12	4.6	35	81	2	5
5	17	12	3.8	35	75	3	12

TABLE 5 Characteristics of failed implants.

	MANDIBLE	MAXILLA	TOTAL
T1 (n=102)	0.43± 0.9	0.45 ± 1.3	0.43 ± 1.1
T2 (n= 91)	0.51 ± 0.8	0.53 ± 1,0	0.52 ± 0.9
T3 (n=75)	0.68 ± 1.5	0.64 ± 1.1	0.66 ± 1.3
n= number of sample			

TABLE 6 Mean Crestal Bone Loss (mm).

lost in a two-unit maxillary restoration, 1 implant was lost in a two-unit mandibular restoration, and 1 implant was lost in a three-unit maxillary restoration (Table 5). All the failed implants were successfully replaced with another implant after 4 months of healing, and loaded with delayed loading protocol. RFA showed an average ISQ of 72.8±3.2 at placement and 70.5±4.1 at T1. A marginal bone remodeling of 0.42mm±1.1 mm, 0.52 mm±0.9 mm, and 0.66 mm±1.3 mm was observed at T1, T2, and T3 respectively (Table 6). No statistical differences were observed for implant length, mesial or distal bone levels, or the insertion torque values measured.

DISCUSSION

The present study confirms the results from previous clinical investigations that good outcomes can be obtained with immediate loading of implants positioned in the posterior upper and lower partial edentulous areas (14, 15). Immediate loading protocols offer obvious advantages for the patient, such as a momentary reduction of oral handicap and decreased surgery and chair time, since abutment connection surgery is not needed. In accordance with data from the literature (14-15), in the present study we have used screw implants with tapered design, rough surface, and with a minimum insertion torque value of 35 Ncm. Furthermore, a baseline resonance frequency threshold value of 60 ISQ was set as a minimum stability value in order to perform immediate function.

The survival rate of 95.4% found in the present study is in agreement with the data reported in the literature, which show a cumulative failure rate of implant supported fixed dental prostheses of 4.4% in a short time follow-up (53). Most of the lost implants in the present study were two unit prostheses. According with our results, a higher risk of implant failure in two-unit fixed partial prostheses compared to three/four-unit fixed partial prostheses is reported also by Margossian and cooworkers (54). This outcome suggests that the number of units in a prosthesis may positively impact implant stability during bone healing. In fact prostheses might work as an external rigid fixation device that splints the implants together and therefore reduces micro-movements. This concept is today also supported by a recent literature review (55), which emphasizes that in immediate implant loading protocols, splinted prostheses showed a higher success rate (94.7%) than those of implants restored with non splinted restorations (88.4%), regardless of implant design.

Another factor contributing to the good results of the present study is probably the modified site preparation protocol aiming for high primary stability, by using smaller final twist drills depending on bone quality. The modified surgical technique that we performed had been previously evaluated by Ostman and coworkers (52) in a study in which the primary stability of 905 implants was evaluated with RFA. Based on the results of the study, the authors suggested that when an immediate loading protocol is applied the drilling surgical technique cannot be standardized but needs to be modified according to the bone quality found.

Marginal bone loss represents an important indicator for peri-implant health, and its level is considered a determining factor in the evaluation of survival quality (and thus of primary outcome), since peri-implant bone loss may induce pocket formation. This could be unfavorable for the long term health of the peri-implant tissues (56). The values generally accepted as a reasonable guideline for crestal bone loss since the late 80's is -1.5 mm for the first year post-loading of the implants and -0.2 mm of additional loss for each following year (57, 58). It must also be emphasized that data present in the literature (59) show that once immediately loaded or restored, implants integrated successfully presented a peri-implant tissue reaction comparable with those of the conventionally loaded

implants. No evidence suggested that peri-implant mucosal complications could be directly attributed to immediate loading or restoration protocols. The precise mechanisms of crestal bone resorption around dental implants is not yet completely known. Bone loss may result from implant design, bone density, surgical trauma at implant insertion or at second-stage surgery, occlusal overload, apical migration of crevicular epithelium in an attempt to isolate bacterial-induced infection or to establish a biological width, blood supply interruption, or development of a pathogenic bacterial biofilm (60-64). Previously histological experimental studies highlighted that Laser-Lok® microtextured collar implant surface primarily influence cortical bone remodeling around the implant neck (46). Using a standard loading protocol with Laser-Lok® implants, Botos and coworkers (48) reported a mean crestal bone loss at 1 year of 0,42 mm, while at 3 years Shapoff (68) and Pecora and coworkers (47) reported a mean crestal bone loss of 0,46 mm, and of 0,59 mm, respectively. Results of our study are in agreement with these data, showing a mean crestal bone loss of 0.66 mm±1.3 mm after two years of function, but support also the hypothesis that Laser-Lok® microtextured collar may lead to a decreased amount of initial crestalbone loss also when implants are immediately loaded. Today there is histologic evidence of a mechanical attachment of connective tissue fibers to Laser-Lok® microtexturing surface of implants placed both in native bone (46) and in fresh extraction sites (65). It has been suggested that this direct connective tissue attachment might serve as a physiological barrier to the apical migration of the junctional epithelium, and prevent crestal bone resorption (46). However, to confirm this ipothesys further histological researches are needed, especially comparing Laser-Lok® implants in different loading conditions. While the present study did not demonstrate histologic evidence of a connective tissue attachment to the collar of immediate loaded implants, within the limits of the investigation it is possible conclude that immediate functional loading of Laser-Lok® Tapered Internal implant in partially edentulous arches leads to a short term treatment outcome that seems to be not less favourable than conventional loading, and with no adverse peri-implant consequences after 24 months of function in highly motivated patients with excellent oral hygiene. However, it is correct to remember that the concept of immediate loading should be performed according to a specified protocol with attention to adequate primary implant stability, careful patient instruction, the use of a resilient acrylic resin for the fabrication of the temporary restoration, the exclusion of parafunctional/bruxist patients and, the immediate splinting of the implants.

Acknowledgment

This study has been supported by a grant from Classimplant, Rome, Italy.

REFERENCES

1. Nkenke E, Fenner M. Indications for immediate loading of implants and implant success. Clin Oral Imp Res 2006;17 (Suppl. 2),; 19–34
2. Glauser R, Ree A, Lundgren A, Gottlow J, Hammerle CH &Scharer P. Immediate occlusal loading of Branemark implants applied in various jawbone regions: a prospective, 1-year clinical study. ClinImpl Dent Relat Res 2001; 3: 204–213.
3. Glauser R, Ruhstaller P. &Windisch S, et al. Immediate occlusal loading of Branemark System TiUnite implants placed predominantly in soft bone: 4-year results of a prospective clinical study. ClinImpl Dent Relat Res 2005; 7 (Suppl. 1): 52–59.
4. Glauser R., Zembic A., Ruhstaller P. &Windisch S. Five-year results of implants with an oxidized surface placed predominantly in soft quality bone and subjected to immediate occlusal loading. J Prosthet Dent. 2007; 97 Suppl. 1): 59–68. Erratum in: J Prosthet Dent. (2008) 99: 167.
5. Cannizzaro G. & Leone M. Restoration of partially edentulous patients using dental implants with a microtextured surface: a prospective comparison of delayed and immediate fully occlusal loading. Int J OralMaxillofacImplants. 2003; 18: 512–522.
6. Testori T, Bianchi F, Del Fabbro M, et al. Immediate non-occlusal loading vs. early loading in partially edentulous patients. PractProcedAesthet Dent 2003;15: 787–794.
7. Degidi M, Nardi D, Piattelli A. Immediate restoration of small-diameter implants in cases of partial posterior edentulism: a 4-year case series. J Periodontol 2009;80: 1006–1012.
8. Achilli A, Tura F, Euwe E. Immediate/ early function with tapered implants supporting maxillary and mandibular posterior fixed partial dentures: preliminary results of a prospective multicenter study. J Prosthet Dent 2007; 97 (Suppl. 1): 52–58. Erratum in: . J Prosthet Dent 2008; 99: 167.
9. Schincaglia GP, Marzola R, Scapoli C, Scotti R. Immediate loading of dental implants supporting fixed partial dentures in the posterior mandible: a randomized controlled split-mouth study-machined versus titanium oxide implant surface. Int J Oral Maxillofac Implants 2007;22: 35–46.
10. Galli F, Capelli M, Zuffetti F, Testori T, Esposito M. Immediate non-occlusal vs. early loading of dental implants in partially edentulous patients: a multicentre randomized clinical trial. Peri-implant bone and soft-tissue levels. Clin Oral Impl Res 2008;19: 546–552.
11. Ganeles J, Zollner A, Jackowski J, ten Bruggenkate C, Beagle J, Guerra, F. Immediate and early loading of Straumann implants with a chemically modified surface (SLActive) in the posterior mandible and maxilla: 1-year results from a prospective multicenter study. ClinOralImpl Res 2008;19: 1119– 1128.
12. Weber HP, Morton D, Gallucci GO, Roccuzzo M, Cordaro L, Grutter L.Consensus statements and recommended clinical procedures regarding loading protocols .Int J Oral Maxillofac Implants.2009;24 Suppl:180-3.
13. Aparicio C, Rangert B, Sennerby L. Immediate/early loading of dental implants: a report from the Sociedad Española de Implantes World Congress consensus meeting in Barcelona, Spain, 2002. Clin Implant Dent Relat Res 2003; 5:57–60.
14. Esposito M, Grusovin MG, Willings M, Coulthard P & Worthington HV. Interventions for replacing missing teeth: different times for loading dental implants. Cochrane Database of Systematic Reviews 2007; Chichester, UK: John Wiley & Sons, Ltd.
15. Gapski R, Wang HL, Mascarenhas P, et al. Critical review of immediate implant loading. Clin Oral Impl Res. 2003;14:515-527.
16. Romanos GE. Present status of immediate loading of oral implants. J Oral Implantol. 2004;30:189-197.
17. Degidi M, Piattelli A. 7-year follow-up of 93 immediately loaded titanium dental implants. J Oral Implantol. 2005;31:25-31.
18. Chiapasco M. Early and immediate restoration and loading of implants in completely edentulous patients. Int J Oral Maxillofac Implants. 2004;19 Suppl:76-91.
19. Szmukler-Moncler S, Salama H, Reingewirtz Y, Dubruille JH. Timing of loading and effect of micromotion on bone-dental implant interface: review of experimental literature.J Biomed Mater Res. 1998 Summer;43(2):192-203.
20. Glauser R, Portmann M, Ruhstaller P, Gottlow J, Schärer P. Initial implant stability using different implant designs and surgical techniques. A comparative clinical study using insertion torque and resonance frequency analysis. ApplOsseoint Res 2001; 1:6–8.
21. VandenBogaerde L, Pedretti G, Dellacasa P, Mozzati M, Rangert B. Early function of splinted implants in maxillas and posterior mandibles using Brånemark System turned surface implants: an 18-month prospective clinical multicenter study. Clin Implant Dent Relat Res 2003; 5(Suppl 1):21–28.
22. Åstrand P, Billstromm C, Feldmann H, et al. Tapered implants in jaws with soft

bone quality: a clinical and radiographic 1-year study of the Branemark System Mark IV fixture. ClinImpl Dent Relat Res 2003; 5:213–218.
23. Avila G, Galindo P, Rios H, and Wang H-L. Immediate Implant Loading: Current Status From Available Literature. Implant Dent 2007; Volume 16, Number 3: 235-245
24. Misch CE. Bone classification, training keys to implant success. Dent Today. 1989;8:39-44.
25. Östman PO, Hellman M, Sennerby L. Direct implant loading in the edentulous maxilla using a bone density-adapted surgical protocol and primary implant stability criteria for inclusion. Clin Implant Dent Relat Res 2005; 7(Suppl 1):S60–S69.
26. Friberg B, Sennerby L, Roos J, Lekholm U. Identification of bone quality in conjunction with insertion of titanium implants. A pilot study in jaw autopsy specimens. Clin Oral Implants Res 1995; 6:213–219.
27. Friberg B, Sennerby L, Gröndahl K, Bergstrom C, Back T, Lekholm U. On cutting torque measurements during implant placement: a 3-year clinical prospective study. Clin Implant Dent Relat Res 1999; 1:75–83.
28. Calandriello R, Tomatis M, Rangert B. Immediate functional loading of Brånemark system implants with enhanced initial stability: a prospective 1- to 2-year clinical and radiographic study. Clin Implant Dent Relat Res 2003; 5(Suppl 1):10–20.
29. Ostman PO, Hellman M, Sennerby L. Direct implant loading in the edentulous maxilla using a bone density-adapted surgical protocol and primary implant stability criteria for inclusion. Clin Implant Dent Relat Res 2005;7(suppl 1):S60–S69.
30. Malo P, Friberg B, Polizzi G, Gualini F, Vighagen T, Rangert B. Immediate and early function of Brånemark System implants placed in the esthetic zone: A 1-year prospective clinical multicenter study. Clin Implant Dent Relat Res 2003;5(suppl 1):37–46.
32. Rompen E, DaSilva D, Hockers T, et al. Influence of implant design on primary fit and stability. A RFA and histological comparison of MKIII and MKIV Brånemark implants in the dog mandible. ApplOsseoin Res 2001; 1:9–11.
33. Wang HL, Ormianer Z, Palti A, et al. Consensus Conference on Immediate Loading: The Single Tooth and Partial Edentulous Areas. ImplantDent2006;15: 324-333.
34. Piattelli A, Paolantonio M, Corigliano M, et al. Immediate loading of titanium plasma-sprayed screw-shaped implants in man: a clinical and histological report of two cases. J Periodontol. 1997; 68:591-597.
35. Corso M, Sirota C, Fiorellini J, et al. Clinical and radiographic evaluation of early loaded free-standing dental implants with various coatings in beagle dogs. J ProsthetDent. 1999;82:428-435.
36. Degidi M, Petrone G, Iezzi G, et al. Histologic evaluation of a human immediately loaded titanium implant with a porous anodized surface. Clin Implant Dent Relat Res. 2002;4:110-114.
37. Balshi TJ, Wolfinger GJ. Immediate loading of Branemark implants in mandibles: a preliminary report. Implant Dent. 1997;6:83-88.
38. Colomina LE. Immediate loading of implant-fixed mandibular prostheses: a prospective 18-month follow-up clinical study-preliminary report. Implant Dent 2001;10:23-29.
39. Jaffin RA, Kumar A, Berman CL. Immediate loading of dental implants in the completely edentulous maxilla: a clinical report. Int J Oral Maxillofac Implants 2004; 19:721-730.
40. Misch C, Scortecci GM. Immediate load applications in implant dentistry. In: Misch C (ed). Dental Implant Prosthetics. St Louis: Elsevier Mosby, 2005:531-567
41. Misch CE, Wang HL, Misch CM, et al. Rationale for the application of immediate load in implant dentistry: part II. Implant Dent2004;13:310-321.
42. Kim Y, Oh TJ, Misch CE, et al. Occlusal considerations in implant therapy: clinical guidelines with biomechanical rationale. Clin Oral Implants Res. 2005;16: 26-35.
43. Ricci JL, Charvert J, Frenkel S, et al. Bone response to laser microtexutred surfaces. In: Davies JE (Ed). Bone Engineering Toronto: Em2, 2000:282-294
44. Alexander H, Ricci JL, Hrico GJ. Mechanical basis for bone retention around dental implants: J Biomed Mater Res B ApplBiomater 2007; 23: 200-210
45. Nevins M, Kim DM, Jun SH, Guze K, Schupbach P, Nevins ML. Histologic evidence of a connective tissue attachment to laser microgrooved abutments: a canine study. Int J Periodontics Restorative Dent. 2010 Jun;30(3):245-55.
46. Nevins M, Nevins ML, Camelo M, Boyesen JL, Kim DM. Human histologic evidence of a connective tissue attachment to a dental implant. Int J PeriodonticsRestorativeDent. 2008 Apr;28(2):111-21.
47. Pecora GE, Ceccarelli R, Bonelli M, Alexander H, Ricci JL. Clinical Evaluation of Laser Microtexturing for Soft Tissue and Bone Attachment to Dental Implants. Implant Dent. 2009;18:57-66
48. Botos S, Yousef H, Zweig B, Flinton R, Weiner S. The effect of Laser Microtexturing of the dental implant collar on crestal bone levels and peri-implant health.Int J Oral Maxillofac Implants 2011; 26:492-498
49. Lekholm U, Zarb GA. Patient selection. In: Brånemark P-I, Zarb GA, Albrektsson T, eds. Tissue-integrated prostheses: osseointegration in clinical dentistry. Chicago, IL: Quintessence, 1985:199–209.
50. Meredith N, Alleyne D, Cawley P. Quantitative determination of the stability of the implant-tissue interface using resonance frequency analysis. Clin Oral Impl Res 1996; 7:261–267.
51. Meredith N, Book K, Friberg B, Jemt T, Sennerby L. Resonance frequency measurements of implants stability in vivo. A cross-sectional and longitudinal study of resonance frequency measurements on implants in the edentulous and partially dentate maxilla. Clin Oral Impl Res 1997; 8:226– 233.
52. Östman PO, Hellman M, Wendelhag I, Sennerby L. Resonance frequency analysis measurements of implants at placement surgery. Int J Prosthodont 2006; 19:77–83. (Discussion 84).
53. Pjetursson BE, Thoma D, Jung R. Zwahlen M, Zembic A. A systematic review of the survival and complication rates of implant-supported fixed dental prostheses (FDPs) after a mean observation period of at least 5 years. Clin. Oral Implants Res 2012; 23(Suppl. 6), 22–38
54. Margossian P, Mariani P, Stephan G, Margerit J, Jorgensen C. Immediate loading of mandibular dental implants in partially edentulous patients: a prospective randomized comparative study.Int J Periodontics Restorative Dent. 2012 Apr;32(2):e51-8.
55. Avila G, Galindo P, Rios H, Wang HL. Immediate implant loading: current status from available literature.Implant Dent. 2007 Sep;16(3):235-45. Review.
56. Heydenrijk K, Meijer HJ, van der Reijden WA, Raghoebar GM, Vissink A, Stegenga B. Microbiota around root-form endosseous implants: a review of the literature. Int J Oral Maxillofac Implants. 2002 Nov-Dec;17(6):829-38
57. Albrektsson T, Zarb G, Worthington P, Eriksson AR. The long term efficacy of currently used dental implants: A review and proposed criteria of success. Int J Oral Maxillofac Implants. 1986;1:11-25.
58. Misch, C.E., Perel, M.L., Wang, H.L., Sammartino, G., Galindo-Moreno, P., Trisi, P., Steigmann, M., Rebaudi, A., Palti, A., Pikos, M.A., Schwartz- Arad, D., Choukroun, J., Gutierrez-Perez, J.L., Marenzi, G. &Valavanis, D.K. (2008) Implant success, survival, and failure. The International Congress of Oral Implantologists (ICOI) Pisa Consensus Conference. Implant Dentistry 17: 5–15.
59. Glauser, R., Zembic, A. &Hammerle, C.H.F. A systematic review of marginal soft tissue at implants subjected to immediate loading or immediate restoration. Clin Oral Impl Res 2006; 17 (Suppl. 2): 82–92.
60. Hermann JS, Cochran DL, Nummikoski PV, Buser D. Crestalbonechanges around titanium implants. A radiographic evaluation of unloaded nonsubmerged and submerged implants in the canine mandible. J Periodontol. 1997 Nov;68(11):1117-30.
61. Hermann JS, Buser D, Schenk RK, Higginbottom FL, Cochran DL. Biologic width around titanium implants. A physiologically formed and stable dimension over time.Clin Oral Implants Res. 2000 Feb;11(1):1-11.
62. Berglund T, Lindhe J. Dimension of the periimplant mucosa. Biological width revisited. J ClinPeriodontol 1996;23:971-973
63. Quyrinen M, Naert I, van Steenberghe D, Nys L. A study of 589 consecutive implants supporting complete fixed prostheses . Part 1: Periodontal aspects. J Prosthet Dent 1992;68:655-663
64. van Steenberghe D, Lekholm U, Bolendere C, et al. Applicability of osseointegrated oral implant in the rehabilitation of partial edentulism. A prospective multicenter study on 558 fixture. Int J Oral Maxillofac Implants 1990;5:272-281
65. Shin S-Y., Han D-H. Influence of microgrooved collar design on soft and hard tissue healing of immediate implantation in fresh extraction sites in dogs. Clin Oral Impl Res 2010;21,; 804–814.