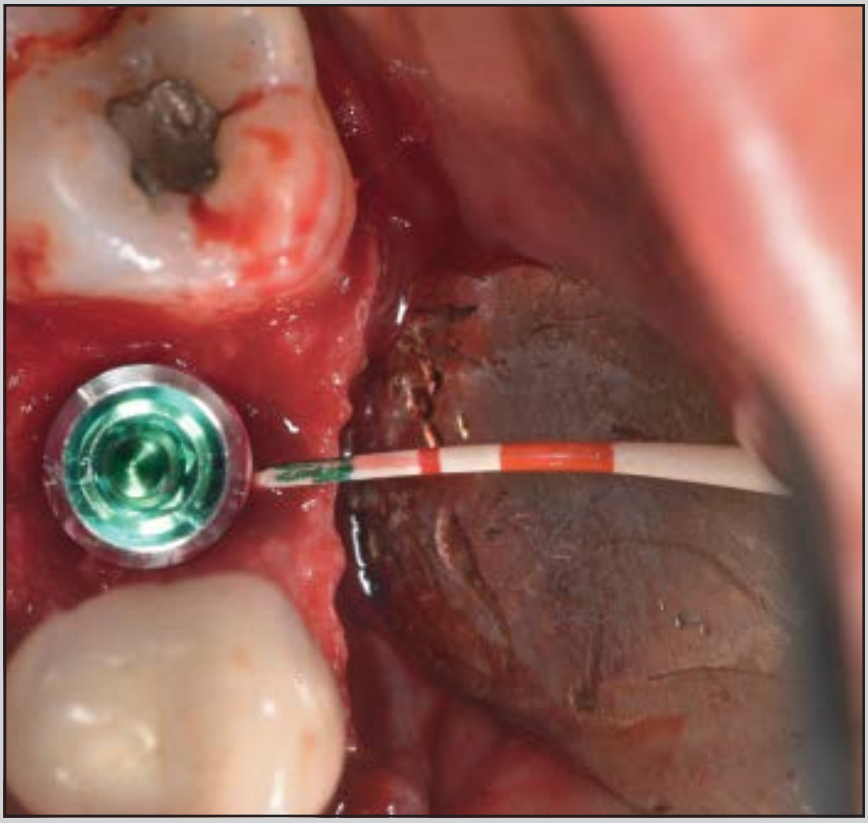



© 2014 BY QUINTESSENCE PUBLISHING CO, INC. PRINTING OF THIS DOCUMENT IS RESTRICTED TO PERSONAL USE ONLY.
NO PART MAY BE REPRODUCED OR TRANSMITTED IN ANY FORM WITHOUT WRITTEN PERMISSION FROM THE PUBLISHER.

Soft and Hard Tissue Modifications at Immediate Transmucosal Implants (with Laser-Lok Microtextured Collar) Placed into Fresh Extraction Sites: A 6-Month Prospective Study with Surgical Reentry



Vincenzo Iorio-Siciliano, DDS, PhD[1]/Giuseppe Marzo,MD, DDS[2]
Andrea Blasi, MD, DDS[1]/Carlo Cafiero, MD, DDS, PhD[3]
Michele Mignogna, MD, DDS[4]/Michele Nicolò, MD, DDS[5]

Histologic and clinical studies confirm that laser-microtextured implant collars favor the attachment of connective fibers and reduce probing depth and peri-implant bone loss when compared with machined collars. This prospective study aimed at assessing the alveolar dimensional changes after immediate placement of a transmucosal implant with a Laser-Lok microtextured collar associated with bone regenerative procedures. Thirteen implants were placed immediately into single-rooted extraction sockets. Peri-implant defects were treated with bovine-derived xenografts and resorbable collagen membranes. At 6-month surgical reentry, the Laser-Lok microtextured collar provided more favorable conditions for the attachment of hard and soft tissues and reduced the alveolar bone loss.
(Int J Periodontics Restorative Dent 2014;34:541–549. doi: 10.11607/prd.1678)

[1]Adjunct Professor, Department of Neurosciences, Reproductive and Odontostomatological Sciences, Department of Periodontology, University of Naples Federico II, Naples, Italy.
[2]Professor, Department of Health Sciences, University of L'Aquila, L'Aquila, Italy.
[3]Aggregate Professor, Adjunct Professor, Department of Neurosciences, Reproductive and Odontostomatological Sciences, University of Naples Federico II, Italy.
[4]Professor, Adjunct Professor, Department of Neurosciences, Reproductive and Odontostomatological Sciences, University of Naples Federico II, Italy.
[5]Associate Professor, Department of Neurosciences, Reproductive and Odontostomatological Sciences, University of Naples Federico II, Italy.

Correspondence to: Dr Vincenzo Iorio-Siciliano, Department of Neurosciences, Reproductive and Odontostomatological Sciences, University of Naples Federico II, via Sergio Pansini, 5 80131 Napoli, Italy; email: enzois@libero.it.

©2014 by Quintessence Publishing Co Inc.

Today there is evidence to suggest that immediate implant placement does not prevent vertical or horizontal resorption of the ridges and that although guided bone regeneration (GBR) combined with immediate placement may reduce horizontal resorption, it does not prevent vertical resorption of the facial bone.[1] Nevertheless, some recent strategies have been developed that use the principles of tissue engineering to prevent remodeling and maintain the original shape of the ridge. One of these strategies is laser-microtexturing surfaces with 8- and 12-μm grooves.[2] Tissue culture studies have demonstrated cellular attachment by osteoblasts and fibroblasts to laser-microgrooved surfaces.[3,4] Others studies have demonstrated the histologic evidence of a mechanical attachment of connective tissue fibers to Laser-Lok (BioHorizons) microtextured surfaces of implants placed both in native bone and in fresh extraction sites.[5] This kind of attachment differs significantly from the one traditionally associated with implants.[6,7] The most important aspects of the Laser-Lok connective tissue

© 2014 BY QUINTESSENCE PUBLISHING CO, INC. PRINTING OF THIS DOCUMENT IS RESTRICTED TO PERSONAL USE ONLY.
NO PART MAY BE REPRODUCED OR TRANSMITTED IN ANY FORM WITHOUT WRITTEN PERMISSION FROM THE PUBLISHER.



Fig 1 *A Single-Stage Implant with a tricalcium phosphate RBT surface, a length of 12 mm, an endosseous diameter of 4 mm, a shoulder diameter of 5 mm, and a neck height of 2.8 mm (1-mm turned surface, 0.9-mm microgroove with an 8 × 6–µm pitch, and 0.9-mm microgroove with a 12 × 12–µm pitch).*

attachment have to be associated with the fact that its position is determined by the layout of the laser microgrooves and that connective tissue fibers are perpendicularly oriented to the implant surface and act as a seal to apical migration of gingival epithelial cells and fibroblasts.[2] It has been hypothesized that a microtextured implant collar surface with 8- and 12-µm grooves might provide opportunities for more stable coronal fibrocollagenous attachment and might potentially mitigate or eliminate the negative sequelae connected with crestal bone modeling. The aim of this study was to determine, after 6 months of healing, whether immediate placement of transmucosal implants with a Laser-Lok microtextured collar in fresh extraction sockets in conjunction with regenerative procedures influences the modeling of the alveolar ridge that occurs after tooth extraction and to assess the dimensional change of alveolar bony walls.

Method and materials

Experimental design

The study design was prospective, with surgical reentry at 6 months following tooth extraction and immediate transmucosal implant placement. Titanium oral implants (Single-Stage Implant System, BioHorizons) with a tricalcium phosphate resorbable blast textured (RBT) surface, a length of 12 mm, an endosseous diameter of 4 mm, and a shoulder diameter of 5 mm were immediately placed into single-rooted extraction sockets. The implant neck is composed of a 1-mm turned surface, a 0.9-mm microgroove with an 8 × 6-µm pitch (connective tissue), and 0.9-mm microgroove with a 12 × 12–µm pitch (bone tissue; Fig 1). Peri-implant marginal defects were treated according to the principles of GBR using bovine-derived xenograft (Laddec, BioHorizons) and resorbable collagen membranes (Mem-Lok, BioHorizons).

Patient population

A total of 13 patients received 13 BioHorizons System implants. All patients were recruited from the patient pool of VIS's private practice in Naples, Italy. The following inclusion criteria were applied: age ≥ 18 years; presence of mandibular or maxillary single-rooted teeth to be extracted because of an endodontic failure, caries, or root fracture; integrity of extraction sockets walls; presence of sufficient residual alveolar bone volume to achieve primary implant stability; presence of a tooth mesial and distal to the extraction site; full-mouth plaque score (FMPS) and full-mouth bleeding score (FMBS) ≤ 25% at baseline; and presence of at least 2 mm of keratinized tissue to allow flap management. Patients were excluded on the basis of: presence of relevant medical conditions contraindicating surgical intervention, pregnancy or lactation, tobacco smoking, and periodontal

© 2014 BY QUINTESSENCE PUBLISHING CO, INC. PRINTING OF THIS DOCUMENT IS RESTRICTED TO PERSONAL USE ONLY.
NO PART MAY BE REPRODUCED OR TRANSMITTED IN ANY FORM WITHOUT WRITTEN PERMISSION FROM THE PUBLISHER.



Fig 2 (left) *Clinical view of the fractured maxillary second premolar.*

Fig 3 (right) *Clinical view of the extraction socket and root removal without damage to the buccal and palatal bone walls.*



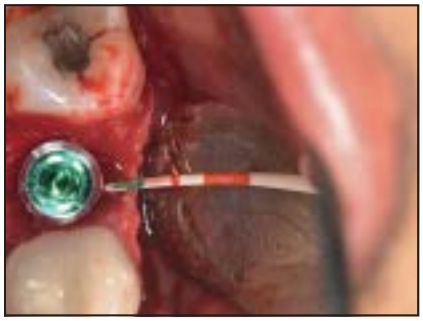

Fig 4 *Occlusal view after immediate placement of a Single-Stage Implant. Peri-implant marginal defects are more pronounced at the buccal aspect.*



Fig 5 *Clinical view after filling of the peri-implant defects with bone-derived xenograft particles (Laddec).*



Fig 6 *Clinical view after adaptation of a resorbable collagen membrane around the neck of the implant (Mem-Lok).*

compromise. Informed consent was obtained, and the study was performed according to the principles outlined in the Declaration of Helsinki on experimentation involving human subjects.

Clinical parameters

At baseline, the following parameters were recorded at six sites per tooth (ie, distobuccal, buccal, mesiobuccal, mesiolingual, lingual, distolingual): FMPS[8] and FMBS[9] using a manual periodontal probe (PerioWise color-coded probe, Premier) and a probing force of 0.3 N.

Surgical procedures

After elevation of a mucoperiosteal flap extending one tooth in the mesial and distal directions, tooth extraction and implant placement were performed simultaneously (Figs 2 and 3). The implant bed preparation was performed according to the manufacturer's instructions. The implants were placed with the Laser-Lok microtextured collar (0.9-mm microgroove with an 8 × 6–µm pitch and 0.9-mm microgroove with a 12 × 12–µm pitch) in subcrestal position, while the apical limit of the turned neck portion (ie, 1 mm) was positioned at the level of the alveolar crest. Primary stability was achieved in the apical portion of the fresh alveolar socket (Fig 4). The marginal defects between the implant and internal walls of the extraction sockets were regenerated by the use of bioresorbable membranes supported by bone substitutes. Bovine-derived xenograft particles with a mean size of 600 µm (range, 200 to 1,000 µm) (Laddec) were placed into the defects (Fig 5), followed by the punch and adaptation of a collagen membrane (Mem-Lok) around the neck of the implant (Fig 6). The membrane extended 3 to 4 mm beyond the borders of the bony defects. After the insertion of a healing

© 2014 BY QUINTESSENCE PUBLISHING CO, INC. PRINTING OF THIS DOCUMENT IS RESTRICTED TO PERSONAL USE ONLY.
NO PART MAY BE REPRODUCED OR TRANSMITTED IN ANY FORM WITHOUT WRITTEN PERMISSION FROM THE PUBLISHER.

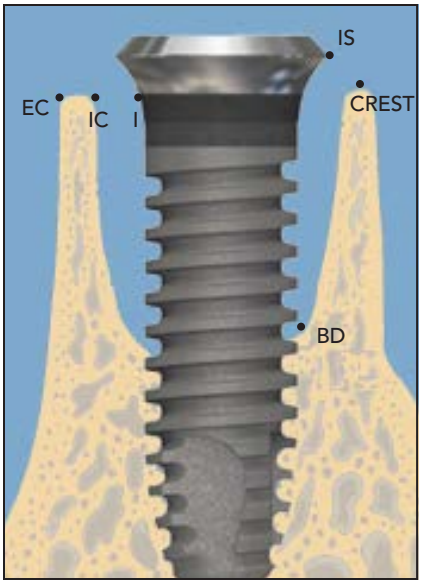

Fig 7 (left) *Buccolingual schematic illustration of the intrasurgical measurements: IS-BD, IS-CREST, CREST-BD, EC-I, IC-I.*

Fig 8 (right) *Occlusal view of peri-implant soft tissues after 6 months of healing and before surgical reentry.*



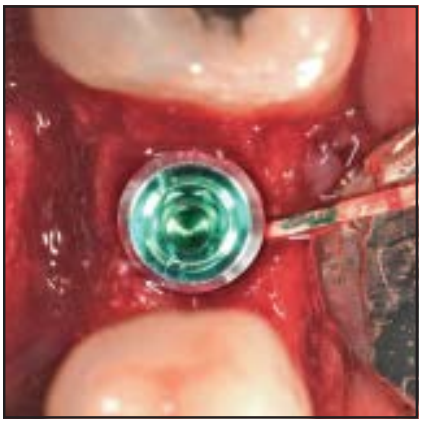

Fig 9 (left) *Occlusal view after surgical reentry. The horizontal buccal and palatal bone resorption is visible.*

Fig 10 (right) *After surgical reentry, connective soft tissue is visible on the Laser-Lok microtextured collar.*

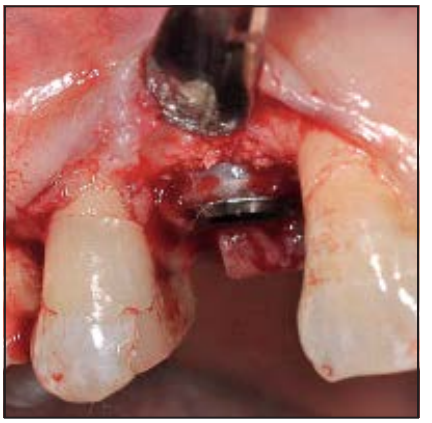

cap, the buccal and oral flaps were repositioned without any tension and sutured around the healing cap using non-resorbable monofilament sutures with the goal of transmucosal wound healing.

Intrasurgical measurements

After implant placement and before regenerative procedures, the following intrasurgical measurements were recorded to the nearest millimeter at four sites per implant (ie, mesial, buccal, distal, and lingual): implant shoulder (IS)—bony defect (BD), IS—the most coronal extension of the alveolar crest (CREST), CREST-BD, external aspect of the socket wall at the level of the alveolar crest (EC)—implant surface (I), internal aspect of the socket wall at the level of the alveolar crest (IC)-I (Fig 7).

Postsurgical instructions and infection control

Postoperative pain and edema were controlled with ibuprofen (eg, 600 mg immediately after the surgical intervention and after 4 hours). To help prevent wound infection, all patients received systemic antibiotics (eg, amoxicillin + clavulanic acid, 1 g twice daily for 7 days). Patients were instructed to rinse twice daily with 0.12% chlorhexidine digluconate for the first 2 weeks.

Surgical reentry

After 6 months of healing (Fig 8), a surgical reentry procedure was performed. Full-thickness flaps were elevated to allow access to the marginal portions of the implants. The measurement of the distances IS-BD,

© 2014 BY QUINTESSENCE PUBLISHING CO, INC. PRINTING OF THIS DOCUMENT IS RESTRICTED TO PERSONAL USE ONLY.
NO PART MAY BE REPRODUCED OR TRANSMITTED IN ANY FORM WITHOUT WRITTEN PERMISSION FROM THE PUBLISHER.

IS-CREST, CREST-BD, EC-I, and IC-I was repeated at four sites per implant (Figs 9 and 10). The mucoperiosteal flaps subsequently were sutured around the healing cap.

Delivery of fixed single-unit crowns

All implants remained unloaded until surgical reentry. Four weeks after surgical reentry, all implants were restored with a provisional acrylic single-unit crown. After 30 days, the provisional crown was removed, and a porcelain-fused-to-metal single-unit crown was cemented.

Statistical analysis

Descriptive statistics (ie, mean ± SD) were used to represent the patient population. All variables were expressed in millimeters, with the exception of the FMPS and the FMBS, which were expressed in percentages. A paired *t* test was used to compare intragroup differences at baseline and at the 6-month surgical reentry. A *P* value <.05 was accepted to identify a statistically significant difference. The data analysis was performed using statistical software (NCSS-PASS, Number Cruncher Statistical Systems).

Table 1 Patient population

Patient no.	Sex	Age (years)	Mean FMPS (%)	Mean FMBS (%)
1	Male	45	20	19
2	Female	37	21	18
3	Male	27	22	21
4	Male	56	19	18
5	Male	51	20	20
6	Female	43	21	21
7	Male	32	18	19
8	Female	48	18	18
9	Male	34	21	20
10	Female	44	21	20
11	Male	45	20	19
12	Female	56	19	18
13	Female	31	22	21
Mean ± SD		42.23 ± 9.43	20.15 ± 1.34	19.38 ± 1.19

Table 2 Implant position and reason for tooth extraction

Patient no.	Implant position*	Reason for tooth extraction
1	24	Fracture
2	14	Fracture
3	14	Fracture
4	35	Caries
5	15	Caries
6	35	Fracture
7	15	Fracture
8	12	Fracture
9	24	Caries
10	25	Fracture
11	34	Fracture
12	15	Fracture
13	45	Fracture

*Federation Dentaire Internationale tooth numbering system.

Results

Demographic data

The characteristics of the subject population at baseline are presented in Table 1. Thirteen patients (seven men and six women) fulfilling the inclusion criteria were enrolled.

Table 2 illustrates the reasons for tooth loss and the locations of immediate implant placement.

© 2014 BY QUINTESSENCE PUBLISHING CO, INC. PRINTING OF THIS DOCUMENT IS RESTRICTED TO PERSONAL USE ONLY.
NO PART MAY BE REPRODUCED OR TRANSMITTED IN ANY FORM WITHOUT WRITTEN PERMISSION FROM THE PUBLISHER.

Fig 11 *Changes in intrasurgical measurements assessed at four sites per implant between baseline and surgical reentry at 6 months. A P value < .05 was accepted as statistically significant.*

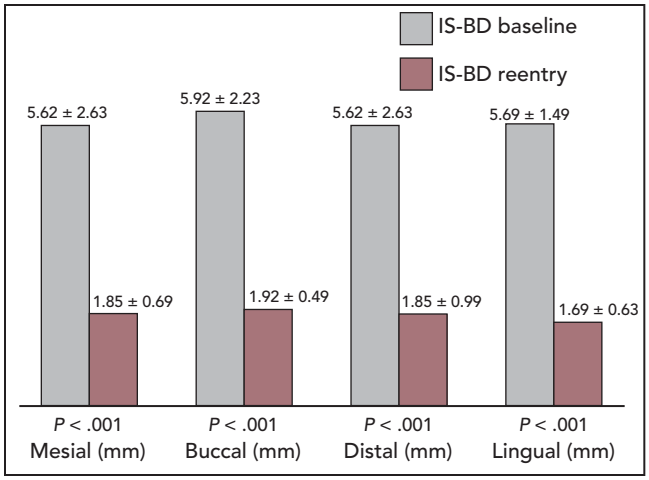

Fig 11a *IS-BD: vertical distance from the implant shoulder* (IS) *to the bottom of the bony defect* (BD).

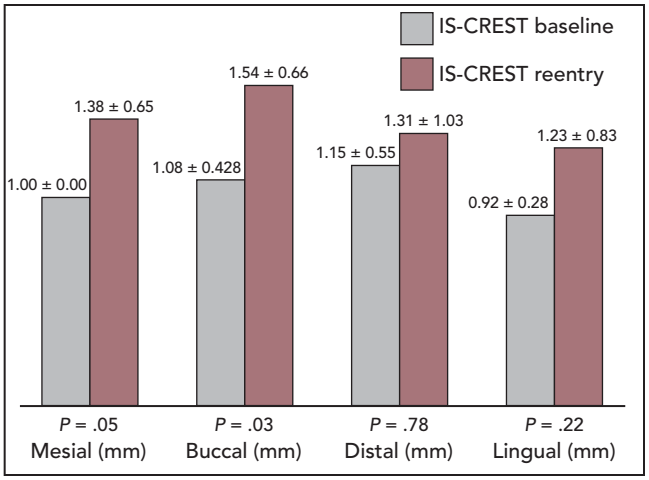

Fig 11b *IS-CREST: vertical distance from the implant shoulder* (IS) *to the most coronal extension of the alveolar crest* (CREST).

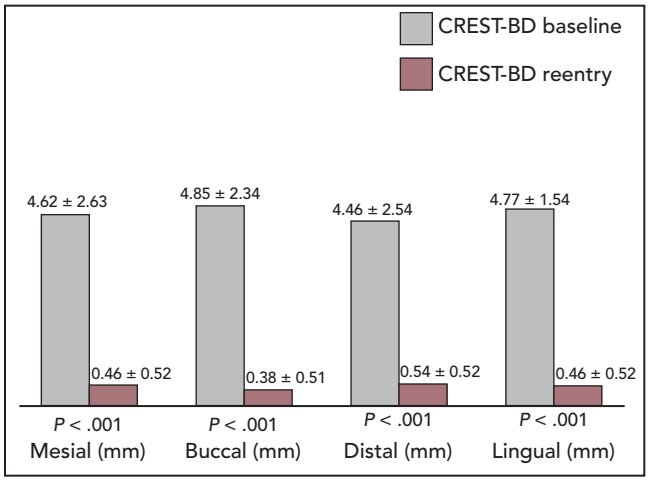

Fig 11c *CREST-BD: vertical distance from the most coronal extension of the alveolar crest* (CREST) *to the bottom of the bony defect* (BD).

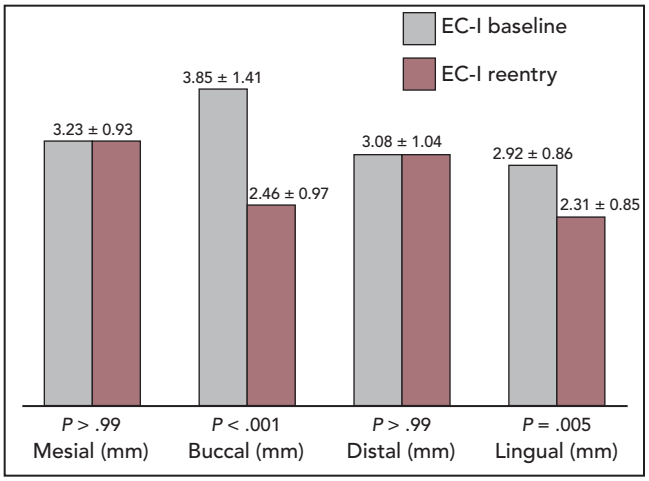

Fig 11d *EC-I: horizontal width from the external aspect of the socket wall at the level of the alveolar crest* (EC) *to the implant surface* (I).

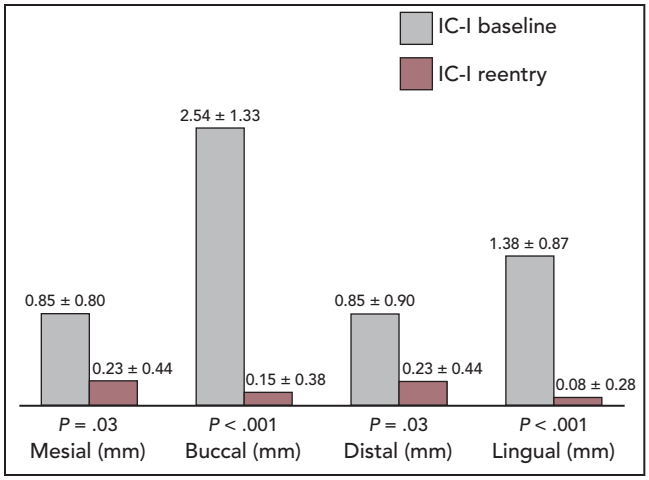

Fig 11e *IC-I: horizontal width from the internal aspect of the socket wall at the level of the alveolar crest* (IC) *to the implant surface* (I).

© 2014 BY QUINTESSENCE PUBLISHING CO, INC. PRINTING OF THIS DOCUMENT IS RESTRICTED TO PERSONAL USE ONLY.
NO PART MAY BE REPRODUCED OR TRANSMITTED IN ANY FORM WITHOUT WRITTEN PERMISSION FROM THE PUBLISHER.

Table 3 Defect filling and bone resorption (mean ± SD) at four sites per implant after surgical reentry at 6 months

Parameter	Mesial	Buccal	Distal	Lingual
Vertical defect filling (mm)	3.77 ± 2.45	4.00 ± 2.35	3.85 ± 2.54	4.00 ± 1.78
Vertical bone resorption (mm)	0.38 ± 0.65	0.46 ± 0.66	0.15 ± 0.90	0.31 ± 0.85
Vertical defect filling (%)	55.79 ± 28.92	68.77 ± 23.59	57.27 ± 30.78	67.03 ± 17.86
Vertical bone resorption (%)	7.51 ± 14.51	9.43 ± 16.54	1.15 ± 19.21	6.68 ± 17.76
Horizontal defect filling (mm)	0.62 ± 0.87	2.38 ± 1.19	0.62 ± 0.87	1.31 ± 0.85
Horizontal bone resorption (mm)	0.00 ± 0.00	1.38 ± 1.12	0.00 ± 0.00	0.62 ± 0.65
Horizontal defect filling (%)	76.92 ± 43.85	96.15 ± 9.39	80.77 ± 38.40	96.15 ± 13.87
Horizontal bone resorption (%)	0.00 ± 0.00	32.18 ± 22.66	0.00 ± 0.00	20.51 ± 21.41

Most occurrences of tooth loss (76.9%) were attributable to root fracture. The vast majority of immediate implants (92.3%) were placed in the premolar areas.

Surgical outcomes

At 6 months, all implants were successfully osseointegrated, yielding a survival rate of 100%. Figure 11 summarizes the mean change ± SD in vertical distances (IS-BD, IS-CREST, and CREST-BD) as well as in horizontal distances (EC-I and IC-I) assessed at four sites per implant (mesial, buccal, distal, and lingual) between baseline and surgical reentry at 6 months.

Statistically significant differences ($P < .05$) were observed in the mean changes in vertical distances IS-BD, CREST-BD, and IS-CREST between baseline and reentry (Figs 11a to 11c).

No statistically significant differences ($P > .99$) were observed for EC-I recorded at interproximal sites, while statistically significant differences ($P < .05$) were observed in the mean changes in horizontal distance EC-I between baseline and reentry at the buccal and lingual aspects (Fig 11d). Statistically significant differences were recorded ($P < .05$) for the IC-I change between baseline and 6 months reentry (Fig 11e).

Table 3 summarizes the mean change in the vertical and horizontal dimensions of marginal bone defects.

Discussion

The findings of this 6-month prospective study reported dimensional alveolar ridge changes following immediate transmucosal implant placement in fresh extraction sockets in combination with regenerative procedures. Previous studies have documented that the placement of an implant in fresh extraction sockets (type I placement[10]) failed to prevent the buccolingual ridge contractions that apparently always take place following tooth loss.[11–13] Botticelli and coworkers[11] have observed that 4 months after the removal of single teeth (maxillary and mandibular single-rooted teeth) and immediate implant placement without regenerative procedures, the buccolingual and apicocoronal dimensions of the marginal portion of edentulous site were substantially reduced. The authors observed a horizontal ridge reduction at 6 months of 56% at the buccal site and 30% at the lingual site. In the current study the horizontal ridge reduction at 6 months was somewhat smaller (32% at the buccal site and 20% at the lingual site)

© 2014 BY QUINTESSENCE PUBLISHING CO, INC. PRINTING OF THIS DOCUMENT IS RESTRICTED TO PERSONAL USE ONLY.
NO PART MAY BE REPRODUCED OR TRANSMITTED IN ANY FORM WITHOUT WRITTEN PERMISSION FROM THE PUBLISHER.

than that reported in the abovementioned studies. The reason for this discrepancy may be related to the management of peri-implant marginal defects by means of bone substitute and resorbable membrane. Hence, in such situations, the use of grafting materials covered by resorbable membrane may improve treatment outcomes. This finding is in agreement with the outcomes of Chen and coworkers.[14] The authors showed that, when compared with no graft, the combination of bone-derived xenograft and collagen membrane was able to limit horizontal ridge resorption, but not the vertical resorption of the buccal bone wall. In the current study the vertical bone crest resorption at the mesial and distal aspects amounted to 0.38 ± 0.6 mm and 0.15 ± 0.9 mm, respectively, while the horizontal bone crest resorption was not found. This phenomenon has been related to the presence of the periodontal ligament of the adjacent (ie, mesial and distal) teeth. In the present study the apical limit of the turned neck portion (1 mm) was placed at the level of the alveolar crest, and the Laser-Lok microtextured collar (0.9-mm microgroove with an 8 × 6–μm pitch and 0.9-mm microgroove with a 12 × 12–μm pitch) was positioned in a subcrestal position. Six months after tooth extraction and immediate implant placement with a concomitant regenerative procedure, the buccal and lingual bone walls were located 0.46 ± 0.66 mm and 0.31 ± 0.85 mm, respectively, apical to the apical limit of turned neck portion. The vertical buccal (0.46 ± 0.66 mm) and lingual (0.31 ± 0.85 mm) bone resorption was lower compared with the alveolar bone resorption reported by other studies.[14,15] This might suggest the hypothesis that the degree of vertical resorption of the socket walls that occurs after tooth extraction must be considered in conjunction with both the augmentation procedures and the implant surface, and that the laser microtextured surface might reduce the level of marginal bone resorption in cases of immediate implant placement associated with regenerative procedures. The authors realize that sample size of the present study is too small to demonstrate this hypothesis, and further studies are needed in which a control implant without laser microtexturing surface is used for comparison. In the present study, implants were placed with the Laser-Lok microtextured surface in a subcrestal position, while the apical limit of the turned neck portion was positioned at the level of the alveolar crest. This placement also may have allowed for stability and the attachment of the soft tissue. However, as reported by Koh and coworkers,[16] who have analyzed the influence of the crestal or subcrestal positioning of immediate implants with a laser-microtextured collar design in fresh alveolar sockets with a concomitant regenerative procedure, crestal bone and soft tissue levels showed no statistically significant differences whether the laser-microtextured collar was placed crestally or subcrestally.

In an experimental animal study[5] using immediate implant placement in fresh alveolar sockets without regenerative procedures, bone attachment to the 12 × 12–μm microgrooved surface and collagen fiber insertion perpendicular to the long axis of the implants over a 8 × 8–μm microgrooved surface have been documented histologically. Furthermore, bone-to-implant contact percentage was significantly higher in the microgrooved surface group than in the turned surface group. Based on the data obtained in this investigation,[5] the authors suggested that in the fresh extraction sockets a microgrooved implant surface may provide more favorable conditions for the attachment of hard and soft tissues and may reduce the level of marginal bone resorption and soft tissue recession.

Conclusions

This prospective study shows that the application of bovine-derived xenograft covered with a resorbable collagen membrane to fill marginal defects around implants placed immediately after tooth extraction limits the horizontal alveolar bone resorption but not the vertical ridge resorption. The use of a Laser-Lok microtextured collar may provide more favorable conditions for the attachment of hard and soft tissues.

© 2014 BY QUINTESSENCE PUBLISHING CO, INC. PRINTING OF THIS DOCUMENT IS RESTRICTED TO PERSONAL USE ONLY.
NO PART MAY BE REPRODUCED OR TRANSMITTED IN ANY FORM WITHOUT WRITTEN PERMISSION FROM THE PUBLISHER.

Acknowledgments

The authors reported no conflicts of interest related to this study.

References

1. Lang NP, Pun L, Lau KY, Li KY, Wong MC. A systematic review on survival and success rates of implants placed immediately into fresh extraction sockets after at least 1 year. Clin Oral Implants Res 2012; 23(suppl 5):39–66.
2. Nevins M, Nevins ML, Camelo M, Boyesen JL, Kim DM. Human histologic evidence of a connective tissue attachment to a dental implant. Int J Periodontics Restorative Dent 2008;28:111–121.
3. Ricci JL, Charvet J, Frenkel SR, et al. Bone response to laser microtextured surfaces. In: Davies JE ed. *Bone Engineering*. Toronto, ON: Em2; 2000: 282–294.
4. Alexander H, Ricci JL, Hrico GJ. Mechanical basis for bone retention around dental implants. J Biomed Mater Res B Appl Biomater 2007;23:200–210.
5. Shin SY, Han DH. Influence of a microgrooved collar design on soft and hard tissue healing of immediate implantation in fresh extraction sites in dogs. Clin Oral Implants Res 2010;21:804–814.
6. Listgarten MA, Lang NP, Schroeder HE, Schroeder A. Periodontal tissue and their counterparts around endosseous implants. Clin Oral Implants Res 1991;2:1–19.
7. Schupbach P, Glauser R. The defense architecture of the human periimplant mucosa: A histological study. J Prosthet Dent 2007;97(suppl 6):S15–S25 [erratum 2008;99:167].
8. O'Leary TJ, Drake RB, Naylor JE. The plaque control record. J Periodontol 1972; 43:38.
9. Claffey N, Nylund K, Kiger R, Garrett S, Egelberg J. Diagnostic predictability of scores of plaque, bleeding, suppuration and probing depth for probing attachment loss. 3 1/2 years of observation following initial periodontal therapy. J Clin Periodontol 1990;17:108–114.
10. Hämmerle CHF, Chen ST, Wilson TG Jr. Consensus statement and recommended clinical procedures regarding the placement of implants in extraction sockets. Int J Oral Maxillofac Implants 2004;19 (suppl I):26–28.
11. Botticelli D, Berglundh T, Lindhe J. Hard tissue alterations following immediate implant placement in extraction sites. J Clin Periodontol 2004;31:820–828.
12. Covani U, Cornelini R, Barone A. Bucco-lingual bone remodeling around implants placed into immediate extraction sockets: A case series. J Periodontol 2003;74: 268–273.
13. Covani U, Cornelini R, Barone A. Vertical crestal bone changes around implants placed into fresh extraction sockets. J Periodontol 2007;78:810–815.
14. Chen ST, Darby LB, Reynolds EC. A prospective clinical study of non-submerged immediate implants: Clinical outcomes and esthetic results. Clin Oral Implants Res 2007;18:552–562.
15. Gher ME, Quintero G, Assad D, Monaco E, Richardson AC. Bone grafting and guided bone regeneration for immediate dental implants in humans. J Periodontol 1994;65:881–891.
16. Koh RU, Oh TJ, Rudek I, et al. Hard and soft tissue change after crestal and subcrestal immediate implant placement. J Periodontol 2011;82:1112–1120.

© 2014 BY QUINTESSENCE PUBLISHING CO, INC. PRINTING OF THIS DOCUMENT IS RESTRICTED TO PERSONAL USE ONLY.
NO PART MAY BE REPRODUCED OR TRANSMITTED IN ANY FORM WITHOUT WRITTEN PERMISSION FROM THE PUBLISHER.