Clinical, Radiographic, and Esthetic Evaluation of Immediately Loaded Laser Microtextured Implants Placed into Fresh Extraction Sockets in the Anterior Maxilla: A 2-Year Retrospective Multicentric Study

Renzo Guarnieri, MD, DDS,* Roberto Placella, DDS,† Luca Testarelli, DDS, PhD,‡ Vincenzo Iorio-Siciliano, DDS, PhD,§ and Maurizio Grande, DDS||

Objectives: *To assess the clinical, radiographic, and esthetic outcomes of implants with a laser microtextured collar placed in the anterior region of the maxilla at the time of tooth extraction and immediately temporized.*

Methods: *Forty-six Tapered Internal Laser-Lok BioHorizons implants were immediately placed and immediately restored with nonfunctional loading in 46 patients (24 men and 22 women) with a thick gingival biotype, ideal gingival level/contour, and postextraction intact walls. Survival rate, cortical bone loss, and periimplant mucosal responses were evaluated at 6, 12, and 24 months.*

Results: *Survival rate was 95.6%. Mean mesial and distal marginal bone loss, 24 months after installation, were 0.58 mm (SD = 0.53; range, 0.17–1.15) and 0.57 mm (SD = 0.70; range, 0.42–1.10), respectively. A mesial and distal papilla regrowth mean of 1.8 and 1.5 mm, respectively, were found. The midfacial soft tissue levels showed 0.12 mm of mean recession after 24 months.*

Conclusion: *Immediate implants with a laser microtextured surface restored at the day of surgery, may be considered as a predictable procedure in terms of implant survival and hard and soft tissue remodeling. (Implant Dent 2014;23:144–154)*

Key Words: immediate implants, immediate loading, maxillary esthetic zone, tooth extraction/therapy, laser microtextured collar surface

In the past, dentistry's best answer to a missing tooth in the maxillary esthetic zone has been fixed bridgework, usually preceded by extraction and a removable provisional prosthesis.[1] In recent years, implantology has become a widely used technique that has revolutionized the practice of dentistry. Implants to support prosthetic reconstructions have become a common treatment modality in totally and partially edentulous patients. Even in cases of single tooth replacement, implant therapy has been demonstrated to be a predictable and successful treatment procedure in long-term prospective studies.[2–7] High clinical success rates obtained with the original implant protocols[8] have given clinicians and researchers confidence to further develop and refine the osseointegration technique, and consequently, implants have been used in increasingly more challenging situations and on broader indications.[9–11] Early and immediate loading of dental implants are techniques that are gradually gaining popularity.[12] A growing amount of data indicates a treatment protocol of tooth extraction immediately combined with implant placement, and loading can also be carried out successfully in patients with hopeless maxillary anterior teeth.[13–22] A high number of clinical studies have proved that good success and high implant survival rate can be obtained with immediate implants and immediate provisionalization proce-

*Private Periodontal and Implant Practice, Rome, Italy.
†Private Implant Practice, Brindisi, Italy.
‡Assistant Professor, Department of Dentistry, University "La Sapienza," Rome, Italy.
§Assistant Professor, Department of Periodontology, University "Federico II," Naples, Italy.
||Private Implant Practice, Rome, Italy.

Reprint requests and correspondence to: Renzo Guarnieri, MD, DDS, Via Paolo Emilio, 7 Int 5, Rome 00144, Italy, E-mail: renzoguarnieri@gmail.com

ISSN 1056-6163/14/02302-144
Implant Dentistry
Volume 23 • Number 2
Copyright © 2014 by Lippincott Williams & Wilkins
DOI: 10.1097/ID.0000000000000061

Copyright © Lippincott Williams & Wilkins. Unauthorized reproduction of this article is prohibited.



Fig. 1. Collar surface characteristics of Laser-Lok implant (on the left magnification 700×).

dures. However, an increasing number of publications are pointing out the esthetic risks of this therapy in terms of late development of buccal gingival recession and labial bone volume loss.[23–28] Recently, some strategies have been developed, using the principles of tissue engineering, in an effort to improve hard and soft tissue integration and to prevent crestal bone loss (CBL). One of these strategies is laser microtexturing surfaces with 8- and/or 12-µm grooves. Tissue culture studies have demonstrated cellular attachment by osteoblast and fibroblast to laser microgrooved surfaces,[29,30] and histological studies have confirmed the evidence of a mechanical attachment of connective tissue fibers to Laser-Lok microtexturing surface of implants (BioHorizons, Birmingham, AL) placed both in native bone[31] and in fresh extraction sites.[32] It has been suggested that this direct connective tissue attachment might serve as a physiological barrier to the apical migration of the junctional epithelium and prevent crestal bone resorption.[33] However, the biological and clinical impact of this novel kind of artificial attachment must continue to be investigated, especially in terms of stability over time and in terms of soft tissue level maintenance. Therefore, the objectives of this study were to assess clinical survival and success rates of Laser-Lok implants placed in the anterior zone of mandible at the time of tooth extraction with immediate nonfunctional temporization and to document the periimplant bone loss, soft tissue dynamics, and esthetic aspects 2 years after functional loading.

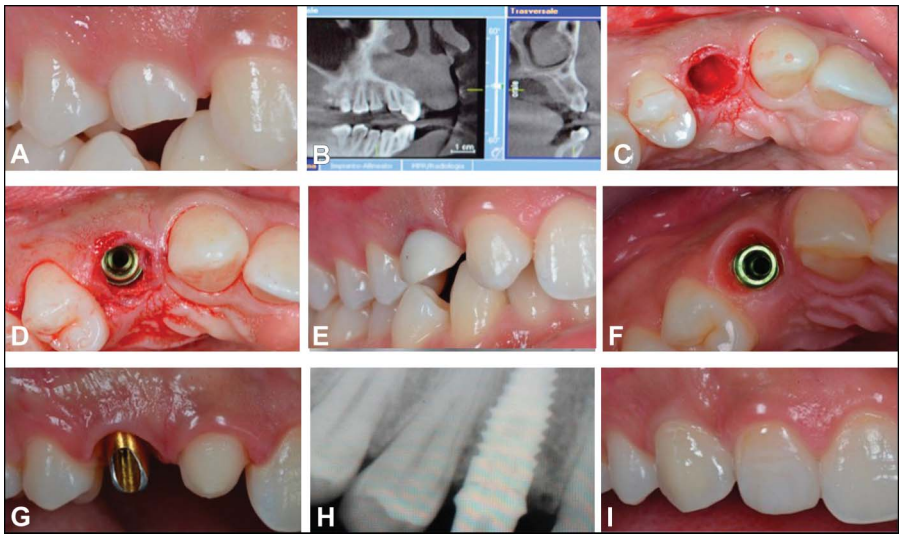

Fig. 2. Examples of implant placed in the anterior zone of maxilla at the time of tooth extraction with immediate temporization: (**A**) clinical situation, (**B**) preoperative radiograph, (**C**) atraumatic extraction, (**D**) implant placement, (**E**) immediate temporary crown, (**F**) periimplant tissue healing after 4 months; (**G**) final abutment; (**H**) radiograph after 2 years, (**I**) clinical situation after 2 years.

MATERIALS AND METHODS

Patients

All patients considered for inclusion in the study were examined and treated between January 2007 and December 2010 in dental clinics located in Italy with extensive experience in the implant treatment of patients. All patients signed a written informed consent form. The study group included 46 implants that were placed in 46 patients (24 men and 22 women) with a mean age of 45.5 years (range, 26–60 years) referred for implant therapy, who required single tooth rehabilitation with implants placed in fresh anterior maxilla extraction sockets with immediate nonfunctional loading. Patients were in a good general health condition, with no chronic systemic disease or smoking habits. Patients were excluded if any of the following were evident: bruxism, unstable posterior occlusion, untreated caries, uncontrolled periodontal disease, adjacent teeth that exceeded Class 1 mobility, unrealistic expectations for the treatment, or inability or unwillingness to return for follow-up visits. All patients provided informed consent to participate in this study, and treatments were performed in accordance with the Helsinki Declaration.

Teeth

In the selected patients, teeth indicated for removal had to demonstrate at least 4 mm of bone beyond the root apex and at least 10 mm height and 4.5 mm width of available bone. Teeth with unmanageable recession and/or without the labial or lingual plate, as described in 1993 by Gelb,[34] or teeth with active periapical lesions or active periodontal lesions were excluded. Indications for tooth extraction and immediate implant placement included trauma, root fractures,

Copyright © Lippincott Williams & Wilkins. Unauthorized reproduction of this article is prohibited.

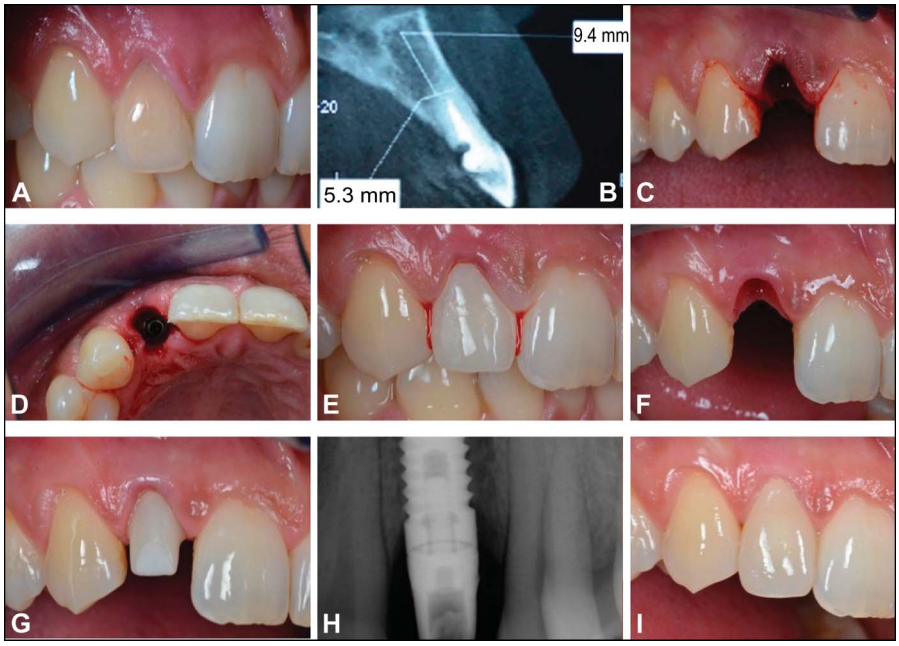

Fig. 3. Examples of implant placed in the anterior zone of maxilla at the time of tooth extraction with immediate temporization: (**A**) clinical situation, (**B**) preoperative radiograph, (**C**) atraumatic extraction, (**D**) implant placement, (**E**) immediate temporary crown, (**F**) periimplant tissue healing after 4 months; (**G**) final abutment; (**H**) radiograph after 2 years, (**I**) clinical situation after 2 years.

endodontic failure, nonrestorable crowns, and the presence of deciduous teeth in cases of tooth agenesis. Radiolucency at the apex without signs of activity (pain, fistula, redness, and suppuration) was also included in the indications. Oral examinations focused on the "smile line," intra-arch relationship, buccolingual width, and maxilla-mandibularly relationship. Tomograms and periapical radiographs were evaluated for mesiodistal width, residual bone beyond the apex, socket width, and root angulation.

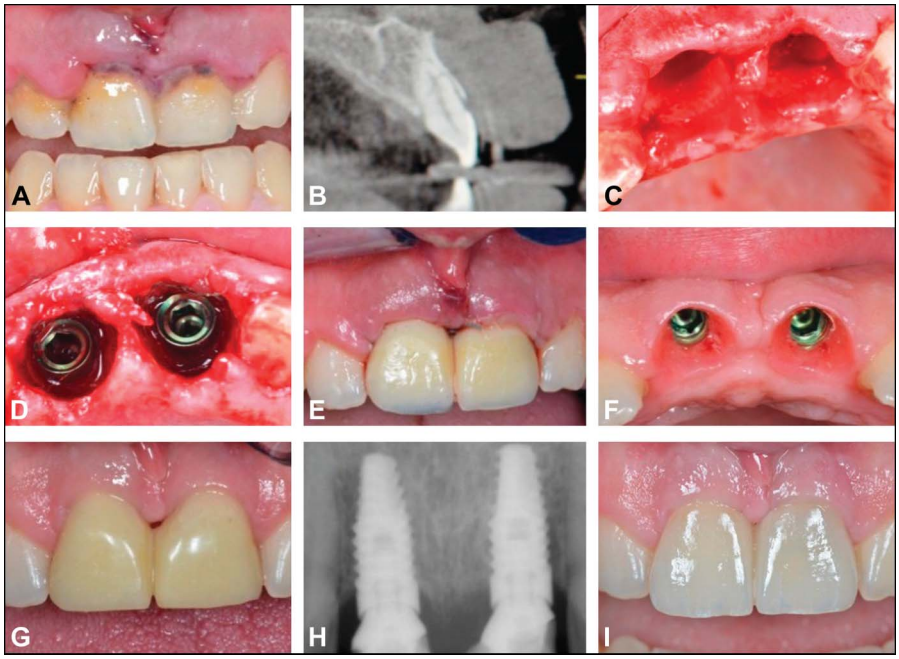

Fig. 4. Examples of implant placed in the anterior zone of maxilla at the time of tooth extraction with immediate temporization: (**A**) clinical situation, (**B**) preoperative radiograph, (**C**) atraumatic extraction, (**D**) implant placement, (**E**) immediate temporary crown, (**F**) periimplant tissue healing after 4 months; (**G**) final abutment; (**H**) radiograph after 2 years, (**I**) clinical situation after 2 years.

Implants

BioHorizons Laser-Lok Tapered Internal implants (BioHorizons, Birmingham, AL) were used in the study. The body of the implant has been blasted with resorbable blast media to create a surface roughness between 0.72 and 1.34 μm. The implant collar is comprised of 0.3 mm of smooth, turned surface, 0.7 mm of 8 μm microgrooves, and 0.8 mm of 12 μm microgrooves (Fig. 1). A total of 46 implants with lengths of 9 to 15 mm and a diameter of 3.8 to 4.6 mm were inserted.

Surgical Procedure

Implants were placed using the surgical procedure recommended by the manufacturer. One gram of amoxicillin was administered 1 hour before surgery. Chlorhexidine rinses were used before the surgery, and amoxicillin (500 mg, 3 times daily) was continued for 5 to 7 days after surgery. After local anesthesia, no flaps were designed and no incisions were made. Teeth were carefully removed and the sockets debrided. The distance between the gingival margin and the bone was measured with a periodontal probe. This distance was added to the desired implant length, and the buccal gingival margin served as the height reference point. The longest possible implants were placed at the most coronal part of the alveolar crest, and special attention was paid to 3-dimensional positioning of the implants as described by Buser et al.[35] Final implant position was carried out by using a torque driver (Precise Adjustable Torque Wrench; BioHorizons). The distance between the coronal part of the implant and the gingival margin was used to choose the healing abutment height. In all the sites, there was no need for suturing.

Prosthetic Procedure

A temporary resin crown was made on the temporary abutment, connected

Copyright © Lippincott Williams & Wilkins. Unauthorized reproduction of this article is prohibited.

Table 1. Marginal Bone Loss in Relation to BSL at T1 (6 months), T2 (1 year), and T3 (2 years)

Location	T1	T2	T3
Mesial bone loss, mean ± SD (mm)	0.41 ± 0.26 (0.10–0.97)	0.51 ± 0.50 (0.17–1.05)	0.58 ± 0.53 (0.17–1.15)
Distal bone loss, mean ± SD (mm)	0.47 ± 0.24 (0.08–0.85)	0.53 ± 0.68 (0.32–1.00)	0.57 ± 0.70 (0.42–1.10)

to the implant within 1 hour, and adjusted to avoid any direct occlusive contacts. Regular examinations were performed every 2 weeks with special attention to occlusion and hygiene. After 6 months, when tissue conditions were expected to have stabilized, the provisional abutments were replaced with definitive abutments, and the provisional crowns were replaced with ceramic crowns. Implant stability was measured and confirmed using a Periotest (Siemens AG, Bensheim, Germany). Sample cases are illustrated in Figures 2, 3, and 4.

Radiographic Examination

Intraoral radiographs were taken after insertion of the implant [baseline {BSL}] and 6 (T1), 12 (T2), and 24 (T3) months thereafter using a paralleling technique (Dentsply RINN, Elgin, IL) for all the radiographs. Each radiograph was performed using a personalized radiographic template for every patient and examined by an independent radiologist. The radiographs were then digitalized using a dedicated scanner (HP 3000) with a resolution of 2048 × 3072 lines and converted into JPG files. A software package (AutoCAD 2000) was used to measure CBL. Vertical lines were drawn from the top of the implants to the crestal bone to measure the crestal bone level. Then, CBL was calculated as the difference in crestal bone level at follow-up and at the baseline.

Follow-up Examination

The following clinical variables were recorded:

1. Plaque score: A dichotomous score was given (0 = no visible plaque at the soft tissue margin; 1 = visible plaque at the soft tissue margin) at 4 sites per implant (mesial, midfacial, distal, and palatal).
2. Probing depth: It was measured to the nearest 0.5 mm at 4 sites per implant (mesial, midfacial, distal, and palatal) using a manual probe (CP 15 UNC; Hu-Friedy, Chicago, IL).
3. Bleeding on probing: A dichotomous score was given (0 = no bleeding; 1 = bleeding) at 4 sites per implant (mesial, midfacial, distal, and palatal).
4. The pink esthetic score (PES)[36] was used to evaluate the esthetic outcome of the periimplant soft tissues after 24 months. This index includes 7 variables: mesial papilla, distal papilla, midfacial level, midfacial contour, alveolar process deficiency, soft tissue color, and soft tissue texture. Each parameter is assessed with a 0-1-2 score with 2 being the best and 0 being the worst score. Papilla levels: The levels were recorded by means of an acrylic stent provided with direction grooves. Papilla level (mesial and distal) was defined as the distance from the top of the groove to the top of the papilla measured to the nearest 0.5 mm using a manual probe. Midfacial mucosa level: The level of the periimplant mucosa at the midfacial aspect of the tooth/restoration was measured using the same acrylic stent provided with a central direction groove. The midfacial level was defined as the distance from the top of the groove to the first contact with the periimplant mucosa measured to the nearest 0.5 mm using a manual probe.
5. The white esthetic score (WES)[37] was used to evaluate the esthetic outcome of the visible part of the implant restoration. This index includes 5 variables: tooth form, tooth volume, tooth color including the assessment of hue and value, tooth texture, and translucency. Again, each parameter is assessed with a 0-1-2 score with 2 being the best and 0 being the worst score. Thus, a maximum score of 10 can be reached. All variables are assessed by comparison with a reference tooth, which is the contralateral tooth for incisor and cuspid replacements and the neighboring premolar for premolar replacements. As proposed by Cosyn et al,[28] a score of 6/10 was considered acceptable, and a score of 9/10 was considered (almost) perfect. The overall esthetic outcome was assessed by combining the results of the PES and WES. If PES ≥12 and WES ≥9, the treatment was considered (almost) perfect. If PES <8 and/or WES <6, the result was considered a failure.

Implant Survival Criteria

An implant was considered surviving if it is clinically stable, complies with the function of supporting the prosthesis, and was causing no discomfort to the patient. Failure was defined as removal of an implant for any reason.

Statistical Analysis

Data analysis was performed using the patient as the experimental unit. For

Table 2. Changes in the Periimplant Soft Tissues Compared to Preoperative Values at T1 (6 months), T2 (1 year), and T3 (2 years)

Location	T1	T2	T3
Mesial papilla, mean ± SD (mm)	–0.14 ± 0.64 (1.8 to 0.6)	–0.02 ± 0.7 (–1.2 to 1.5)	0.04 ± 0.58 (–0.4 to 1.8)
Distal papilla, mean ± SD (mm)	–0.12 ± 0.78 (–2 to 1.1)	–0.04 ± 1.20 (–1.65 to 2.0)	0.03 ± 0.83 (–1.2 to 2.0)
Midfacial mucosa level, mean ± SD (mm)	–0.20 ± 0.76 (–1.7 to 0.5)	–0.16 ± 0.60 (–1.5 to 1.0)	–0.12 ± 0.61 (–1.2 to 1.1)

Negative value indicates recession in relation to the preoperative status.

Copyright © Lippincott Williams & Wilkins. Unauthorized reproduction of this article is prohibited.

Table 3. Esthetic Outcome in Relation to the Preoperative Status

		PES								WES						
Patient	Implant Site	Mesial Papilla	Distal Papilla	Midfacial Mucosa Level	Midfacial Contour	Alveolar Process Deficiency	Soft Tissue Color	Soft Tissue Texture	Total PES	Tooth Form	Tooth Volume	Tooth Color	Tooth Texture	Translucency	Total WES	Total PES + WES
1	11	2	2	2	1	2	2	0	11	0	1	2	1	2	6	17
2	11	1	1	2	2	2	2	2	12	2	2	1	0	2	7	19
3	13	2	2	2	1	2	1	2	12	2	2	2	2	2	10	22
4	12	2	2	2	2	2	2	2	14	2	2	2	2	2	8	24
5	21	2	2	1	2	2	2	2	13	1	1	1	2	2	7	20
6	13	1	1	0	1	0	0	1	4	2	2	2	2	2	10	14
7	23	2	2	1	1	2	2	2	12	2	2	2	2	2	10	22
8	12	2	2	2	2	2	2	2	14	1	1	1	1	1	5	19
9	12	2	2	1	2	2	2	2	13	2	2	2	2	2	10	23
10	11	0	0	1	1	1	1	2	6	2	2	2	2	2	10	16
11	21	2	2	2	2	2	2	2	14	1	1	1	1	2	7	22
12	13	1	1	1	1	1	1	1	7	2	2	0	2	2	10	15
13	12	2	2	2	1	2	2	2	13	2	2	2	2	2	9	23
14	23	2	2	2	2	2	2	2	14	2	2	2	2	2	10	24
15	11	2	2	2	2	2	2	2	14	2	1	2	1	2	8	22
16	12	2	1	1	2	0	2	2	10	2	2	2	2	2	10	20
17	22	2	2	2	2	2	2	2	14	2	2	2	2	2	10	24
18	13	2	2	2	2	2	2	2	14	2	2	2	2	2	10	24
19	11	2	2	2	2	0	2	1	11	2	2	2	2	2	10	21
20	12	2	2	2	2	2	2	2	14	2	2	2	0	2	8	22
21	21	2	2	2	0	2	2	2	12	1	2	2	1	2	7	20
22	13	1	1	2	2	2	2	0	10	2	2	1	1	2	8	18
23	22	2	2	2	2	2	2	2	13	2	2	2	2	2	10	24
24	22	2	2	2	2	2	2	2	14	2	2	2	2	0	8	22
25	21	2	2	2	2	2	2	2	14	1	1	1	2	2	7	21
26	11	1	1	0	1	1	1	1	6	2	2	2	2	2	10	16
27	23	2	2	2	2	2	2	2	14	2	2	2	2	2	10	24
28	21	2	2	2	2	2	2	2	14	1	1	1	1	1	5	19
29	12	2	2	2	2	2	2	2	14	2	2	2	2	2	10	24
30	11	1	1	1	1	1	1	2	8	2	2	2	2	2	10	18
31	21	2	2	2	2	2	2	2	14	2	2	1	1	2	8	22
32	23	1	1	1	1	1	1	1	7	2	2	2	2	2	10	17
33	13	2	2	2	1	2	2	2	13	2	2	2	2	1	9	22
34	12	2	2	2	2	2	2	2	14	2	2	2	2	2	10	24
35	21	2	2	2	2	2	2	2	14	2	2	2	1	2	8	23
36	21	2	1	1	2	2	2	2	12	2	2	2	2	2	10	22
37	11	2	2	2	2	2	2	2	14	2	2	2	2	2	10	24
38	22	2	2	2	2	2	2	2	14	2	2	2	2	2	10	24

(continued on next page)

Copyright © Lippincott Williams & Wilkins. Unauthorized reproduction of this article is prohibited.

Table 3. (Continued)

		PES								WES							
Patient	Implant Site	Mesial Papilla	Distal Papilla	Midfacial Mucosa Level	Midfacial Contour	Alveolar Process Deficiency	Soft Tissue Color	Soft Tissue Texture	Total PES	Tooth Form	Tooth Volume	Tooth Color	Tooth Texture	Translucency	Total WES	Total PES + WES
39	23	2	2	2	2	1	2	1	12	2	2	2	2	2	10	22
40	13	2	2	2	2	2	2	2	14	2	2	2	2	2	10	24
41	12	2	2	2	2	2	2	2	14	1	1	2	2	2	6	22
42	11	2	2	2	2	2	2	2	14	2	2	1	1	2	8	22
43	13	2	2	2	1	2	2	2	13	2	2	2	2	2	10	23
44	23	2	2	2	2	2	2	2	14	2	2	2	2	1	9	23
Mean		1.79	1.75	1.70	1.68	1.72	1.81	1.72	12.25	1.79	1.83	1.75	1.68	1.81	8.81	21.3

all parameters, mean values were calculated, if applicable. Descriptive statistics also included frequency distributions for papillae and midfacial mucosa level. The changes between the BSL and 2-year reassessment were examined using the Wilcoxon signed ranks test. The level of significance was set at 0.01.

RESULTS

Implant Survival and Complications

Two implants were lost during the 6-month follow-up observation period (tooth location 22: diameter, 3.8 mm; length, 10.5 mm; and tooth location 13: diameter, 4.6 mm; length, 12 mm) and not included in the final study group. Besides these 2 early failures, all implants remained well integrated resulting in a 95.6% of implant survival rate after 2 years of function. Regarding other complications, 1 permanent crown lost retention at 24 months of follow-up and was recemented. There were no other technical or biological complications.

Hard Tissue Parameters

Table 1 shows mean bone loss from BSL. At T1 (6 months), the average change in bone level mesially and distally was 0.41 mm (SD = 0.26; range, 0.10–0.97) and 0.47 mm (SD = 0.24; range, 0.08–0.85), respectively. The corresponding mean change at T2 (1 year) was 0.51 mm (SD = 0.50; range, 0.17–1.05) mesially and 0.53 mm (SD = 0.68; range, 0.32–1.00) distally; and at T3 (2 years) was 0.58 mm (SD = 0.53; range, 0.17–1.15) mesially and 0.57 mm (SD = 0.70; range, 0.42–1.10) distally.

Soft Tissue Parameters

Throughout the study period, mean plaque levels remained low (<15%) indicating good oral hygiene. Between 6 months and 2 years, a significant reduction in probing depth from 2.42 to 1.52 mm occurred coinciding with a drop in significant bleeding on probing from 36% to 22%.

Dimensional changes in the soft tissue outline around the implant restorations in relation to the status before tooth extraction are reported in Table 2. Mesial papillae showed a significant regrowth between years 1 and 2 with a mean regrowth of 1.8 mm from the preoperative status. A similar trend was found for distal papillae resulting in a regrowth of 1.5 mm. At 2-year follow-up, mesial papilla loss (>1 mm) was found in 1/44 (2.7%) and distal papilla loss (>1 mm) in 1/44 (2.7%) cases. In 36/44 (81.8%) patients, mesial papillae, and in 34/44 (77.2%) patients, distal papillae, regained at least their original height.

The midfacial mucosa level did not alter significantly between the BSL and 2-year reassessment. At study termination, a mean recession from the preoperative status of 0.12 mm was found (Table 2). At 2-year follow-up,

Table 4. Summarized Esthetic Outcome in Relation to the Preoperative Status of the 44 Included Implants

Parameter PES	Value 0	Value 1	Value 2
Mesial papilla	1	7	36
Distal papilla	1	9	34
Midfacial mucosa level	2	9	33
Midfacial contour	1	12	31
Alveolar process deficiency	3	6	35
Soft tissue color	1	6	37
Soft tissue texture	2	6	36

Parameter WES	Value 0	Value 1	Value 2
Tooth form	1	7	36
Tooth volume	0	8	36
Tooth color	1	9	34
Tooth texture	1	10	33
Translucency	1	4	39

Copyright © Lippincott Williams & Wilkins. Unauthorized reproduction of this article is prohibited.

Table 5. Summarized PES and WES of the 44 Included Implants

PES	Mesial Papilla	Distal Papilla	Midfacial Mucosa Level	Midfacial Contour	Alveolar Process Deficiency	Soft Tissue Color	Soft Tissue Texture	Total Score (Maximum 14)
Maximum	2	2	2	2	2	2	2	14
Minimum	0	0	0	0	0	0	0	6
Mean	1.79	1.75	1.70	1.68	1.72	1.81	1.72	12.25
SD	0.46	0.49	0.55	0.52	0.59	0.45	0.52	2.68

WES	Tooth Form	Tooth Volume	Tooth Color	Tooth Texture	Translucency	Total Score (Maximum 10)
Maximum	2	2	2	2	2	10
Minimum	1	0	1	1	1	5
Mean	1.79	1.83	1.75	1.68	1.86	8.81
SD	0.46	0.37	0.49	0.56	0.41	1.53

midfacial recession (>1 mm) was found in 2/44 (4.5%) cases. In 32/44 (72.7%) patients, the midfacial mucosa regained at least its original level.

In Table 3, detailed values of PES and WES of all 44 implants are shown. Table 4 summarizes results of all criteria of the PES and of the WES. Mesial papilla level, soft tissue color, and texture were most satisfying showing a perfect match with the corresponding tooth in 36/44 (81.8%), in 37/44 (84%), and in 36/44 (81.8%) cases, respectively. Unfavorable results were most prevalent for the alveolar process showing severe deficiency in 3/44 (6.8%) cases. Translucency and tooth color/volume were most satisfying indicating an ideal result in 39/44 (88.6%) and 36/44 (81.8%) cases, respectively. Unfavorable results were most prevalent for tooth texture with a mismatch in 11/44 (25%) and a perfect result in 33/44 (75%) cases.

The overall esthetic outcome was assessed by combining the results of the PES and WES (Tables 4 and 5). Thirty (68%) out of 44 single implant treatments showed a successful result (PES ≥12 and WES ≥9). An acceptable result (PES, 8–11 and WES, 6–8) was found for 14/44 (32%) cases. The esthetic outcome was unfavorable for 0/20 (0%) single implant treatments.

DISCUSSION

Studies on immediate implant placement and loading are often based on implant survival rates. This is indeed a major outcome determining treatment success to a high extent. In this study, 95.6% of the implants survived after 2 years of loading. A similar overall survival rate (95.5%) of implants in the esthetic zone in the short time period is reported by meta-analysis of a recent literature review.[27] Our results are in agreement with these literature data. They confirm that the timing of implant placement and loading relative to tooth extraction in the esthetic zone does not seem to result in a different implant survival rate than conventionally installed single implants after a comparable observation period.[38–40] In the anterior zone, the success of single implant therapy is also determined by the long-term quality of survival, which is dictated by a mixture of several factors including esthetics. Although the esthetic aspect of implant-supported restorations is not included in previous descriptions of implant success criteria,[41] this aspect has attracted more attention in recent years. Optimal esthetics and preservation of hard and soft periimplant tissues is now mandatory in modern implantology. One of the factors affecting the long-term quality of survival is the level of periimplant marginal bone loss because periimplant bone loss may induce pocket formation and could be unfavorable for the long-term health of the periimplant tissues.[42] In this study, the mesial marginal bone loss after 2 years of loading was 0.58 mm (SD = 0.53; range, 0.17–1.15), and the distal marginal bone loss was 0.57 mm (SD = 0.70; range, 0.42–1.10). Little data have been published on levels of the longitudinal radiographic marginal bony changes after immediate implant placement and immediate provisional restoration.[26,43–45] De Rouck et al[26] reported the highest percentage of marginal bone loss occurred in the first functioning year, with bone levels becoming stable afterward. Moreover, half of the bone loss measured in the first year occurred in the first 3 months. In that study, implants with a standard machined collar were used showing, from 3 to 12 months, a marginal bone loss of 0.51 ± 0.24 mm to 0.95 ± 0.35 mm at the mesial site and 0.52 ± 0.46 mm to 0.79 ± 0.39 mm at the distal site. Our results are partially in agreement with data reported by De Rouck, as they show that the CBL occurs mostly within the third month. However, using implants with a laser microtextured collar in this study, we found a lower marginal bone loss after 1 year of function [mesial of 0.58 mm {SD = 0.53; range, 0.17–1.15} and distal of 0.57 mm {SD = 0.70; range, 0.42–1.10}], compared with data of De Rouck et al. Previous clinical studies have shown that implants with a laser microtextured collar yield limited crestal bone remodeling.[33,46,47] Using a standard placement and loading protocol, Pecora et al[46] showed implants with a laser microtextured collar were numerically superior to control implants with a machined collar in CBL at each month after month 1 and achieved nominal

Copyright © Lippincott Williams & Wilkins. Unauthorized reproduction of this article is prohibited.

statistical significance at month 7 through month 37. Furthermore, this difference was seen to increase at each successive visit. Similar results have been reported by Botos et al[33] who instead compared implants with laser microtextured and machined collar surfaces using a standard and immediate loading protocol. In the immediately loaded group, implants with a laser microtextured collar showed at 1-year follow-up exhibiting a mean CBL of 0.42 mm, compared with 1.13 mm for implants with a machined collar. Similar results have been reported in this present study, but they also seem to indicate that implants with a laser microtextured collar surface may also preserve crestal bone when implants are immediately placed and loaded.

Periimplant soft tissue conditions are others factors that have gained a lot of attention on the long-term quality of survival. In this study, mesial and distal papillae showed a significant regrowth between BSL and 2 years, with mesial papillae exhibiting a mean regrowth of 1.8 mm, and distal papillae a mean regrowth of 1.5 mm. These data are in agreement with previous data published on immediately placed and provisionally restored single tooth maxillary implants, which showed a lower papillae loss in comparison with conventional implant treatment.[26,48–54] However, because the presence of papillae is believed to be primarily related to the bone level at the adjacent tooth,[15,49,50] the proximal papilla can be maintained if the bone peak remains intact at the time of tooth loss. Our data showed that midfacial soft tissue levels remained fairly stable over time, with 0.12 mm of mean recession compared with the preoperative status. These results are in line with other studies in which limited recession has been found after immediate implantation and immediate provisionalization strategy.[14,17,20,26,44,55,56] In contrast, using the same protocol, other studies reported a high risk of advanced midfacial recession.[25,57–60] The contradiction about the risk for advanced midfacial recession present in literature may be explained by disparities in case selection (buccal bone crest intact or not, presence or absence of unmanageable recession), in study design (prospective vs retrospective), in recording procedure (using a stent or standardized digital slides with fixed reference points or not), in surgical aspects (surgeons' experience; implant type), and in restorative aspects (immediate/early provisionalization or not). We realize that the sample size of our study is too small to demonstrate whether immediate implant placement with immediate placement of the temporary crown may allow the preservation of the midfacial soft tissue, and more prospective studies monitoring soft tissue dynamics over longer time periods and encompassing a larger number of observers and a larger number of implants are needed. To our knowledge, the available literature documenting the esthetic characteristics of single implant crowns using objective criteria is rather scarce.[37,54,58,59,61–64] The published data report optimal esthetics seems difficult to achieve despite patients were selected by stringent criteria and treated by experienced clinicians. Some studies[37,58,59,63,64] reported a (almost) perfect soft tissue outcome (PES $\geq$12) in 19% to 39% of the cases and a (almost) perfect implant crown outcome (WES $\geq$9) in 18% to 50% of the cases. These literature data are quite lower if compared with the PES/WES results documented in this study, as 30 (68%) out of 44 cases showed a (almost) perfect result (PES $\geq$12 and WES $\geq$9). The good esthetic outcomes found in our study may also be related to the strict selection inclusion criteria. In all selected patients, extraction sites had to demonstrate intact walls and an ideal gingival level/contour. Moreover, the most frequent reasons of extraction in this study were endodontic failures and nonrestorable crowns, which would not lead to severe marginal bone loss. The fact that implants with a laser microtextured collar yield minimal bone loss could also be an explanation for the tissue preservation we observed, albeit, the impact and the additional value of a microtextured implant collar on periimplant soft tissue remodeling is currently unclear. *In vitro* studies have investigated the effect of a microgrooved surface with features in the range of 2 to 12 μm regarding attachment, spreading, orientation, and growth of fibroblast and osteoblast precursors.[65,66] Surfaces with 12-μm grooves showed the best potential for inhibition of fibroblast cell growth relative to osteoblast cell growth, whereas surfaces with 8-μm grooves showed the most effective inhibition of cell migration across the grooves. Subsequent histologic studies on this kind of surface have shown a mechanical attachment of connective tissue fibers on the laser microtexturing surface of implants placed both in native bone[31] and in fresh extraction sites.[32] The most important aspects of this physical connective tissue attachment is that its position is determined by the laser microgrooves layout,[67] and the connective tissue fibers are perpendicularly oriented to the implant surface and act as a seal to apical migration of gingival epithelial cells and fibroblasts. These studies support the hypothesis that this kind of surfaces can be used to control bone and soft tissue responses to implant surface and that it might act to establish a predetermined site to attract a physical connective tissue attachment, restrict apical migration of gingival epithelium, and preserve the coronal level of bone. This study did not include histologic evaluation of a physical connective tissue attachment to the implant collar. However, the lower mean marginal bone loss documented, compared with that reported in literature using implants with a standard machined collar, seems to confirm the hypothesis that the laser microtextured collar surface may preserve the periimplant coronal bone level.

One of the hypotheses of this study was, from a theoretical point of view, hard and soft periimplant tissue might be preserved because there is only 1 surgical phase, and a provisional restoration offers an instant mechanical support to the papillae and midfacial gingival tissues. This treatment protocol offers obvious advantages such as time gain, immediate esthetics, and comfort, although it must be remembered that immediate implantation may not avert postextraction hard tissue remodeling possibly resulting in additional soft tissue remodeling.[23,68] However, even if the hard and soft tissue remodeling seem hardly affected by the moment of implant placement relative to tooth extraction, the amount of tissue remodeling seems to be determined also by many other factors

Copyright © Lippincott Williams & Wilkins. Unauthorized reproduction of this article is prohibited.

including: surgeon's experience, thin/scalloped biotype, buccal bone crest intact or not, implant type, oral facial implant positioning, hard and/or soft tissue grafting or not, and restorative aspects.[57,58,69–71] Because of the heterogeneity of these factors, the impact of the immediate implantation and provisionalization treatment strategy on the soft tissues surrounding single implant restorations remains controversial and additional studies are needed. Needless to say, clinical experience and careful case selection of only considering low-risk patients with a thick gingival biotype, ideal gingival level/contour, and intact socket walls at the time of tooth extraction are deemed mandatory for this kind of treatment strategy. As a retrospective analysis, this study lacks the random allocation of patients into treatment and control groups, and thereby represents a low level of clinical significance. However, studies such as this often represent the first line of clinical evidence, which underscores its clinical value. Prospective, randomized, and controlled clinical studies are needed to establish if laser microtextured implant collar surface, compared with machined implant collar surface, might preserve periimplant hard and soft tissue when using an immediate implantation and provisionalization protocol.

CONCLUSION

In conclusion, within the limits of this study, the results showed that immediate implants with laser microtextured surface restored at the day of surgery may be considered in the mid-long term a predictable procedure in terms of implant survival and hard and soft tissue remodeling.

DISCLOSURE

The authors claim to have no financial interest, either directly or indirectly, in the products or information listed in the article.

ACKNOWLEDGMENTS

The study was supported by Classimplant S.R.L., Rome, Italy, providing materials and funding.

REFERENCES

1. Studer S, Pietrobon N, Wohlwend A. Maxillary anterior single-tooth replacement: Comparison of three treatment modalities. *Pract Periodontics Aesthet Dent.* 1994;6:51–60;quiz 62.

2. Jemt T, Lekholm U, Grondahl K. 3-year follow up study of early single implant restorations ad modum Brånemark. *Int J Periodontics Restorative Dent.* 1990;10:340–349.

3. Henry PJ, Laney WR, Jemt T, et al. Osseointegrated implants for single-tooth replacement: A prospective 5-year multicenter study. *Int J Oral Maxillofac Implants.* 1996;11:450–455.

4. Buser D, Mericske-Stern R, Bernard JP, et al. Long-term evaluation of non-submerged ITI implants. Part 1: 8-year life table analysis of a prospective multi-center study with 2359 implants. *Clin Oral Implants Res.* 1997;8:161–172.

5. Palmer RM, Palmer PJ, Smith BJ. A 5-year prospective study of Astra single tooth implants. *Clin Oral Implants Res.* 2000;11:179–182.

6. Berglundh T, Persson L, Klinge B. A systematic review of the incidence of biological and technical complications in implant dentistry reported in prospective longitudinal studies of at least 5 years. *J Clin Periodontol.* 2002;29(suppl 3):197–212.

7. Wennström JL, Ekestubbe A, Gröndahl K, et al. Implant-supported single-tooth restorations: A 5-year prospective study. *J Clin Periodontol.* 2005;32:567–574.

8. Albrektsson T, Brånemark PI, Hansson HA, et al. Osseointegrated titanium implants. Requirements for ensuring a long-lasting, direct bone-to-implant anchorage in man. *Acta Orthop Scand.* 1981;52:155–170.

9. Ostman PO, Hellman M, Sennerby L. Immediate occlusal loading of implants in the partially edentate mandible: A prospective 1-year radiographic and 4-year clinical study. *Int J Oral Maxillofac Implants.* 2008;23:315–322.

10. Ostman PO, Hellman M, Sennerby L. Direct implant loading in the edentulous maxilla using a bone density-adapted surgical protocol and primary implant stability criteria for inclusion. *Clin Implant Dent Relat Res.* 2005;7(suppl 1):S60–S69.

11. Testori T, Meltzer A, Del Fabbro M, et al. Immediate occlusal loading of Osseotite implants in the lower edentulous jaw. A multicenter prospective study. *Clin Oral Implants Res.* 2004;15:278–284.

12. Nkenke E, Fenner M. Indications for immediate loading of implants and implant success. *Clin Oral Implants Res.* 2006;17(suppl 2):19–34.

13. Chaushu G, Chaushu S, Tzohar A, et al. Immediate loading of single-tooth implants: Immediate versus non-immediate implantation. A clinical report. *Int J Oral Maxillofac Implants.* 2001;16:267–272.

14. Wöhrle PS. Single-tooth replacement in the aesthetic zone with immediate provisionalization: Fourteen consecutive case reports. *Pract Periodontics Aesthet Dent.* 1998;10:1107–1114;quiz 1116.

15. Hui E, Chow J, Li D, et al, Immediate provisionalization for single-tooth implant replacement with Brånemark system: Preliminary report. *Clin Implant Dent Relat Res.* 2001;3:79–86.

16. Calvo Guirado JL, Sáez Yuguero R, Ferrer Pérez V, et al. Immediate anterior implant placement and early loading by provisional acrylic crowns: A prospective study after a one-year follow-up period. *J Ir Dent Assoc.* 2002;48:43–49.

17. Groisman M, Frossard WM, Ferreira HM, et al. Single-tooth implants in the maxillary incisor region with immediate provisionalization: 2-year prospective study. *Pract Proced Aesthet Dent.* 2003;15:115–122;quiz 126.

18. Lorenzoni M, Pertl C, Zhang K, et al. Immediate loading of single-tooth implants in the anterior maxilla. Preliminary results after one year. *Clin Oral Implants Res.* 2003;14:180–187.

19. Norton MR. A short-term clinical evaluation of immediately restored maxillary TiOblast single-tooth implants. *Int J Oral Maxillofac Implants.* 2004;19:274–281.

20. Cornelini R, Cangini F, Covani U, et al. Immediate restoration of implants placed into fresh extraction sockets for single-tooth replacement: A prospective clinical study. *Int J Periodontics Restorative Dent.* 2005;25:439–447.

21. Barone A, Rispoli L, Vozza I, et al. Immediate restoration of single implants placed immediately after tooth extraction. *J Periodontol.* 2006;77:1914–1920.

22. De Rouck T, Collys K, Cosyn J. Single-tooth replacement in the anterior maxilla by means of immediate implantation and provisionalization: A review. *Int J Oral Maxillofac Implants.* 2008;23:897–904.

23. Botticelli D, Berglundh T, Lindhe J. Hard-tissue alterations following immediate implant placement in extraction sites. *J Clin Periodontol.* 2004;31:820–828.

24. Araújo MG, Sukekava F, Wennström JL, et al. Tissue modeling following implant placement in fresh extraction sockets. *Clin Oral Implants Res.* 2006;17:615–624.

25. Kan JY, Rungcharassaeng K, Sclar A, et al. Effects of the facial osseous defect morphology on gingival dynamics after immediate tooth replacement and guided bone regeneration: 1-year results. *J Oral Maxillofac Surg.* 2007;65(suppl 1):13–19.

26. De Rouck T, Collys K, Cosyn J. Immediate single-tooth implants in the

Copyright © Lippincott Williams & Wilkins. Unauthorized reproduction of this article is prohibited.

anterior maxilla: A 1-year case cohort study on hard and soft tissue response. *J Clin Periodontol.* 2008;35:649–657.

27. den Hartog L, Slater JJ, Vissink A, et al. Treatment outcome of immediate, early and conventional single-tooth implants in the aesthetic zone: A systematic review to survival, bone level, soft-tissue, aesthetics and patient satisfaction. *J Clin Periodontol.* 2008;35:1073–1086.

28. Cosyn J, Eghbali A, De Bruyn H, et al. Immediate single-tooth implants in the anterior maxilla: 3-year results of a case series on hard and soft tissue response and aesthetics. *J Clin Periodontol.* 2011; 38:746–753.

29. Ricci JL, Charvert J, Frenkel S, et al. Bone response to laser microtextured surfaces. In: Davies JE, ed. *Bone Engineering*. Toronto, Canada: Em2; 2000:282–294.

30. Alexander H, Ricci JL, Hrico GJ. Mechanical basis for bone retention around dental implants: *J Biomed Mater Res B Appl Biomater.* 2009;23:200–210.

31. Nevins M, Nevins ML, Camelo M, et al. Human histologic evidence of a connective tissue attachment to a dental implant. *Int J Periodontics Restorative Dent.* 2008;28:111–121.

32. Shin SY, Han DH. Influence of a microgrooved collar design on soft and hard tissue healing of immediate implantation in fresh extraction sites in dogs. *Clin Oral Implants Res.* 2010;21:804–814.

33. Botos S, Yousef H, Zweig B, et al. The effects of laser microtexturing of the dental implant collar on crestal bone levels and peri-implant health. *Int J Oral Maxillofac Implants.* 2011;26:492–498.

34. Gelb DA. Immediate implant surgery: Three-year retrospective evaluation of 50 consecutive cases. *Int J Oral Maxillofac Implants.* 1993;8:388–399.

35. Buser D, Martin W, Belser UC. Optimizing esthetics for implant restorations in the anterior maxilla: Anatomic and surgical considerations. *Int J Oral Maxillofac Implants.* 2004;19:43–61.

36. Fürhauser R, Florescu D, Benesch T, et al. Evaluation of soft tissue around single-tooth implant crowns: The pink esthetic score. *Clin Oral Implants Res.* 2005;16:639–644.

37. Belser UC, Grütter L, Vailati F, et al. Outcome evaluation of early placed maxillary anterior single-tooth implants using objective esthetic criteria: A cross-sectional, retrospective study in 45 patients with a 2- to 4-year follow-up using pink and white esthetic scores. *J Periodontol.* 2009;80:140–151.

38. Turkyilmaz I, Avci M, Kuran S, et al. A 4-year prospective clinical and radiological study of maxillary dental implants supporting single-tooth crowns using early and delayed loading protocols. *Clin Implants Dent Rel Res.* 2007;9:222–227.

39. De Bruyn H, Atashkadeh M, Cosyn J, et al. Clinical outcome and bone preservation of single TiUnite™ implants installed with flapless or flap surgery. *Clin Implant Dent Relat Res.* 2011;13:175–183.

40. Eghbali A, De Bruyn H, De Rouck T, et al. Single implant treatment in healing versus healed sites of the anterior maxilla: A clinical and radiographic evaluation. *Clin Implant Dent Relat Res.* 2012;14: 336–346.

41. Albrektsson T, Jansson T, Lekholm U. Osseointegrated dental implants. *Dent Clin North Am.* 1986;30:151–174.

42. Heydenrijk K, Meijer HJ, van der Reijden WA, et al. Microbiota around root-form endosseous implants: A review of the literature. *Int J Oral Maxillofac Implants.* 2002;17:829–838.

43. De Rouck T, Collys K, Cosyn J. Immediate single-tooth implants in the anterior maxilla: A 1-year case cohort study on hard and soft tissue response. *J Clin Periodontol.* 2008;35:649–657.

44. De Rouck T, Collys K, Wyn I, et al. Instant provisionalization of immediate single-tooth implants is essential to optimize esthetic treatment outcome. *Clin Oral Implants Res.* 2009;20:566–570.

45. Lang NP, Lui P, Lau KY, et al. A systematic review on survival and success rates of implants placed immediately into fresh extraction sockets after at least 1 year. *Clin Oral Implants Res.* 2012;23 (suppl 5):39–66.

46. Pecora GE, Ceccarelli R, Bonelli M, et al. Clinical evaluation of laser microtexturing for soft tissue and bone attachment to dental implants. *Implant Dent.* 2009;18: 57–66.

47. Shapoff CA, Lahey B, Wasserlauf PA, et al. Radiographic analysis of crestal bone levels around Laser-Lok collar dental implants. *Int J Periodontics Restorative Dent.* 2010;30:129–137.

48. Jemt T. Regeneration of gingival papillae after single-implant treatment. *Int J Periodontics Restorative Dent.* 1997;17: 326–333.

49. Choquet V, Hermans M, Adriaenssens P, et al. Clinical and radiographic evaluation of the papilla level adjacent to single-tooth dental implants. A retrospective study in the maxillary anterior region. *J Periodontol.* 2001;72: 1364–1371.

50. Tarnow DP, Magner AW, Fletcher P. The effect of the distance from the contact point to the crest of bone on the presence or absence of the interproximal dental papilla. *J Periodontol.* 1992;63:995–996.

51. Kan JY, Rungcharassaeng K, Umezu K, et al. Dimensions of peri-implant mucosa: An evaluation of maxillary anterior single implants in humans. *J Periodontol.* 2003;74:557–562.

52. Henriksson K, Jemt T. Measurements of soft tissue volume in association with single-implant restorations: A 1-year comparative study after abutment connection surgery. *Clin Implant Dent Relat Res.* 2004;6:181–189.

53. Cardaropoli G, Lekholm U, Wennström JL. Tissue alterations at implant-supported single- tooth replacements: A 1-year prospective clinical study. *Clin Oral Implants Res.* 2006;17:165–171.

54. Raes F, Cosyn J, Crommelinck E, et al. Immediate and conventional single implant treatment in the anterior maxilla: 1-year results of a case series on hard and soft tissue response and aesthetics. *J Clin Periodontol.* 2011;38:385–394.

55. Kan JY, Rungcharassaeng K, Lozada J. Immediate placement and provisionalization of maxillary anterior single implants: 1-year prospective study. *Int J Oral Maxillofac Implants.* 2003;18:31–39.

56. Redemagni M, Cremonesi S, Garlini G, et al. Soft tissue stability with immediate implants and concave abutments. *Eur J Esthet Dent.* 2009;4:328–337.

57. Chen ST, Darby IB, Reynolds EC. A prospective clinical study of nonsubmerged immediate implants: Clinical outcomes and esthetic results. *Clin Oral Implants Res.* 2007;18:552–562.

58. Chen ST, Darby IB, Reynolds EC, et al. Immediate implant placement post-extraction without flap elevation. *J Periodontol.* 2009;80:163–172.

59. Juodzbalys G, Wang HL. Soft and hard tissue assessment of immediate implant placement: A case series. *Clin Oral Implants Res.* 2007;18:237–243.

60. Kan JY, Rungcharassaeng K, Sclar A, et al. Effects of the facial osseous defect morphology on gingival dynamics after immediate tooth replacement and guided bone regeneration: 1-year results. *Int J Oral Maxillofacial Surg.* 2007;65:13–19.

61. Evans CD, Chen ST. Aesthetic outcomes of immediate implant placements. *Clin Oral Implants Res.* 2008;19:73–80.

62. Cosyn J, Eghbali A, De Bruyn H, et al. Single implant treatment in healing versus healed sites of the anterior maxilla: An aesthetic evaluation. *Clin Implant Dent Relat Res.* 2012;14:517–526.

63. Lai HC, Zhang ZY, Wang F, et al. Evaluation of soft-tissue alteration around implant-supported single-tooth restoration in the anterior maxilla: The pink esthetic score. *Clin Oral Implants Res.* 2008;19: 560–564.

64. Buser D, Halbritter S, Hart C, et al. Early implant placement with simultaneous guided bone regeneration following single-tooth extraction in the aesthetic zone: 12-month results of a pro-

Copyright © Lippincott Williams & Wilkins. Unauthorized reproduction of this article is prohibited.

spective study with 20 consecutive patients. *J Periodontol.* 2009;80:152–162.

65. Ricci JL, Grew JC, Alexander H. Connective-tissue responses to defined biomaterial surfaces. I. Growth of rat fibroblast and bone marrow cell colonies on microgrooved substrates. *J Biomed Mater Res A.* 2008;85:313–325.

66. Grew JC, Ricci JL, Alexander H. Connective-tissue responses to defined biomaterial surfaces. II. Behavior of rat and mouse fibroblasts cultured on microgrooved substrates. *J Biomed Mater Res A.* 2008;85:326–335.

67. Nevins M, Kim DM, Jun SH, et al. Histologic evidence of a connective tissue attachment to laser microgrooved abutments: A canine study. *Int J Periodontics Restorative Dent.* 2010;30:245–255.

68. Araújo MG, Sukekava F, Wennström JL, et al. Ridge alterations following implant placement in fresh extraction sockets: An experimental study in the dog. *J Clin Periodontol.* 2005;32: 645–652.

69. Buser D, Halbritter S, Hart C, et al. Early implant placement with simultaneous guided bone regeneration following single-tooth extraction in the aesthetic zone: 12-month results of a prospective study with 20 consecutive patients. *J Periodontol.* 2009;80:152–162.

70. Nisapakultorn K, Suphanantachat S, Silkosessak O, et al. Factors affecting soft tissue level around anterior maxillary single-tooth implants. *Clin Oral Implants Res.* 2010;21:662–670.

71. Block MS, Mercante DE, Lirette D, et al. Prospective evaluation of immediate and delayed provisional single tooth restorations. *Int J Oral Maxillofac Implants.* 2009;67:89–107.

Copyright © Lippincott Williams & Wilkins. Unauthorized reproduction of this article is prohibited.