Tackling a challenging esthetic clinical situation

Dr. Cary A. Shapoff illustrates a case replacing two adjacent maxillary central incisors

Replacing two adjacent maxillary central incisors is one of the most challenging esthetic clinical situations we face in providing dental implant therapeutics. The maxillary anterior region provides numerous esthetic, technical, and sequencing challenges. This article describes a surgical and restorative workflow for this clinical problem from treatment planning considerations to selection of a dental implant system that provides surgical and restorative advantages in order to enhance the esthetic outcome.



Figure 1



Figure 2



Figure 3

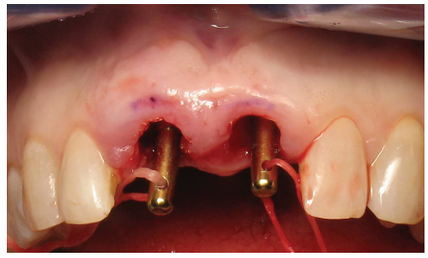

Figure 4

Case 1

A 53-year-old female presented for functional surgical crown-lengthening procedure around her maxillary central incisors (teeth Nos. 8 and 9) prior to replacement of new crowns. The patient reported mobility of the existing crowns and an unpleasant odor in her mouth. According to patient history, these crowns were recent replacements of prior long-standing unesthetic crowns. The patient had an unremarkable medical history and had previously sought dental and dental hygiene care on a regular basis. Both teeth Nos. 8-9 had prior endodontic therapy (Figure 1).

At her initial examination, a complete dental and periodontal evaluation, including full-mouth radiographs, was completed with photographic documentation. Significant marginal inflammation was noted around teeth Nos. 8-9 associated with poor fit of the crown margins and with recurrent decay. The patient demonstrated normal to thick biotype with rolled, reddened margins around the central incisors associated with a high smile line and a dental history of mouth breathing (Figure 2).

All other regions of her mouth demonstrated marginal gingivitis associated with retained interproximal plaque. The existing shape of her central incisor crowns were square and short and disproportionate in shape and size to her other natural anterior teeth.

The existing crowns were carefully removed, and the underlying tooth structure was inspected. It was noted that there was inadequate core portion of the crowns, with only the coronal aspect of an endodontic post and composite retaining the crowns. There had been no ferrule portion of the tooth preparations in the cervical region (Figure 3). The likely contributing factor to the mobility of the crowns was the excessive tooth preparation resulting in crown flexure and marginal leakage resulting in recurrent caries.

At her request, she was referred to a prosthodontist for further restorative treatment. A composite-based diagnostic wax-up was completed to assist in determining optimum tooth height and shape. Treatment plan options were developed after discussing surgical and restorative considerations with the patient. These included functional surgical crown lengthening and new crowns, orthodontic extrusion of the two central incisors, followed by functional crown lengthening and new crowns, or extraction of the teeth and replacement with two dental implants and crowns. Based on the missing core portion of her teeth and the extent of decay around the post spaces, it was determined that extraction of the teeth and replacement with dental implants was the treatment of choice. Based on the anatomy of the tooth sockets and dimensions of palatal bone, identified by three-dimensional imaging CBCT, it was further determined that immediate extraction and placement of dental implants with intra-socket bone grafting was possible.

The patient preferred interim fixed provisionalization during the initial healing phase, rather than any of the removable provisional options discussed with her.

The surgical phase consisted of



Cary A. Shapoff, DDS, has practiced in Fairfield, Connecticut for over 36 years. He is in private practice as a periodontist, and is a Diplomate and past director of the American Board of Periodontology. He lectures both nationally and internationally on periodontal disease and its treatment, bone grafting procedures, and dental implant surgery. He has also written articles published in the *Journal of Periodontology*, *Compendium*, the *International Journal of Periodontics and Restorative Dentistry*, and *The Dental Guide* (Canada). He has been a consultant and lecturer for BioHorizons for 7 years.

Dr. Shapoff can be contacted at: cas@shapoff.com.

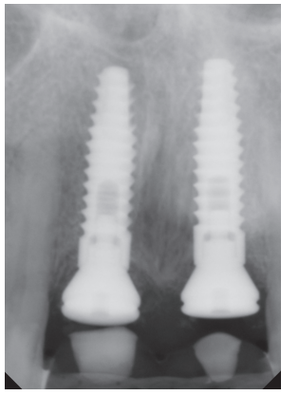

Figure 5

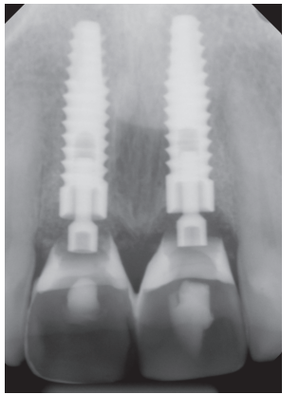

Figure 6



Figure 7A



Figure 7B

extraction of teeth with a flapless approach followed by careful curettage of the intact socket walls. Utilizing a surgical guide based on the diagnostic wax-up, two dental implants were placed, engaging the palatal wall of the intact sockets (Figure 4).

The implants selected were the BioHorizons® Tapered Internal with Laser-Lok® microchannels on the coronal collar portion (3.8 mm x 15 mm with 3.5 mm prosthetic platforms). Precise three-dimensional positioning was established with the surgical guide. Following implant placement, the voids within the socket were bone grafted with a combination cortical and cancellous allograft (MinerOss®), and flared healing abutments were placed to support the soft tissues (Figure 5).

The composite-based diagnostic wax-

Carestream
DENTAL

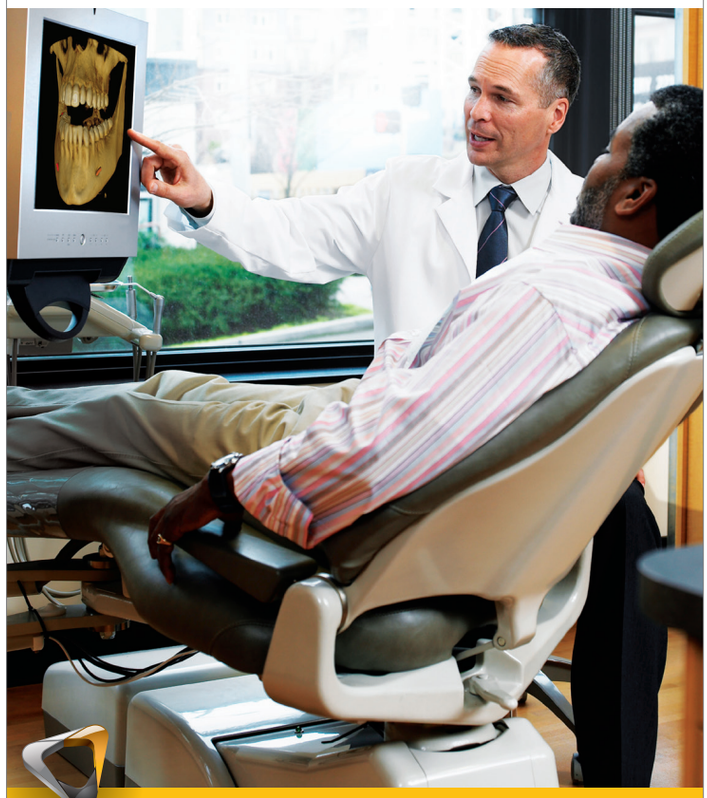

It's amazing what a great image can do for your practice.

The CS 9300 Select is ready to work hard for your practice.

This technologically-advanced system will finally give you clarity, flexibility and, most importantly, complete control of your image quality and dosimetry. It will also show your patients how dedicated you are to their oral health.

- **One system with superior 3D scans with multiple fields of view, 2D panoramic imaging and optional one-shot cephalometric imaging**
- **Dedicated 2D digital panoramic imaging with variable focal trough technology that produces high-quality images in 13 seconds**
- **Intelligent Dose Management provides high-resolution 3D images and low dose as collimation limits exposure to area of interest**
- **Five selectable fields of view ranging from 5cm x 5cm to 10cm x 10cm help you get the proper image size for each procedure**



To learn more about what a great image can do for your oral and maxillofacial surgery practice, visit carestreamdental.com/CS9300 or call 800.944.6365 today.

© Carestream Health, Inc. 2013
10232 OM DI AD 0114

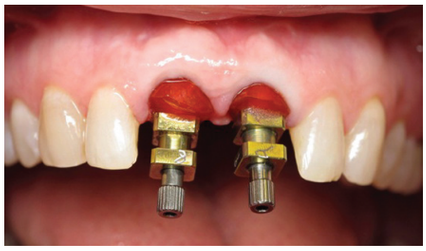
Figure 8

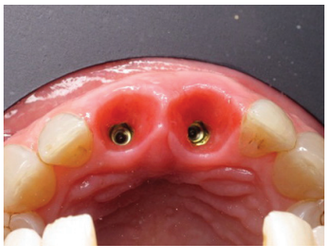
Figure 9


Figure 10A


Figure 10B

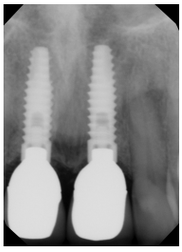
Figure 11


Figure 12A

Figure 12B

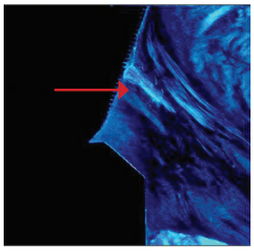
Figure 13: Polarized light micrograph

up was then bonded to adjacent laterals as a fixed provisional.

Three months after surgical placement of the implants, screw-retained provisional crowns were fabricated onto PEEK abutments and were modified to achieve ideal tooth shape and gingival architectural framework (Figure 6). Maintenance of the interproximal bone between the implants was achieved with use of the BioHorizons implants with Laser-Lok microchannels. Minor modifications to the interproximal and facial dimensions of the composite crowns were made over a period of 12 weeks (Figures 7A and 7B).

Once ideal tooth and gingival size and shape were established, custom, open-tray impressions were taken to capture the precise ideal subgingival form for final crown fabrication (Figures 8-9). Final crowns were then provisionally cemented and monitored for potential additional minor modifications (Figures 10A and 10B). The radiograph of the final crowns at 12 months demonstrates the maintenance of the crestal bone around each dental implant as well as maintenance of the interproximal bone between the implants (Figure 11).

Discussion

Numerous lessons can be learned from a critical review of this case.

1. Evaluation of the failed crowns identified excessive tooth preparation and inadequate coronal portion of the tooth to provide predictable restoration with basic fixed partial dentures (crowns). In addition, the design of the failed crowns did not mimic the tapered shape of her adjacent natural teeth. Critical documentation of tooth shape and size and smile analysis is an essential element of proper treatment planning. Lack of adequate ferrule and lack of coronal tooth portion should have precluded placement of the failed permanent crowns.

2. Dental implant treatment planning should include photographic documentation, diagnostic wax-up, evaluation of the gingival tissue biotype, position of the maxillary lip position relative to the gingival margin of the teeth, and shape and form of the intended implant restoration.

3. Surgical treatment planning should include three-dimensional imaging especially if a flapless approach is considered. Because of the thick gingival biotype and intact sockets of both teeth, immediate placement was considered. In other cases of high smile line, and thinner biotype, a delayed two-phased approach of grafting followed by implant placement would have been the treatment choice. A delayed two-phased approach would also be required if the remaining alveolar bone prevented adequate initial biomechanical stability at implant insertion.

4. Selection of the BioHorizons Tapered Internal implant was a key element of the success of maintaining interproximal bone between two implants. Use of the tapered 3.8 implant body allowed ideal positioning


Figure 14

in the palatal bone without encroachment on the facial bone dimension or elimination of the mesiodistal bone within the socket reducing initial stability. Intra-socket bone grafting with a calcified allograft minimized the horizontal dimension bone resorption often seen even with immediate implant placement. The use of the BioHorizons implants with the Laser-Lok microchannels was another key element in maintaining the ideal intra-implant bone level, which in turn supported the ideal height of the interproximal papilla. Numerous published articles have supported the concept of enhanced bone maintenance with the non-random Laser-Lok microchannels (Figures 12A and 12B). Additional animal and human clinical and histologic studies have demonstrated “functionally oriented” connective tissue attachment to the Laser-Lok surface along with inhibition of the epithelial downgrowth against the implant surface and Laser-Lok abutment surface (Figure 13).



Figure 15

5. Maintaining support of the facial and interproximal tissue contours with use of the flared healing abutments assisted in recapturing the proper gingival contour around the provisional crowns. This could have been further improved by fabrication of "custom" healing abutments utilizing the BioHorizons 3inOne abutment and composite. This customized technique is used often in this practice but was not utilized in this case.

6. Fabrication and modification of the well-contoured, screw-retained provisionals by the prosthodontist, Dr. Jeffrey O'Connell, (Bridgeport, Connecticut) was also another key element in achieving ideal tooth shape and gingival framework. In addition, the established subgingival contours were captured in the final impression technique utilizing the BioHorizons open-tray copings modified with resin. The excellent working relationship of the prosthodontist and his dental laboratory technician also needs to be mentioned in achieving natural-looking, all-ceramic crowns. This case was completed before the company release of CAD-CAM custom abutments with Laser-Lok microchannels (Figure 14). Use of these abutments would have further enhanced the attachment of soft tissue to the abutment surface resulting in protection of the underlying crestal bone.

In summary, the patient was successfully restored with two single-crown dental implant restorations following an interdisciplinary workflow from treatment planning through final restorations. The use of the BioHorizons Tapered Internal dental implant with Laser-Lok microchannels was an integral part of the success of this case. In similar cases where the gingival biotype is thinner, I would have considered using the platform switched BioHorizons Tapered Internal Plus implant in order to create a thicker dimension of marginal tissue around the abutments (Figure 15). IP

Carestream DENTAL

YOUR PRACTICE. OUR PASSION.



Count on us for INNOVATIVE design to keep your practice in the forefront.

INTEGRATED software for seamless workflow, office to operatory.

And INTERACTIVE products that promote better patient relationships.

Visit www.carestreamdental.com or call 800.944.6365.

© Carestream Health, Inc. 2013. RVG and WinOMS are trademarks of Carestream Health. 10232 OM DI AD 0114

Share our passion for your practice online.