A Modified Edentulous Ridge Expansion Technique for Immediate Placement of Implants: A Case Report

Mario Santagata, MD, PhD*
Luigi Guariniello, MD, PhD
Gianpaolo Tartaro, MD, PhD

This case report is focused on the possibility of treating atrophic ridge with a reduced number of surgical procedures and a reduced healing time. A 43-year-old female patient affected by edentulism associated with horizontal resorption of the ridge was treated by means of a sagittal osteotomy and expansion of the ridge with the new modified edentulous ridge expansion (MERE) technique to obtain a wider bony base for ideal implant placement. In the same procedure 2 implants were placed and connective tissue graft, covering the bony wound, was placed to achieve keratinized mucosa. The implants were placed immediately after the split crest of the ridge and covered by a connective tissue graft. Postoperative recovery was uneventful. Within the limits of this case report, the MERE technique appeared to be reliable and simple, and it reduced morbidity compared with other techniques such as autogenous bone grafts and guided bone regeneration.

Key Words: MERE technique, split-crest, alveolar ridge augmentation, dental implants, soft-tissue grafts

INTRODUCTION

The modified edentulous ridge expansion (MERE) technique corrects the atrophic ridge with a reduced number of surgical procedures and a reduced healing time. Since its introduction the MERE technique has undergone several modifications to allow placement of implants in a submerged approach.[1–6]

Recently, Coatoam and Mariotti[7] introduced a modification with a segmental ridge-split procedure that includes an orthodontic ligature wire for stability of the bony plates. The present report deals with a further modification of the segmental ridge-split procedure, including the use of connective tissue graft as a biological barrier to cover an immediate implant for improved hard- and soft-tissue regeneration.

CASE REPORT

A 43-year-old female patient affected by edentulism associated with horizontal alveolar ridge defect was referred to the authors for surgical correction of the deficit to improve implant support and the final esthetics of an implant-borne prosthesis. Patient exclusion criteria were extremely atrophic ridge with no interposition of

Department of Head and Neck Pathologies, Oral Cavity and Audio-Verbal Communication, Second University of Naples, Naples, Italy.
* *Corresponding author,* e-mail: mario.santagata@tin.it
DOI: 10.1563/AAID-JOI-D-10-00035.1

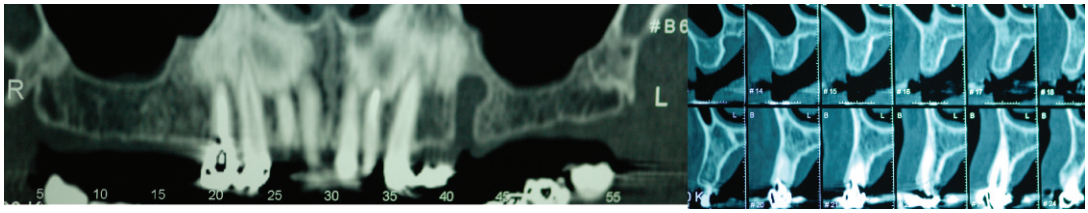

Figure 1. A low-dose computerized tomography scan showed sufficient interposition of cancellous bone between the buccal and palatal plates.

cancellous bone between the buccal and palatal plates and concomitant vertical defect.

A low-dose computerized tomography (CT) scan was performed for treatment planning (slice thickness = 1.25 mm; interval = 0.6 mm; table feed = 11.25 mm × rotation; field of view = 0.6 mm; matrix = 512 × 512/200 mA/80 kV).[8] A low-dose CT scan was also required to evaluate the horizontal defect and the presence of cancellous bone between the buccal and palatal plates (Figure 1).

Surgical procedure

The operation was performed under local anesthesia (2% mepivacaine).

The MERE technique

Step 1: Flap Design

A full-thickness flap was dissected only in alveolar crest (Figure 2). Periosteum preservation was intended to reduce bone resorption and prevent free fracture of the split ridge.

Step 2: Sagittal Osteotomy

A sagittal osteotomy was outlined in the bone by scoring it with a No. 64 Beaver blade (BD Beaver, Waltham, Mass) (Figure 3). The blade was used as a chisel and was tapped with a surgical mallet (Walter Lorenz, Surgical, Inc, Jacksonville, Fla) around approximately 3 mm deep into the crestal ridge. Vertical bone-releasing osteotomies were also carried out mesially and distally 2 mm away from the adjacent teeth. This was intended to give the split segment enough elasticity and to prevent accidental bone fracture of the transposed bony segment.

Step 3: Osteotomes Technique

Once the bony incisions were outlined, a bone chisel (Hu-Friedy Mfg Co, Inc, Chicago, Ill) was progressively driven deeper in the crestal osteotomy, and the implant site was prepared to the final depth with the osteotomes technique (Bone condenser—Silhouette Osteotomes, Biolok International Inc, Deerfield Beach, Fla) (Figure 4).

Step 4: Implant Placement

Tapered internal implants with a laser microgrooved coronal design (Biohorizons, Birmingham, Ala) (Figure 5) were gently tapped into position. Implant diameter was slightly wider than the osteotomy sites to increase primary stability.

Step 5: Xenograft

The furrow between the bone plates was grafted with a mix of cancellous and cortical porcine bone (Putty, Tecnoss, Turin, Italy) because the gap was more than 2 mm deep.[9]

Step 6: Connective Tissue Graft

Before suturing, an autogenous connective tissue graft was layered over the bony wound and used as a biological barrier for better hard- and soft-tissue regeneration. The connective tissue graft, about 1.5 mm thick and 27 mm wide, was harvested from the palate. The donor site was selected from the palate, 2 mm below the gingival crestal

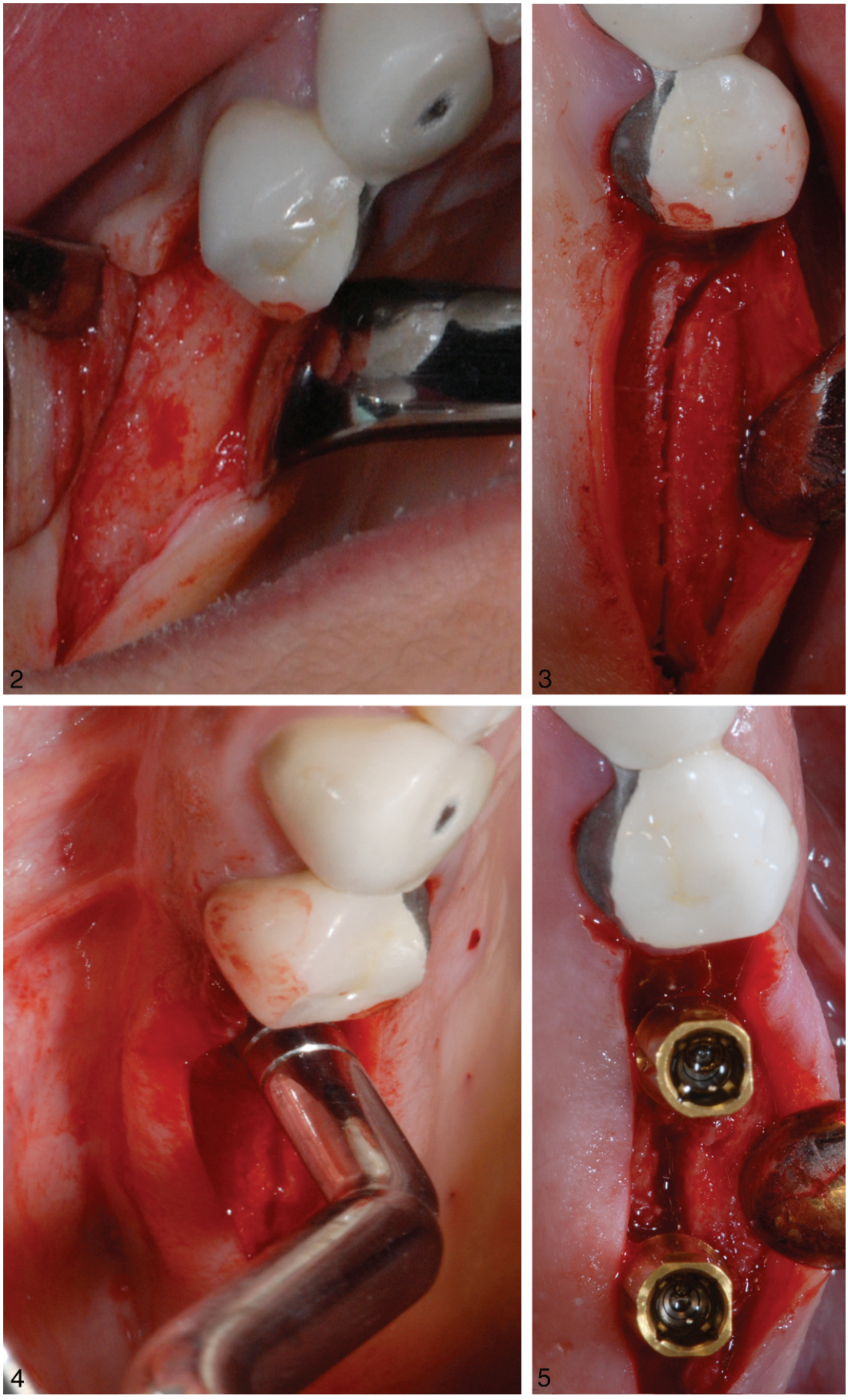

Figures 2–5. Figure 2. Paracrestal palatal incision. **Figure 3.** Sagittal osteotomy with vertical bone-releasing osteotomy. **Figure 4.** Osteotome technique. **Figure 5.** Implant placement.

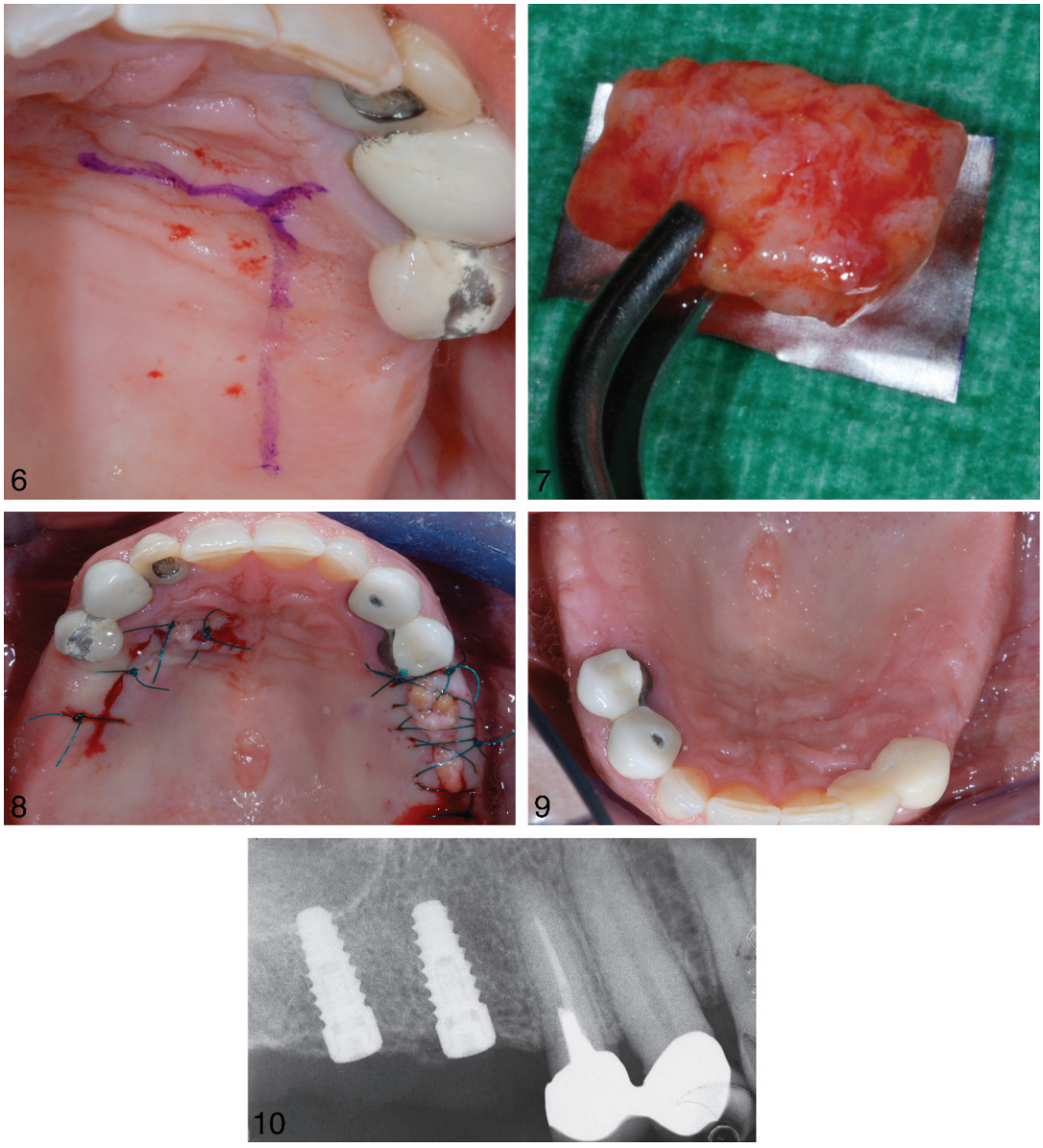

Figures 6–10. Figure 6. Donor site. **Figure 7.** Autogenous connective tissue graft. **Figure 8.** Autogenous connective tissue graft placed. A suture was placed from the vestibular to the palatal site, stabilizing the connective graft. **Figure 9.** The clinical aspect at the 50 days postoperative examination. **Figure 10.** A periapical radiograph exhibiting implant sites 15 and 16 and minimally invasive sinus lift in site 16 in the immediate postoperative period.

margin (Figure 6). The connective tissue was placed over the implants and inserted under the vestibular and palatal residual keratinized mucosa. Sutures were placed from the vestibular to the palatal site, stabilizing the connective tissue graft. A connective tissue graft covering the bony wound was used to augment the keratinized mucosa and avoid bone graft infection (Figures 7 through 10).

Step 7: Suturing

Periosteal sutures, using 4/0 Trofilorc sutures (LorcaMarìn, SA, Murcia, Spain), were used to intentionally position the flap buccally and palatally for healing by secondary intention.

Step 8: Postoperative Care

All patients received 2 g of amoxicillin plus clavunate per day starting approximately

1 hour before surgery and continuing for 6 days after surgery and nonsteroidal analgesic (ibuprofen, 400 mg) as needed after surgery. Postoperative instructions included a soft diet for 2 weeks and a rinse with 0.2% chlorhexidine solution twice a day for 1 minute until mechanical brushing could be resumed. Sutures were removed 10 days after surgery.

Results

The implants were placed immediately in conjunction with the MERE technique of the edentulous ridge and covered by an autogenous connective tissue graft. The MERE technique exploits the healing processes to regenerate soft and hard tissues at the treated site. This approach restores proper placement and continuity to the mucogingival junction, increases the quantity of keratinized tissue, and deepens the fornix. These results may be achieved in a single surgical step thanks to partial thickness dissection.

Postoperative recovery was uneventful.

Discussion and Conclusion

Compared with standard sagittal osteotomy, where the expansion of the atrophied site is obtained with chisels, expansion using the osteotome technique may allow a more gradual widening of the ridge and avoid excessive vestibular inclination of the fixture; there is also less risk of fracture of the osteotomized segments. In fact, traditional bone-splitting techniques[3] present problems associated with the fact that the axis of rotation is situated at the apical end of the osteotomy with consequent excessive vestibular inclination of the implant body.

This situation may result in esthetic and biologic problems; the emergence profile of the implant-prosthesis is displaced vestibularly and apically with significantly reduced thickness. This results in tissue instability that can lead to recession and possible exposure of the implant body.

The MERE technique avoids this problem and avoids possible complication like collagen membrane infection. In fact, when the gap between buccal and palatal plates is very large and/or deep, one or more layers of equine lyophilized and resorbable collagen are placed within the coronal portion of the newly created alveolus.[3]

This membrane may become contaminated with oral cavity bacteria that can damage the native bone. In this case report, an autogenous connective tissue graft was used to act as a biological barrier for improved hard- and soft-tissue regeneration.

In conclusion, within the limits of this case report, the technique appears to be relatively simple: it reduced the biological cost and corrected the atrophic ridge with a reduced number of surgical procedures and a reduced healing time. These results may be achieved in a single surgical step thanks to partial-thickness dissection. A full-thickness approach would require closure of the surgical wound by first intention, thus altering the anatomy of the soft tissues in this area. This often results in the need for a second corrective mucogingival surgery procedure.

Abbreviations

CT: computerized tomography
MERE: modified edentulous ridge expansion

References

1. Duncan JM, Westwood RM. Ridge widening for the thin maxilla: a clinical report. *Int J Oral Maxillofac Implants*. 1997;12:224–227.

2. Engelke WG, Diederichs CG, Jacobs HG, Deckwer I. Alveolar reconstruction with splitting osteotomy and microfixation of implants. *Int J Oral Maxillofac Implants*. 1997;12:310–318.

3. Scipioni A, Bruschi GB, Calesini G. The edentulous ridge expansion technique: a five-year study. *Int J Periodontics Restorative Dent*. 1994;14:451–459.

4. Scipioni A, Bruschi GB, Calesini G, Bruschi E, De Martino C. Bone regeneration in the edentulous ridge expansion technique: histologic and ultrastructural study of 20 clinical cases. *Int J Periodontics Restorative Dent*. 1999;19:269–277.

5. Sethi A, Kaus T. Maxillary ridge expansion with simultaneous implant placement: 5-years results of an ongoing clinical study. *Int J Oral Maxillofac Implants*. 2000;15:491–499.

6. Simion M, Baldoni M, Zaffe D. Jawbone enlargement using immediate implant placement associated with a split-crest technique and guided tissue regeneration. *Int J Periodontics Restorative Dent*. 1992;12:462–473.

7. Coatoam GW, Mariotti A. The segmental ridge-split procedure. *J Periodontol*. 2003;74:757–770.

8. Fanucci E, Leporace M, Di Costanzo G, Fiaschetti V, Simonetti G. Multidetector CT and Dentascan software: dosimetric evaluation and technique improvement. *Radiologia Medica*. 2006;111:130–138.

9. Chen ST, Wilson TG, Hammerle C. Immediate or early placement of implants following tooth extraction: review of biologic basis, clinical procedures and outcomes. *Int J Oral Maxillofac Implant*s. 2004;19(suppl):12–25.