CLINICAL ORAL IMPLANTS RESEARCH

Gerhard Iglhaut
Kathrin Becker
Vladimir Golubovic
Henning Schliephake
Ilja Mihatovic

The impact of dis-/reconnection of laser microgrooved and machined implant abutments on soft- and hard-tissue healing

Authors' affiliations:
Gerhard Iglhaut, Private Practice, Memmingen, Germany
Gerhard Iglhaut, Henning Schliephake, Department of Oral and Maxillofacial Surgery, George-Augusta-University, Göttingen, Germany
Kathrin Becker, Vladimir Golubovic, Ilja Mihatovic, Department of Oral Surgery, Heinrich Heine University, Düsseldorf, Germany

Corresponding author:
Dr. Ilja Mihatovic
Department of Oral Surgery
Westdeutsche Kieferklinik
Heinrich-Heine-University
D-40225 Düsseldorf, Germany
Tel.: +49 211 8118149
Fax: +49 211 8116550
e-mail: ilja.mihatovic@med.uni-duesseldorf.de

Date:
Accepted 30 July 2012

To cite this article:
Iglhaut G, Becker K, Golubovic V, Schliephake H, Mihatovic I. The impact of dis-/reconnection of laser microgrooved and machined implant abutments on soft- and hard-tissue healing.
Clin. Oral Impl. Res. **24**, 2013, 391–397
doi: 10.1111/clr.12040

© 2012 John Wiley & Sons A/S

Key words: animal study, crestal bone level, immunohistochemistry, platform switching

Abstract

Objectives: To (i) investigate the influence of different extensions of a laser microgrooved abutment zone on connective tissue attachment and (ii) assess the impact of a repeated abutment dis-/reconnection on soft- and hard-tissue healing.

Materials and Methods: Titanium implants were inserted epicrestally in the lower jaws of six dogs. Healing abutments with either partially (LP) or completely (LC) laser microgrooved margins or machined surface margins (M) were randomly allocated either to a single (1×)/repeated (2×) dis-/reconnection at 4 and 6 weeks (test), respectively, or left undisturbed (control). At 6 and 8 weeks, histomorphometrical (e.g. most coronal level of bone in contact with the implant [CBI], subepithelial connective tissue attachment [STC]) and immunohistochemical (Collagen Type-I [CI]) parameters were assessed.

Results: At control sites, LP/LC groups revealed lower mean CBL (8 weeks, 0.95 ± 0.51 vs. 0.54 ± 0.63 vs. 1.66 ± 1.26 mm), higher mean STC (8 weeks, 82.58 ± 24.32% vs. 96.37 ± 5.12% vs. 54.17 ± 8.09%), but comparable CI antigen reactivity. A repeated abutment manipulation was associated with increased mean CBL (8 weeks, 1.53 ± 1.09 vs. 0.94 ± 0.17 vs. 1.06 ± 0.34 mm), decreased STC (8 weeks, 57.34 ± 43.06% vs. 13.26 ± 19.04% vs. 37.76 ± 37.08%) and CI values.

Conclusions: It was concluded that (i) LC>LP abutments enhanced subepithelial connective tissue attachment and preserved crestal bone levels, (ii) repeated abutment dis-/reconnection during the initial healing phase (4–6 weeks) may be associated with increased soft- and hard-tissue changes and (iii) LP and LC should be considered using a one abutment, one time approach.

In recent years, the improvement of soft-tissue attachment to the transmucosal part of osseointegrated dental implants has become a topic of growing interest (Comut et al. 2001; Schwarz et al. 2007a, 2007b; Nevins et al. 2008, 2010; Tete et al. 2009; Kloss et al. 2011). These efforts were mainly based on the observation that the connective tissue at commonly used materials was poorly vascularized and mainly consisted of dense collagen fibres running in a direction parallel to the implant surface, thus impairing a proper soft-tissue seal (Buser et al. 1992; Berglundh et al. 1994; Abrahamsson et al. 1996).

While some authors observed that surface hydrophilicity may enhance the soft-tissue healing under preclinical conditions (Schwarz et al. 2007b, 2007c; Kloss et al. 2011), others provided the proof-of-principle concept of a direct connective tissue attachment to microgrooved dental implants in human subjects (Nevins et al. 2008). The latter surface technology is based on microchannels created by a controlled laser ablation. In an experimental animal study, it has been demonstrated that these "laser-lok" (BioHorizons, Birmingham AL, USA) surfaces prevented the apical downgrowth of the junctional epithelium by establishing a direct connective tissue attachment acting as a physiological barrier (Nevins et al. 2010).

As a frequent exchange of temporary abutments during the healing period has nowadays become a standard procedure for the conditioning of the implant supporting soft tissues, a disruption of the mucosal seal may disturb soft-tissue healing at modified implant surfaces. While a repeated exchange of machined abutments was associated with an apical positioning of the connective tissue and crestal bone level changes (Abrahamsson

et al. 1997), this issue has not been addressed for laser microgrooved abutments.

The aims of the present study were (i) to investigate the influence of different extensions of a laser microgrooved abutment zone on connective tissue attachment and (ii) to assess the impact of a repeated abutment dis-/reconnection on soft- and hard-tissue healing.

Material and methods

Animals

A total of six male foxhounds (age, 15.2 ± 7.2 months; mean weight, 41.5 ± 4.1 kg), each exhibiting a fully erupted permanent dentition, were used in the study. During the experiment, the dogs were fed once per day with soft-food diet and water *ad libitum*. The study protocol was approved by the appropriate local authority (Landesamt für Natur und Verbraucherschutz, Recklinghausen, Germany). The experimental segment of the study started after an adaption period of 4 weeks.

Study design and experimental phases

The study was conducted in two surgical phases. The mandibular 2nd, 3rd, 4th premolars as well as 1st and 2nd molar (P2-M2) were bilaterally extracted in the first phase. After 8 weeks of healing, three screw-typed titanium implants each were bilaterally inserted in the lower jaws and randomly (anterior and posterior sites) connected with nonmatching partially (LP) or completely (LC) laser microgrooved or machined titanium (M) abutments.

According to a split-mouth design, the implant sites were randomly allocated either to a single (1×)/repeated (2×) abutment dis-/reconnection at 4 and 6 weeks (test), respectively, or left undisturbed (i.e. no abutment manipulation) (control). The randomization procedure was based on a computer generated list (RandList®; DatInf GmbH, Tübingen, Germany). Accordingly, three dogs received a 1× abutment dis-/reconnection at 4 weeks, while a 2× abutment dis-/reconnection was conducted in the remaining three dogs at 4 and 6 weeks. The animals were euthanized at 6 (n = 3) and 8 (n = 3) weeks after implant placement.

Titanium implants

Commercially available two-piece titanium implants (diameter, 3.6 mm; length, 10.5 mm; Laser- Lok® 3.0 dental implants; BioHorizons) were selected for the connection of nonmatching LP (0.7 mm Laser-Lok zone), LC (2.9 mm Laser-Lok zone), and M (fully machined) healing abutments (diameter, 3.505 mm; height, 4.318 mm; BioHorizons) (Fig. 1a,b). In all groups, the resulting circumferential horizontal mismatch was about 0.1 mm.

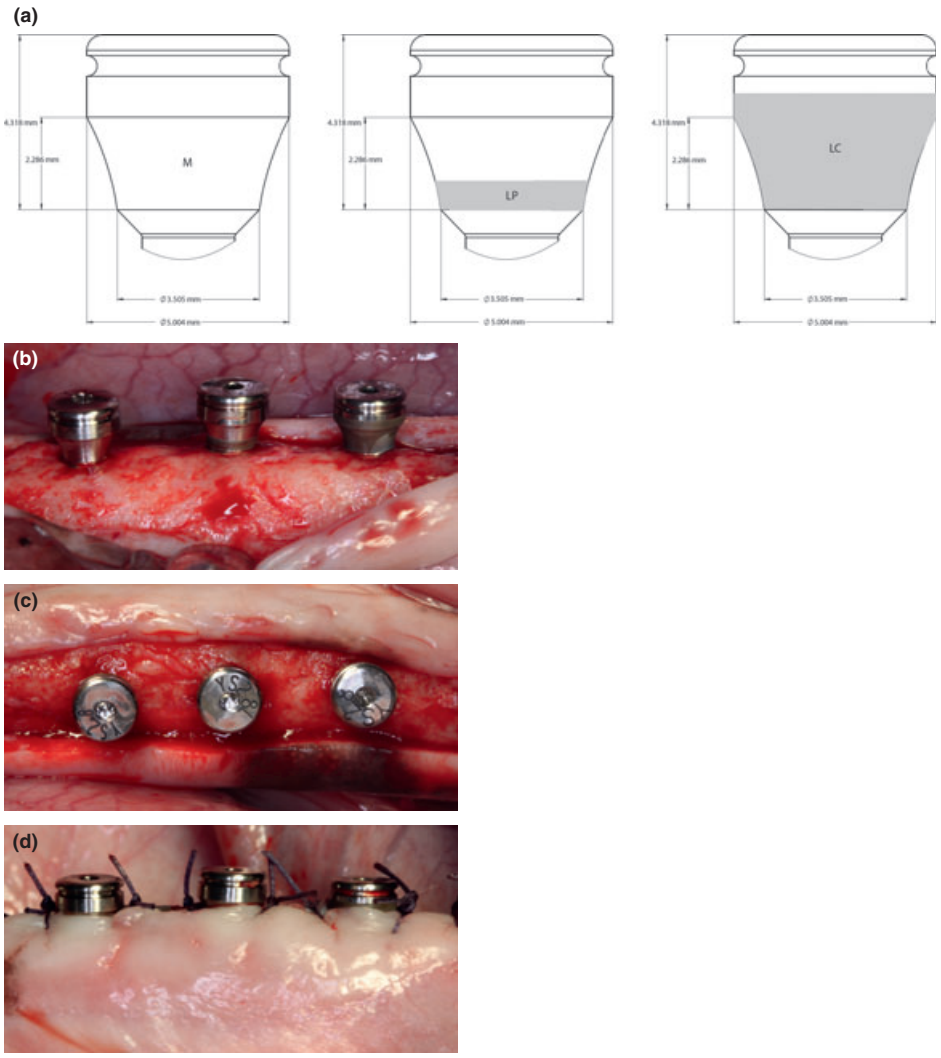

Fig. 1. (a) Sizes and dimensions of healing abutments. Left: M (fully machined); middle: LP (0.7 mm laser microgrooved zone); right: LC (2.9 mm laser microgrooved zone). (b) Implant placement was performed in the lower jaws, and IS was located at the level of the buccal alveolar crest. Healing abutments were immediately connected. Left: M; Middle: LP; Right: LC. (c) Occlusal view indicating that a residual thickness of the alveolar bone crest of at least 1 mm was maintained at both vestibular and oral aspects. (d) At most implants sites, the mucosal height was insufficient to completely cover the LC abutments. Abutments were dis-/reconnected at 4 and 6 weeks after implant placement. Contralateral sites served as control.

Surgical procedure

Prior to each surgical intervention, intramuscular sedation was accomplished with 0.01 mg/kg acepromazine (Vetranquil 1%; Ceva Tiergesundheit, Düsseldorf, Germany). Subsequently, anaesthesia was initiated according to a standard protocol employing 21.5 mg/kg thiopental-sodium (Trapanal 2.5%; Altana GmbH, Konstanz, Germany) and inhalation anaesthesia performed by the use of oxygen and nitrous oxide and isoflurane. While anesthetized, all animals received a constant rate infusion of lactated Ringer's solution to maintain hydration. Intraoperative analgesia was performed by intravenous injection of 0.1 mg/kg piritramid (Dipidolor®; Janssen-Cilag GmbH, Neuss, Germany) and 4.5 mg/kg carprofene (Rimadyl®; Pfitzer Pharma GmbH, Karlsruhe, Germany). For postoperative treatment, piritramid (days 1–3) and carprofen (days 4–7) were applied subcutaneously in the same dose as described before.

In the first surgery, P2-M2 were carefully removed bilaterally in the lower jaws after reflection of mucoperiosteal flaps and tooth separation. After wound closure by means of resorbable mattress sutures, the sites were allowed to heal for 8 weeks.

© 2012 John Wiley & Sons A/S

In the second surgery, midcrestal incisions were made and full-thickness flaps elevated to expose the respective sites for implant insertion in the upper jaws. Implant bed preparation was performed at a distance of at least 10 mm apart, using a low-trauma surgical technique under copious irrigation with sterile 0.9% physiological saline. Implant site were selected to account for a residual thickness of the alveolar bone crest of at least 1 mm at both vestibular and oral aspects. As suggested in the surgical protocol of the manufacturer, the implant shoulder was located at the level of the buccal aspect of the alveolar crest. All abutments were connected using a torque of 15 Ncm (Fig. 1c). Finally, mucoperiosteal flaps were repositioned and adapted with resorbable mattress sutures (Resorba®, Nürnberg, Germany) to ensure a nonsubmerged healing position (Fig. 1d).

In all animals, a plaque control programme including tooth and implant cleaning just by the use of a toothbrush was initiated postoperatively and provided three times per week during the entire observation period of 6 and 8 weeks (V.G.), respectively.

For abutment dis-/reconnection at 4 and 6 weeks, an intramuscular sedation with 0.01 mg/kg acepromazine was initiated and followed by a short-acting anaesthesia using 0.4 mg/10 kg medetomidin (Domitor®; Orion Corporation, Espoo, Finland). Before abutment reconnection, any visible deposits were carefully removed by a toothbrush. Cotton pellets were used under moderate pressure to remove all remaining nonmineralized deposits, which was followed by a thorough irrigation with 0.9% physiological saline. All experimental procedures including abutment dis-/reconnection were performed by one experienced surgeon (I.M.).

Retrieval of specimens

Three animals each were euthanized (overdose of sodium pentobarbital 3%) after 6 and 8 weeks after implant placement. The oral tissues were fixed by perfusion with 10% buffered formalin administered through the carotid arteries. The jaws were dissected, and blocks containing the experimental specimens were obtained. All specimens were fixed in 10% neutral buffered formalin solution for 4–7 days.

Histological preparation

The tissue biopsies were dehydrated using ascending grades of alcohol and xylene, infiltrated and embedded in methylmethacrylate (MMA) (Technovit 9100 NEU; Heraeus Kulzer, Wehrheim, Germany) for nondecalcified sectioning. During this standardized procedure, any negative influence of polymerisation heat was avoided because of a controlled polymerization in a cold atmosphere (−4°C). After 20 h, the specimens were completely polymerized and cut in the vestibulo-oral direction along with the long axis of the implant using a diamond band saw (Exakt®; Apparatebau, Norderstedt, Germany). Two sections approximately 300 μm in thickness were prepared, glued with acrylic cement (Technovit 7210 VLC; Heraeus Kulzer) to silanized glass slides (Super Frost; Menzel GmbH, Braunschweig, Germany) and ground to a final thickness of approximately 40 μm. Subsequently, one of the specimens was stained with paragon, while the other was used for immunohistochemical labelling.

Immunohistochemical labelling

For immunohistochemistry, the MMA embedded tissue sections were deplasted in xylene (2 × 30 min) followed by treatment in 2-methoxyethylacetate (2 × 20 min) and acetone (2 × 5 min). After rehydration in phosphate-buffered saline (PBS), antigen unmasking was performed by incubating the slides for 15 min in trypsin (0.05% in PBS; PAA Laboratories GmbH, Pasching, Austria) at 37° C. After washing with PBS, the activity of endogenous peroxidase was quenched with 0.9% hydrogen peroxide in PBS for 10 min at room temperature, the specimens were washed and nonspecific binding sites were blocked with a blocking solution for 30 min (DakoCytomation, Hamburg, Germany). The primary mouse monoclonal antibody to collagen type-1 (1 : 40 dilution; Acris Antibodies GmbH, Hiddenhausen, Germany) and the corresponding unspecific antibody (mouse IgG_1) (DakoCytomation), respectively as negative control were applied to tissue sections in a humidified chamber and incubated over night at 8°C. The slides were washed in PBS and incubated with secondary biotinylated anti-mouse antibody (1 : 50 dilution; Dako) for 90 min at room temperature. After washing in PBS, the presence of antibody-antigen complexes was visualized using a streptavidin–peroxidase solution (1 : 250 dilution; Dako) and AEC (3-amino-9-ethylcarbazole) as the chromogen (Dako).

Histological analysis

For image acquisition, a colour CCD camera (Color View III; Olympus, Hamburg, Germany) mounted on a binocular light microscope (Olympus BX50; Olympus) was used. Digital images (original magnification ×200) were evaluated using a software program (Cell D®; Soft Imaging System, Münster, Germany).

The following landmarks were identified in the stained sections at both vestibular and oral aspects: implant shoulder (IS), mucosal margin (PM), the apical extension of the long junctional epithelium (aJE) and the most coronal level of bone in contact (CBI) with the implant. Linear measurements were made by drawing a vertical line, following the long axis of the implant, from PM to aJE, aJE to CBI, IS to aJE and IS to CBI at both buccal and lingual aspects. The amount of subepithelial connective tissue contact (STC) to the abutment/implant surface was measured as percentage of the distance from aJE to CBI, serving as 100%. Along aJE to CBI and in close proximity to the abutment/implant surface, a subepithelial connective tissue zone of 2 mm in width was demarcated as region of interest for the immunohistomorphometrical analysis. Within this area, the CI antigen reactivity was automatically assessed (%) by the image analysis software (Figs 2 and 3).

Prior to the start of the morphometrical analyses, a calibration procedure was initiated for both the masked investigator (K.B.) and the image analysis software and revealed that repeated measurements of $n = 6$ different sections were similar at >95% level, respectively.

Statistical analysis

The statistical analysis was performed using a commercially available software program (PASW Statistics 20.0; SPSS Inc., Chicago, IL, USA). Mean values, standard deviations and medians among animals were calculated for each variable and group. Owing to the small number of animals, only descriptive statistical analyses were applied.

Results

In all animals, the postoperative healing was considered as generally uneventful. Throughout the entire study period, no complications such as allergic reactions, abscesses or infections were noted. The experimental procedures had no influence on the health status, behaviour or feeding habit of each animal. The oral hygiene programme successfully prevented plaque biofilm formation at the transmucosal aspect of all abutments investigated.

© 2012 John Wiley & Sons A/S

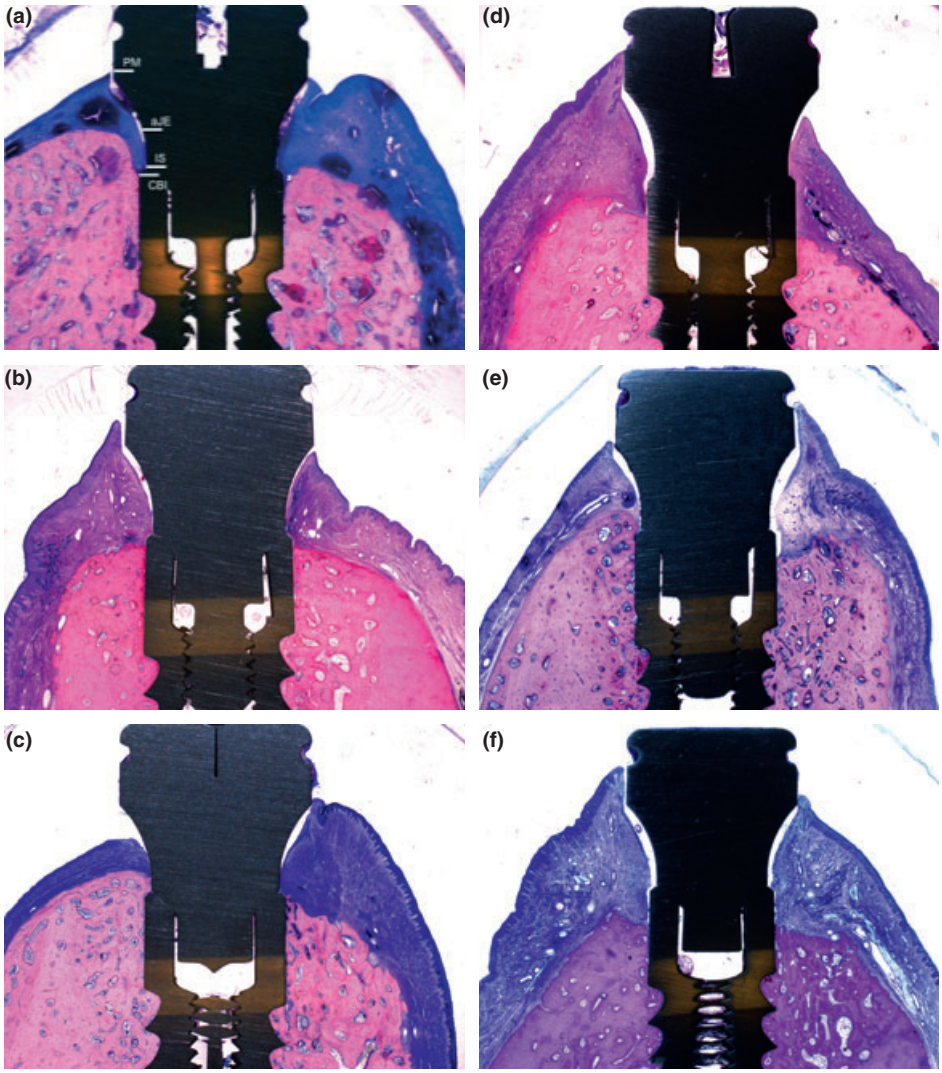

Fig. 2. Representative histological views (Paragon stain) of wound healing in different groups at 6 and 8 weeks (original magnification ×25). LP and LC abutments preserved crestal bone levels and increased subepithelial connective tissue contact areas when compared with M abutments. In both groups, however, a repeated abutment (2×) dis-/reconnection was associated with a disruption of the mucosal seal, an apical displacement of the subepithelial connective tissue zone, thus resulting in crestal bone level changes at 8 weeks (left-vestibular). (a) M: control; (d) M: test (2×); (b) LP: control; (e) LP: test (2×); (c) LC: control; (f) LC: test (2×).

Histological/Immunohistochemical observations

The mean values and medians of PM-aJE, aJE-CBI, IS-aJE, IS-CBI and STC values in different groups at 6 and 8 weeks after implant placement are summarized in Tables 1 and 2.

At control sites, PM-aJE values (mean and median) were comparable at M, LP and LC abutments. In these groups, aJE was commonly located on a level coronal to IS, as indicated by positive IS-aJE values at 6 and 8 weeks (Tables 1 and 2). In contrast, both LP and LC abutments revealed lower aJE-CBI and subsequently IS-CBI values when compared with the M group. This was particularly true for IS-CBI values (mean and median) noted at LC abutments (Tables 1 and 2).

Similar results were also observed for STC values (mean and median). In particular, at 6 and 8 weeks, LP and LC abutments were associated with increased STC areas at both vestibular and oral aspects when compared with the M group. While these values were almost stable over time at M abutments, both LP and LC abutments revealed further increases at 8 weeks when compared with the data assessed after 6 weeks of healing (Tables 1 and 2). Histological analysis revealed that in some specimens of all groups investigated, IS was obviously placed in a slight subcrestal position at the oral aspect. At these sites, M abutments were separated from the adjacent alveolar bone by a nonmineralized tissue. In contrast, both LP and LC abutments had frequently established a close bone contact at the crestal aspect of the abutment surface (Figs 2a–c and 3b).

In all groups investigated, a single- (1×) and repeated (2×) abutment dis-/reconnection was associated with uneven increases of aJE-CBI and IS-CBI values as well as decreases of STC values (mean and median) (Fig. 2d–f). In the L groups, STC changes were more pronounced at LC abutments when compared with the corresponding control sites at 8 weeks (Tables 1 and 2).

Immunohistochemical analysis at 6 and 8 weeks revealed a comparable but increasing CI antigen reactivity adjacent to all control abutments (Table 3). In particular, the subepithelial connective tissue was commonly characterized by well-organized collagen fibres running in different directions. While in the outer zone, most of these fibres were oriented in a direction parallel to the abutment, the fibre bundles in the inner zone were oriented perpendicular towards the abutment/implant surface. No obvious differences in fibre orientation were noted between M, LC or LP abutments (Fig. 3a–d).

After a single- (1×) and repeated (2×) abutment dis-/reconnection, the established mucosal seal was obviously disrupted at all specimens investigated. While at most sites, aJE was still located at or slightly above IS (Tables 1 and 2), the subepithelial connective tissue zone was displaced in an apical direction and frequently associated with a saucer-like bone resorption (Fig. 3e). Adjacent to all test abutments, CI antigen reactivity (mean and median) tended to be increased after a single- (1×) abutment manipulation, but remained stable subsequent to a repeated (2×) abutment dis-/reconnection (Table 3). Histological observation at 8 weeks, however, has pointed to an obvious decrease of collagen type-I fibre density in the inner zone at all test abutments investigated (Fig. 3f).

Discussion

The present study was designed to investigate the impact of LP and LC abutments on soft-tissue integration of titanium implants, and to assess the influence of a repeated dis-/reconnection during the healing phase on the mucosal seal in respective groups.

At control sites, it was basically observed that both LP and LC abutments were associated with decreased aJE-CBI and IS-CBI as well as increased STC values after 6 and 8 weeks of healing. Immunohistochemical analysis of CI antigen reactivity has pointed to a more frequent perpendicular fibre orientation in the inner subepithelial connective

© 2012 John Wiley & Sons A/S

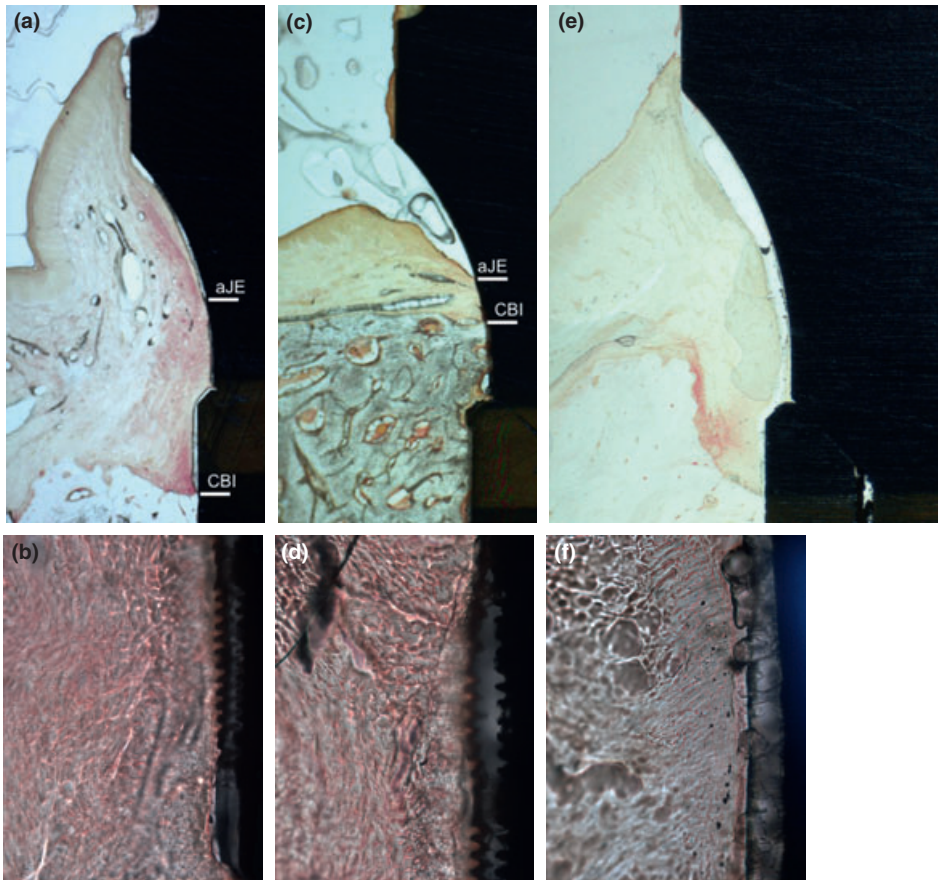

Fig. 3. Immunohistochemical views (Collagen Type-I) (original magnification ×40) at 8 weeks. (a) LC abutments commonly established an intimate contact with the subepithelial connective tissue (control, oral aspect); (b) Parallel fibre alignment in the outer zone (LC, control, vestibular aspect); (c) Subcrestal positioning of IS was associated with the establishment of a close bone-to-abutment/implant contact in the LP group (control, oral aspect); (d) Perpendicular orientation towards the inner zone (LC, control, vestibular aspect); (e) A repeated abutment dis-/reconnection resulted in an apical displacement of the subepithelial connective tissue zone (test, oral aspect); (f) Abutment manipulation was associated with a decreased CI antigen reactivity in the inner zone (M, vestibular aspect). aJE, the apical extension of the long junctional epithelium; CBI, the most coronal level of bone in contact with the implant.

tissue zone facing microgrooved surface areas. In this context, it must be emphasized that CI fibres represent a major organic component of the peri-implant mucosa and mainly run parallel with common abutment surfaces (Berglundh et al. 1991, 2007; Romanos et al. 1995; Abrahamsson et al. 1998).

The observation that L microgrooves may enhance connective tissue attachment in the transmucosal area is in agreement with the results of a previous experimental study performed in canines (Nevins et al. 2010). In particular, at 12 weeks after implant placement, LP abutments also limited the apical downgrowth of the barrier epithelium and established a close adhesion of connective tissue fibres running towards the microgrooved band. Similar to the present data, some specimens also revealed a direct bone attachment to the L abutment surface. In contrast, M abutments were associated with an increased apical extension of the junctional epithelium, thus reducing connective tissue attachment and increasing bone loss (Nevins et al. 2010). Basically, the observation that a reduction of mean PM-aJE values is associated with a preservation of crestal bone levels was also demonstrated in numerous preclinical studies performed in dogs. In these experiments, the effect was either accomplished by hydrophilic titanium surfaces (Schwarz et al. 2007a, 2010), or the use of a platform-switched implant abutment configuration (Becker et al. 2007, 2009). In particular, at hydrophilic one-part implants (Schwarz et al. 2010), mean PM-aJE values at 8 weeks varied between 0.96 ± 0.15 mm and 1.21 ± 0.43 mm, thus resulting in mean aJE-CBI values of 1.21 ± 0.31 mm to 1.48 ± 0.24 mm, respectively. At M surfaces, these numbers were obviously increased, and varied between 1.76 ± 0.17 mm and 1.80 ± 0.60 mm for mean PM-aJE, and 1.06 ± 0.27 mm and 1.60 ± 0.33 mm for mean aJE-CBI values (Schwarz et al. 2010). At platform-switched two-part implants using M abutments, mean IS-aJE and IS-CBI values at vestibular/oral aspects were 0.0 ± 0.5/0.0 ± 0.1 mm and 1.0 ± 0.4/1.0 ± 0.3 mm, respectively. These values were maintained over a period of 24 weeks, thus resulting in mean IS-aJE and IS-CBI values of 0.0 ± 0.1/0.1 ± 0.2 mm and 0.9 ± 0.4/0.9 ± 0.4 mm, respectively (Becker et al. 2009). As marginal bone level alterations could be related to the extent of the circumferential mismatch (>4 mm) (Canullo et al. 2010), it may be suggested that the present reductions in aJE-CBI and IS-CBI values were mainly related to the specific laser microgrooved surface rather than the effect of a 0.1 mm platform-switched implant–abutment configuration. In this context, it must also be emphasized that aJE-CBI and IS-CBI values as noted in the present study were obviously not influenced by the extent of the L zone (i.e. LP or LC). However, LC abutments increased STC values and may therefore offer some advantages over a LC configuration. In this context, it must be emphasized that the assessment of STC did not consider any artefacts (i.e. traumatic detachment) potentially generated during histological processing, and therefore, these values may be interpreted with caution.

Table 1. **Mean values ± SD and (medians) of PM-aJE, aJE-CBI, IS-aJE, IS-CBI (in mm ±SD) and STC (in % ±SD) at vestibular and oral aspects in different groups at 6 weeks after implant placement (i.e. 1× abutment dis-/reconnection) (*n* = 3 dogs)**

Group	Modification	PM-aJE	aJE-CBI	IS-aJE	IS-CBI	STC
Test (1×)	M	1.60 ± 0.78 (1.60)	1.63 ± 0.18 (1.63)	0.86 ± 0.66 (0.86)	0.76 ± 0.48 (0.76)	17.15 ± 20.89 (17.15)
	LP	1.89 ± 0.072 (1.89)	1.37 ± 0.55 (1.37)	0.67 ± 0.23 (0.67)	0.70 ± 0.31 (0.70)	64.95 ± 20.19 (64.95)
	LC	2.16 ± 0.81 (2.16)	1.41 ± 0.09 (1.41)	0.96 ± 0.39 (0.96)	0.45 ± 0.29 (0.45)	26.68 ± 4.74 (26.68)
Control	M	1.52 ± 0.11 (1.49)	2.25 ± 0.69 (2.39)	0.97 ± 0.46 (1.13)	1.57 ± 0.79 (1.93)	61.01 ± 14.81 (57.44)
	LP	1.82 ± 0.83 (1.91)	1.80 ± 0.71 (1.80)	0.99 ± 0.57 (0.92)	0.71 ± 0.66 (0.41)	44.72 ± 22.91 (48.45)
	LC	1.80 ± 0.66 (1.80)	1.16 ± 0.40 (1.16)	0.91 ± 0.26 (0.91)	0.50 ± 0.45 (0.50)	91.88 ± 8.55 (91.88)

© 2012 John Wiley & Sons A/S

Table 2. **Mean values ± SD and (medians) of PM-aJE, aJE-CBI, IS-aJE, IS-CBI (in mm ±SD) and STC (in % ±SD) at vestibular and oral aspects in different groups at 8 weeks after implant placement (i.e. 2× abutment dis-/reconnection) (*n* = 3 dogs)**

Group	Modification	PM-aJE	aJE-CBI	IS-aJE	IS-CBI	STC
Test (2×)	M	2.34 ± 0.69 (2.41)	1.77 ± 0.52 (1.79)	0.60 ± 0.35 (0.60)	1.06 ± 0.34 (1.13)	37.76 ± 38.08 (33.95)
	LP	1.36 ± 0.27 (1.51)	2.89 ± 1.09 (3.41)	1.35 ± 0.40 (1.21)	1.53 ± 1.09 (1.61)	57.34 ± 43.06 (76.30)
	LC	1.44 ± 0.34 (1.44)	1.83 ± 0.26 (1.83)	0.88 ± 0.17 (0.88)	0.94 ± 0.17 (0.94)	13.26 ± 19.04 (13.26)
Control	M	1.43 ± 0.15 (1.46)	2.08 ± 1.26 (1.39)	0.41 ± 0.22 (0.44)	1.66 ± 1.26 (1.20)	54.17 ± 8.09 (58.05)
	LP	1.55 ± 0.53 (1.31)	1.19 ± 1.05 (1.41)	0.80 ± 0.16 (0.82)	0.95 ± 0.51 (0.94)	82.58 ± 24.32 (92.95)
	LC	1.18 ± 0.26 (1.18)	1.22 ± 0.69 (1.22)	0.77 ± 0.80 (0.77)	0.54 ± 0.63 (0.54)	96.37 ± 5.12 (96.37)

Table 3. **Mean values ± SD and (medians) of Collagen Type-I (in % ±SD) at vestibular and oral aspects in different groups at 6 and 8 weeks after implant placement (i.e. 1× and 2× abutment dis-/reconnection) (*n* = 6 dogs)**

Modification	Control (6 weeks)	Test (1×)	Control (8 weeks)	Test (2×)
M	2.36 ± 6.60 (2.36)	4.17 ± 2.44 (4.17)	9.22 ± 1.59 (9.22)	4.32 ± 4.97 (4.32)
LP	7.69 ± 9.42 (7.69)	8.10 ± 3.45 (8.10)	18.42 ± 13.16 (19.80)	6.08 ± 7.03 (6.08)
LC	2.21 ± 1.78 (2.21)	2.82 ± 2.52 (2.82)	3.34 ± 2.80 (3.34)	5.65 ± 3.90 (5.65)

When further evaluating the present results, it was observed that a repeated abutment manipulation was commonly associated with a disruption of the established mucosal seal, thus resulting in obvious increases of aJE-CBI and IS-CBI values as well as decreased STC values.

The detrimental effect of a repeated abutment dis-/reconnection on soft- and hard-tissue levels is in agreement with previous and recent preclinical data (Abrahamsson et al. 1997; Rodriguez et al. 2011). In particular, matching commercially pure Ti abutments were manipulated altogether 5 times, once a month over a 6-month period of plaque control. At these sites, mean PM-aJE, aJE-CBI and IS-CBI values were 2.50 ± 0.42 mm, 1.65 ± 0.24 mm and 1.49 ± 0.19 mm, respectively. At control sites, these values were 2.04 ± 0.22 mm, 1.28 ± 0.11 mm and 0.78 ± 0.17 mm, respectively, reaching statistical significance when comparing mean IS-CBI and PM-IS values between both groups (Abrahamsson et al. 1997). These detrimental effects were obviously reduced at platform-switched implants (Rodriguez et al. 2011). In particular, at these sites, a repeated (4×) dis-/reconnection resulted in a significantly reduced radiographic bone loss when compared with matching implant–abutment configurations (vertical: 0.24 ± 0.08 mm vs. 1.09 ± 0.25 mm/horizontal: 0.24 ± 0.13 mm vs. 0.98 ± 0.27 mm) (Rodriguez et al. 2011). The latter observation is also in agreement with the present finding that aJE was still located at or slightly above IS in all test groups investigated. Accordingly, increases in IS-CBI after a single- (1×) or repeated (2×) abutment manipulation were mainly related to an apical shift of the connective tissue zone, rather than increases in PM-aJE values.

Within the limitations of the present study, it was concluded that LC>LP abutments enhanced subepithelial connective tissue attachment and preserved crestal bone levels. As a repeated abutment dis-/reconnection during the initial healing phase (4–6 weeks) may be associated with increased soft and hard-tissue changes, the clinician is advised to consider LP and LC using a one abutment, one time approach.

Acknowledgements: We kindly appreciate the skills and commitment of Ms Brigitte Hartig and Ms Tina Hagena in the preparation of the immunohistochemical specimens, as well as the competent assistance of Dr Martin Sager and Ms Eva Engelhardt (Animal Research Institute, Heinrich Heine University).

Conflict of interests

The authors declare that they have no conflict of interests related to this study.

Source of funding

The study was funded by an unrestricted grant of BioHorizons, Birmingham AL, USA.

References

Abrahamsson, I., Berglundh, T., Glantz, P.O. & Lindhe, J. (1998) The mucosal attachment at different abutments. An experimental study in dogs. *Journal of Clinical Periodontology* **25**: 721–727.

Abrahamsson, I., Berglundh, T. & Lindhe, J. (1997) The mucosal barrier following abutment dis/reconnection. An experimental study in dogs. *Journal of Clinical Periodontology* **24**: 568–572.

Abrahamsson, I., Berglundh, T., Wennstrom, J. & Lindhe, J. (1996) The peri-implant hard and soft tissues at different implant systems. A comparative study in the dog. *Clinical Oral Implants Research* **7**: 212–219.

Becker, J., Ferrari, D., Herten, M., Kirsch, A., Schaer, A. & Schwarz, F. (2007) Influence of platform switching on crestal bone changes at non-submerged titanium implants: a histomorphometrical study in dogs. *Journal of Clinical Periodontology* **34**: 1089–1096.

Becker, J., Ferrari, D., Mihatovic, I., Sahm, N., Schaer, A. & Schwarz, F. (2009) Stability of crestal bone level at platform-switched non-submerged titanium implants: a histomorphometrical study in dogs. *Journal of Clinical Periodontology* **36**: 532–539.

Berglundh, T., Abrahamsson, I., Welander, M., Lang, N.P. & Lindhe, J. (2007) Morphogenesis of the peri-implant mucosa: an experimental study in dogs. *Clinical Oral Implants Research* **18**: 1–8.

Berglundh, T., Lindhe, J., Ericsson, I., Marinello, C. P., Liljenberg, B. & Thomsen, P. (1991) The soft tissue barrier at implants and teeth. *Clinical Oral Implants Research* **2**: 81–90.

Berglundh, T., Lindhe, J., Jonsson, K. & Ericsson, I. (1994) The topography of the vascular systems in the periodontal and peri-implant tissues in the dog. *Journal of Clinical Periodontology* **21**: 189–193.

Buser, D., Weber, H.P., Donath, K., Fiorellini, J.P., Paquette, D.W. & Williams, R.C. (1992) Soft tissue reactions to non-submerged unloaded titanium implants in beagle dogs. *Journal of Periodontology* **63**: 225–235.

Canullo, L., Fedele, G.R., Iannello, G. & Jepsen, S. (2010) Platform switching and marginal bone-level alterations: the results of a randomized-controlled trial. *Clinical Oral Implants Research* **21**: 115–121.

© 2012 John Wiley & Sons A/S

Comut, A.A., Weber, H.P., Shortkroff, S., Cui, F.Z. & Spector, M. (2001) Connective tissue orientation around dental implants in a canine model. *Clinical Oral Implants Research* **12**: 433–440.

Kloss, F.R., Steinmuller-Nethl, D., Stigler, R.G., Ennemoser, T., Rasse, M. & Hachl, O. (2011) In vivo investigation on connective tissue healing to polished surfaces with different surface wettability. *Clinical Oral Implants Research* **22**: 699–705.

Nevins, M., Kim, D.M., Jun, S.H., Guze, K., Schupbach, P. & Nevins, M.L. (2010) Histologic evidence of a connective tissue attachment to laser microgrooved abutments: a canine study. *International Journal of Periodontics and Restorative Dentistry* **30**: 245–255.

Nevins, M., Nevins, M.L., Camelo, M., Boyesen, J.L. & Kim, D.M. (2008) Human histologic evidence of a connective tissue attachment to a dental implant. *International Journal of Periodontics and Restorative Dentistry* **28**: 111–121.

Rodriguez, X., Vela, X., Mendez, V., Segala, M., Calvo-Guirado, J.L. & Tarnow, D.P. (2011) The effect of abutment dis/reconnections on periimplant bone resorption: a radiologic study of platform-switched and non-platform-switched implants placed in animals. *Clinical Oral Implants Research* doi: 10.1111/j.1600-0501.2011.02317.x.

Romanos, G.E., Schroter-Kermani, C., Weingart, D. & Strub, J.R. (1995) Health human periodontal versus peri-implant gingival tissues: an immunohistochemical differentiation of the extracellular matrix. *International Journal of Oral and Maxillofacial Implants* **10**: 750–758.

Schwarz, F., Ferrari, D., Herten, M., Mihatovic, I., Wieland, M., Sager, M. & Becker, J. (2007a) Effects of surface hydrophilicity and microtopography on early stages of soft and hard tissue integration at non-submerged titanium implants: an immunohistochemical study in dogs. *Journal of Periodontology* **78**: 2171–2184.

Schwarz, F., Herten, M., Sager, M., Wieland, M., Dard, M. & Becker, J. (2007a) Histological and immunohistochemical analysis of initial and early osseous integration at chemically modified and conventional SLA titanium implants: preliminary results of a pilot study in dogs. *Clinical Oral Implants Research* **18**: 481–488.

Schwarz, F., Herten, M., Sager, M., Wieland, M., Dard, M. & Becker, J. (2007b) Histological and immunohistochemical analysis of initial and early subepithelial connective tissue attachment at chemically modified and conventional SLA titanium implants. A pilot study in dogs. *Clinical Oral Investigations* **11**: 245–255.

Schwarz, F., Mihatovic, I., Ferrari, D., Wieland, M. & Becker, J. (2010) Influence of frequent clinical probing during the healing phase on healthy periimplant soft tissue formed at different titanium implant surfaces: a histomorphometrical study in dogs. *Journal of Clinical Periodontology* **37**: 551–562.

Tete, S., Mastrangelo, F., Bianchi, A., Zizzari, V. & Scarano, A. (2009) Collagen fiber orientation around machined titanium and zirconia dental implant necks: an animal study. *International Journal of Oral and Maxillofacial Implants* **24**: 52–58.

© 2012 John Wiley & Sons A/S