Reattachment of Connective Tissue Fibers to a Laser-Microgrooved Abutment Surface

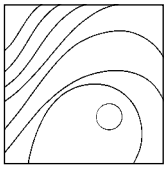

Myron Nevins, DDS[1]/Marcelo Camelo, DDS[2]
Marc L. Nevins, DMD, MMSc[3]/Peter Schupbach, PhD[4]
David M. Kim, DDS, DMSc[5]

This report presents human evidence of reattachment of the connective tissue when a laser-microgrooved healing abutment was replaced with a laser-microgrooved cylindric definitive abutment. No additional bone loss was noted 15 weeks after placement of the laser-microgrooved cylindric definitive abutment. Dense connective tissue was in intimate contact with the laser-microgrooved surface to the point of the soft tissue separation, and clear evidence of the junctional epithelium ending at the coronal-most position of the laser-microgrooved zone was identified. (Int J Periodontics Restorative Dent 2012;32:e131–e134.)

[1]Associate Clinical Professor, Division of Periodontology, Department of Oral Medicine, Infection and Immunity, Harvard School of Dental Medicine, Boston, Massachusetts, USA.
[2]Institute for Advanced Dental Studies, Belo Horizonte, Brazil.
[3]Assistant Clinical Professor, Division of Periodontology, Department of Oral Medicine, Infection and Immunity, Harvard School of Dental Medicine, Boston, Massachusetts, USA.
[4]Schupbach Ltd, Service and Research Laboratory for Biomaterials, Histology and Imaging, Horgen, Switzerland.
[5]Assistant Professor, Division of Periodontology, Department of Oral Medicine, Infection and Immunity, Harvard School of Dental Medicine, Boston, Massachusetts, USA.

Correspondence to: Dr Myron Nevins, Division of Periodontology, Department of Oral Medicine, Infection and Immunity, Harvard School of Dental Medicine, 188 Longwood Ave, Boston, MA 02115; fax: 617-432-1897; email: nevinsperimp@aol.com.

Soft tissue alteration as well as crestal bone resorption may occur at healing or definitive abutment connection for a two-stage dental implant system.[1–3] This has been challenged by the clinical observation of the bone-preserving effects of laser-microgrooved channel implants and abutments demonstrated in both preclinical and clinical studies.[4–8] A laser-created microchannel surface has the ability to reduce or eliminate crestal bone loss by promoting physical attachment of the connective tissue fiber and has the potential for significant esthetic and clinical benefits.

A recent study confirmed previous preclinical results of physical connective tissue attachment to the laser-microgrooved healing abutments, preventing the apical migration of the junctional epithelium and thus protecting the underlying crestal bone from premature resorption.[8] Therefore, the question can be raised of whether this physical soft tissue attachment can be reestablished when the laser-microgrooved healing abutment is replaced by the laser-microgrooved

© 2012 BY QUINTESSENCE PUBLISHING CO, INC. PRINTING OF THIS DOCUMENT IS RESTRICTED TO PERSONAL USE ONLY.
NO PART OF MAY BE REPRODUCED OR TRANSMITTED IN ANY FORM WITHOUT WRITTEN PERMISSION FROM THE PUBLISHER.



Fig 1a (left) *Healing abutment with a 0.7-mm Laser-Lok microgrooved zone.*

Fig 1b (right) *Cylindric two-piece definitive abutment with a 0.7-mm Laser-Lok microgrooved zone.*



definitive abutment (Figs 1a and 1b).

This case report examined the feasibility of laser-microgrooved abutments in inducing reattachment of the peri-implant soft tissue after an abutment has been replaced.

Method and materials

A healthy male patient who previously participated in an implant retrieval study requiring removal of a single nonstrategic implant and the reconstruction of the biopsy site with bone graft[8] agreed to participate in this case. He signed an informed consent form based on the Helsinki Declaration of 1975, as revised in 2000. This patient received multiple dental implants and restorations at no cost.

This patient received multiple Resorbable Blast Textured Tapered Internal Implants with a 0.3-mm machined collar (BioHorizons) placed level to the osseous crest. Healing abutments with 0.7-mm laser-ablated microchannels at the implant-abutment junction were then connected to the implants (Fig 1a). At 10 weeks, three laser-microgrooved healing abutments were removed and replaced by laser-microgrooved cylindric definitive abutments (Figs 1b and 2). A healing period of an additional 15 weeks was allowed before a single soft tissue/definitive abutment assembly was removed using a gingivectomy procedure (Figs 3a and 3b). The specimen was placed immediately in fixative for histologic preparation and evaluation, and the patient received a conventional definitive abutment. Specimen preparation and anlaysis were reported previously.[8]

Results

Clinical and radiographic findings

The healing abutments demonstrated no signs of clinical inflammation at the 10-week postoperative visit. All implants were clinically stable, and radiographic examination suggested clinical integration at all sites. At that time, the healing abutments were replaced by definitive cylindric abutments with 0.7-mm laser-ablated microchannels. The soft tissue surrounding the laser-microgrooved cylindric definitive abutment was healthy at 15 weeks. Radiographic observations revealed the maintenance of the crestal bone level around all implants at all times (Figs 4 to 6).

© 2012 BY QUINTESSENCE PUBLISHING CO, INC. PRINTING OF THIS DOCUMENT IS RESTRICTED TO PERSONAL USE ONLY.
NO PART OF MAY BE REPRODUCED OR TRANSMITTED IN ANY FORM WITHOUT WRITTEN PERMISSION FROM THE PUBLISHER.

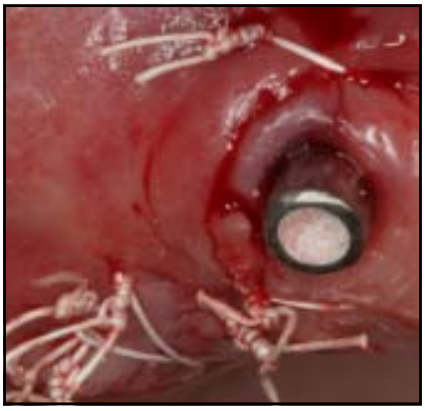

Fig 2 *Laser-microgrooved healing abutment replaced with a laser-microgrooved cylindric definitive abutment.*





Figs 3a (left) and 3b (right) *A gingivectomy procedure was performed to remove the peri-implant soft tissue cuff/abutment assembly.*

Fig 4 (left) *Radiograph taken the day of implant and healing abutment insertion.*

Fig 5 (center) *Ten weeks after implant/abutment placement.*

Fig 6 (right) *Fifteen weeks after the abutment-swapping procedure. Note the maintenance of the crestal bone level around the implant platform.*

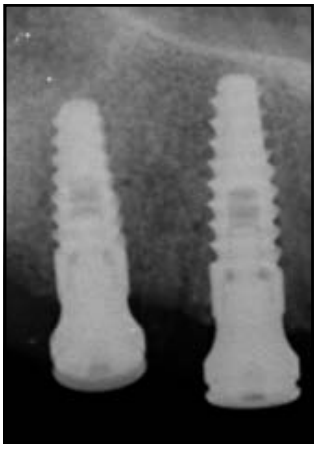

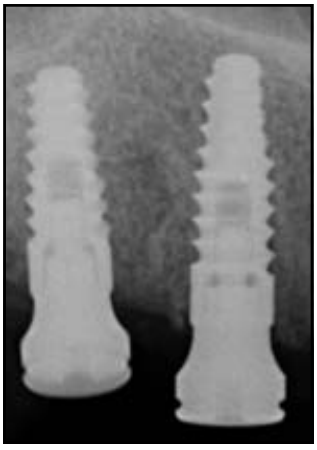



Histologic findings

The retrieved specimen demonstrated normal peri-abutment soft tissues without evidence of inflammatory cell infiltrate (Fig 7a). Polarized light imagery of mesial and distal surfaces revealed dense connective tissue fibers attaching directly to the laser-microgrooved abutment surfaces (Fig 7b). It was difficult to perform histologic analysis because of the fragility of the small specimen, where some connective tissue had been displaced. However, dense connective tissue was in intimate contact with the laser-microgrooved surface to the point of the soft tissue separation, and clear evidence of the junctional epithelium ending at the coronal-most position of the laser-microgrooved zone was identified (Fig 7b).

© 2012 BY QUINTESSENCE PUBLISHING CO, INC. PRINTING OF THIS DOCUMENT IS RESTRICTED TO PERSONAL USE ONLY.
NO PART OF MAY BE REPRODUCED OR TRANSMITTED IN ANY FORM WITHOUT WRITTEN PERMISSION FROM THE PUBLISHER.



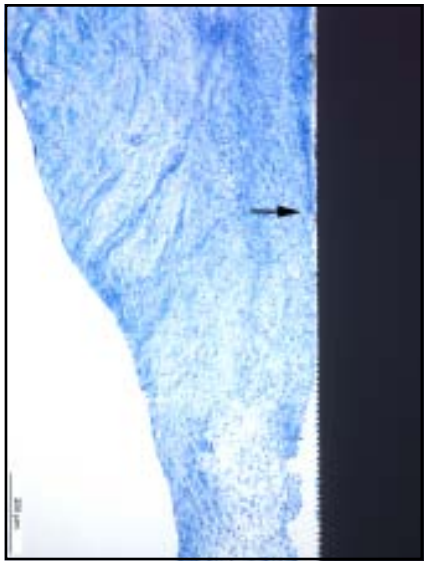

Figs 7a (left) **and 7b** (right) *The retrieved specimen demonstrated normal peri-abutment soft tissues, without evidence of inflammatory cell infiltrate. Polarized light imagery of the mesial and distal surfaces revealed dense connective tissue fibers attaching directly to the laser-microgrooved abutment surfaces. Arrow = apical end of the junctional epithelium.*

Discussion

This report presents human evidence of reattachment of the connective tissue when a laser-microgrooved healing abutment has been replaced with a laser-microgrooved cylindric definitive abutment. No additional bone loss was noted 15 weeks after placement of the laser-microgrooved cylindric definitive abutment. This finding adds support to the use of a laser-microgrooved healing and/or definitive abutment when multiple-abutment engagement is required. Follow-up studies with more subject enrollment are required to confirm these findings.

Acknowledgment

This study was supported by a grant from BioHorizons.

References

1. Hermann JS, Cochran DL, Nummikoski PV, Buser D. Crestal bone changes around titanium implants. A radiographic evaluation of unloaded nonsubmerged and submerged implants in the canine mandible. J Periodontol 1997;68:1117–1130.
2. Hermann JS, Schoolfield JD, Nummikoski PV, Buser D, Schenk RK, Cochran DL. Crestal bone changes around titanium implants: A methodologic study comparing linear radiographic with histometric measurements. Int J Oral Maxillofac Implants 2001;16:475–485.
3. Ericcson I, Persson LG, Berglundh T, Marinello CP, Lindhe J, Klinge B. Different types of inflammatory reactions in peri-implant soft tissues. J Clin Periodontol 1995;22:255–261.
4. Nevins M, Nevins ML, Camelo M, Boyesen JL, Kim DM. Human histologic evidence of a connective tissue attachment to a dental implant. Int J Periodontics Restorative Dent 2008;28:111–121.
5. Nevins M, Kim DM, Jun SH, Guze K, Schupbach P, Nevins ML. Histologic evidence of a connective tissue attachment to laser microgrooved abutments: A canine study. Int J Periodontics Restorative Dent 2010;30:245–255.
6. Shapoff CA, Lahey B, Wasserlauf PA, Kim DM. Radiographic analysis of crestal bone levels around Laser-Lok collar dental implants. Int J Periodontics Restorative Dent 2010;30:129–137.
7. Geurs NC, Vassilopoulos PJ, Reddy MS. Histologic evidence of connective tissue integration on laser microgrooved abutments in humans. Clin Adv Periodontics 2011;1:29–33.
8. Nevins M, Camelo M, Nevins ML, Schupbach P, Kim DM. Connective tissue attachment to laser-microgrooved abutments: A human histologic case report. Int J Periodontics Restorative Dent 2012;32:385–392.

© 2012 BY QUINTESSENCE PUBLISHING CO, INC. PRINTING OF THIS DOCUMENT IS RESTRICTED TO PERSONAL USE ONLY.
NO PART OF MAY BE REPRODUCED OR TRANSMITTED IN ANY FORM WITHOUT WRITTEN PERMISSION FROM THE PUBLISHER.