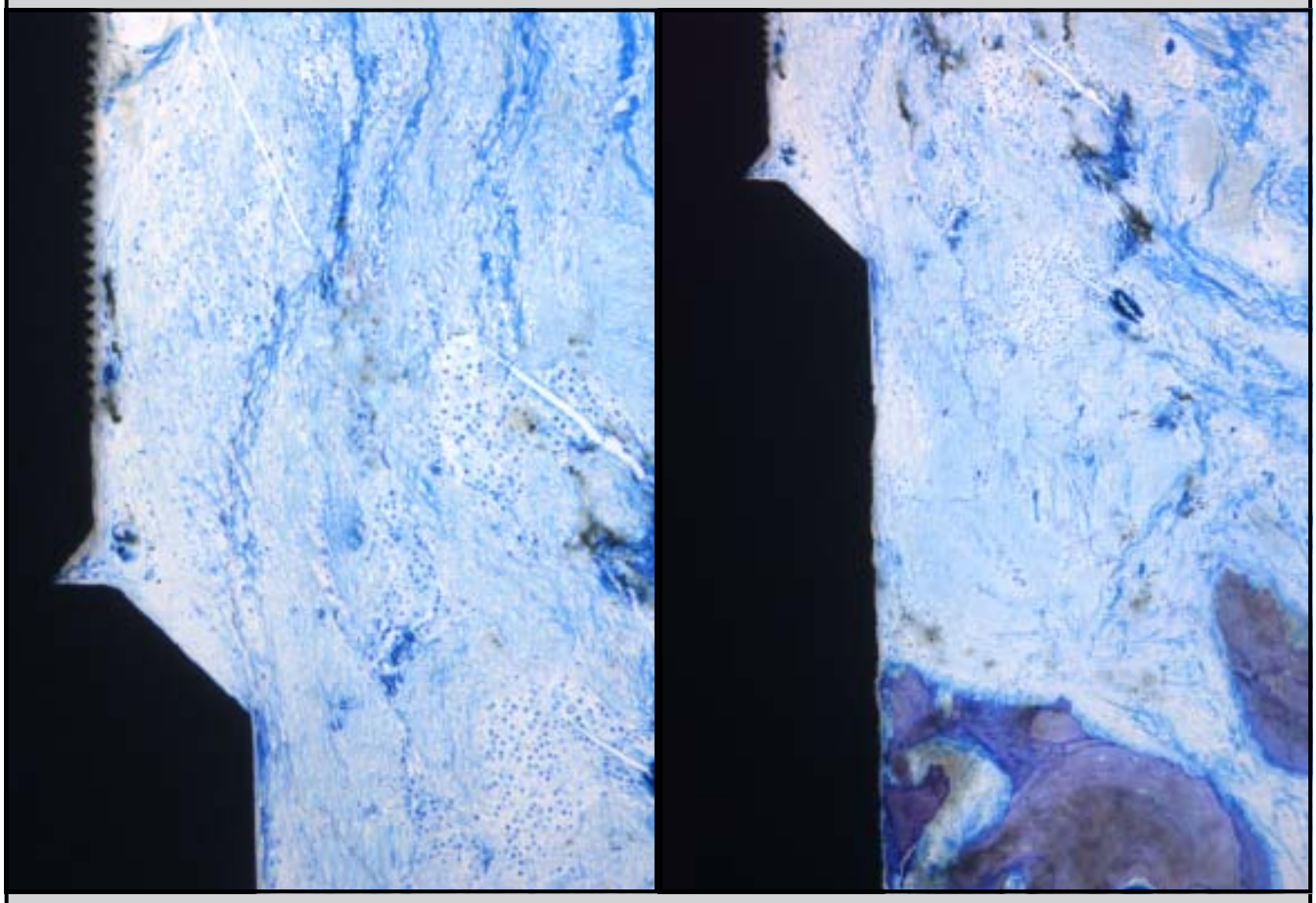

© 2012 BY QUINTESSENCE PUBLISHING CO, INC. PRINTING OF THIS DOCUMENT IS RESTRICTED TO PERSONAL USE ONLY.
NO PART OF MAY BE REPRODUCED OR TRANSMITTED IN ANY FORM WITHOUT WRITTEN PERMISSION FROM THE PUBLISHER.

Connective Tissue Attachment to Laser-Microgrooved Abutments: A Human Histologic Case Report



Myron Nevins, DDS[1]/Marcelo Camelo, DDS[2]
Marc L. Nevins, DMD, MMSc[3]/Peter Schupbach, PhD[4]
David M. Kim, DDS, DMSc[5]

Previous preclinical and clinical studies have demonstrated the effectiveness of precisely configured laser-ablated microgrooves placed on implant collars to allow direct connective tissue attachment to the implant surface. A recent canine study examining laser-ablated microgrooves placed in a defined healing abutment area demonstrated similar findings. In both instances, direct connective tissue attachment to the implant-abutment surface served as an obstacle to the apical migration of the junctional epithelium, thus preventing crestal bone resorption. The current case report examines the effectiveness of abutment-positioned laser-ablated microgrooves in human subjects. As in the preclinical trial, precisely defined laser-ablated microgrooves allowed direct connective tissue attachment to the altered abutment surface, prevented apical migration of the junctional epithelium, and thus protected the crestal bone from premature resorption. (Int J Periodontics Restorative Dent 2012;32:385–392.)

[1]Associate Clinical Professor, Division of Periodontology, Department of Oral Medicine, Infection and Immunity, Harvard School of Dental Medicine, Boston, Massachusetts, USA.
[2]Institute for Advanced Dental Studies, Belo Horizonte, Brazil.
[3]Assistant Clinical Professor, Division of Periodontology, Department of Oral Medicine, Infection and Immunity, Harvard School of Dental Medicine, Boston, Massachusetts, USA.
[4]Schupbach Ltd, Service and Research Laboratory for Biomaterials, Histology, and Imaging, Horgen, Switzerland.
[5]Assistant Professor, Division of Periodontology, Department of Oral Medicine, Infection and Immunity, Harvard School of Dental Medicine, Boston, Massachusetts, USA.

Correspondence to: Dr Myron Nevins, Division of Periodontology, Department of Oral Medicine, Infection and Immunity, Harvard School of Dental Medicine, 188 Longwood Ave, Boston, MA 02115; fax: 617-432-1897; email: nevinsperimp@aol.com.

Maintaining optimal esthetics and function for implant-supported restorations is dependent on a stable relationship between the underlying crestal bone and overlying mucosal tissue. This is especially true in the anterior esthetic zone of the maxilla, where maintenance of marginal gingival and papillary tissues depends on long-term crestal bone stability. Crestal bone loss of 0.5 to 2.0 mm following abutment attachment to the first implant thread is a commonly observed occurrence in the first year of implant function.[1–6] Beyond the first year, crestal bone loss may continue at a rate of approximately 0.1 mm annually, further jeopardizing the stable relationship of overlying soft tissue to underlying bone.[1–6]

Various dental implant designs have aspired to preserve the crestal bone. Previous investigations have examined the role precisely configured microchannels placed within the implant collar or within a defined healing abutment region may play in limiting the apical migration of the junctional epithelium, reducing or eliminating crestal bone loss

© 2012 BY QUINTESSENCE PUBLISHING CO, INC. PRINTING OF THIS DOCUMENT IS RESTRICTED TO PERSONAL USE ONLY.
NO PART OF MAY BE REPRODUCED OR TRANSMITTED IN ANY FORM WITHOUT WRITTEN PERMISSION FROM THE PUBLISHER.



Fig 1 *Healing abutment with a 0.7-mm Laser-Lok microgrooved zone.*

normally initiated at the implant-abutment junction (IAJ).[7–11] A prospective human clinical trial by Nevins et al demonstrated perpendicularly attached connective tissue fibers to precisely defined Laser-Lok microchannels placed within the implant collar, preventing apical migration of junctional epithelium and subsequent crestal bone loss.[9] A later preclinical canine study demonstrated perpendicularly oriented connective tissue fibers against Laser-Lok microgrooved areas placed within a specific band of the healing abutment.[10] As a result, microbial microleakage at the IAJ was prevented and apical migration of the junctional epithelium prohibited, resulting in no loss of peri-implant crestal bone following abutment attachment.[10]

The purpose of this proof-of-principle case report was to determine whether precisely defined Laser-Lok microchannels placed within a specific area of the implant abutment surface would promote direct connective tissue attachment, thereby inhibiting apical migration of the junctional epithelium in humans.

Method and materials

Two healthy partially edentulous adult patients were selected to test the hypothesis that 8-µm Laser-Lok microchannels applied to the healing abutment within a 0.7-mm-tall band positioned immediately above the IAJ would allow direct connective tissue fiber attachment, preventing apical migration of the junctional epithelium (Fig 1). Both patients volunteered for the protocol and signed an informed consent form based on the Helsinki Declaration of 1975, as revised in 2000. Both patients required multiple implants for implant-supported restorations and were thoroughly informed regarding the nature of the study and understood that he/she would receive enough implants so that one or more could be removed, allowing the remaining implants to support an implant-supported restoration.

Surgical implant placement

Full-thickness mucoperiosteal flaps were reflected with crestal incisions under local anesthesia, and implant osteotomies were performed. Resorbable Blast Textured Tapered Internal Implants with a 0.3-mm machined collar (BioHorizons) were placed as level to the osseous crest as possible (Fig 2a), and healing abutments with laser-ablated microchannels within the 0.7-mm-tall band were then connected to the implants. The mucoperiosteal flaps were closed tension-free with multiple 4.0 silk sutures (Fig 2b).

The patients were examined at 1, 2, 4, 8, and 10 weeks postsurgery. At 10 weeks, implants not critical to the definitive implant-supported restorations were harvested en bloc together with adjacent soft and hard tissues. The specimens were placed immediately in fixative for histologic

© 2012 BY QUINTESSENCE PUBLISHING CO, INC. PRINTING OF THIS DOCUMENT IS RESTRICTED TO PERSONAL USE ONLY.
NO PART OF MAY BE REPRODUCED OR TRANSMITTED IN ANY FORM WITHOUT WRITTEN PERMISSION FROM THE PUBLISHER.

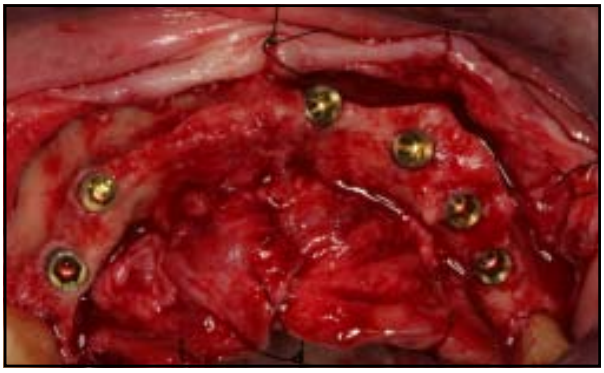

Fig 2a *Resorbable Blast Textured Tapered Internal Implants placed level to the osseous crest.*



Fig 2b *Healing abutments with Laser-Lok microchannels connected to the implants. Mucoperiosteal flaps were closed without tension.*

Fig 3 *At 10 weeks, healing was normal for patient 1, with no evidence of infection or inflammation.*



preparation and evaluation. The en bloc resected site was reconstructed to restore the natural ridge contour.

Specimen preparation and analysis

Fixed samples were dehydrated in a graded series of ethanols using a dehydration system with agitation and vacuum. The blocks were infiltrated with Technovit 7200 VLC resin (Heraeus Kulzer). Infiltrated specimens were placed into embedding molds, and polymerization was performed under ultraviolet light. Polymerized blocks were sectioned in the mesiodistal direction and parallel to the long axis of each implant. The slices were reduced by microgrinding and polishing using an Exakt grinding unit to an even thickness of 30 to 40 µm. Sections were stained with toluidine blue/Azur II and examined using both a Leica MZ16 stereomicroscope and a Leica 6000DRB light microscope.

Results

During the 10-week postoperative follow-up period, healing occurred without complication. Minimal to no inflammation was present, implants were clinically stable, and the radiographs suggested clinical integration for all implant sites (Fig 3). Lacking strategic importance for the definitive implant-supported restorations, two implants were planned for biopsy and histologic analysis.

© 2012 BY QUINTESSENCE PUBLISHING CO, INC. PRINTING OF THIS DOCUMENT IS RESTRICTED TO PERSONAL USE ONLY.
NO PART OF MAY BE REPRODUCED OR TRANSMITTED IN ANY FORM WITHOUT WRITTEN PERMISSION FROM THE PUBLISHER.



Fig 4a (left) *At low magnification, peri-abutment soft tissues were healthy, with no inflammatory cell infiltrate at the IAJ. A long junctional epithelium was absent, and excellent bone-to-implant contact was noted at all implant threads.*

Fig 4b (right) *At higher power magnification, direct contact* (arrows) *was seen between the Laser-Lok microchannels and adjacent connective tissue. Evidence of a long junctional epithelium was absent. LLA = Laser-Lok abutment; CT = connective tissue.*

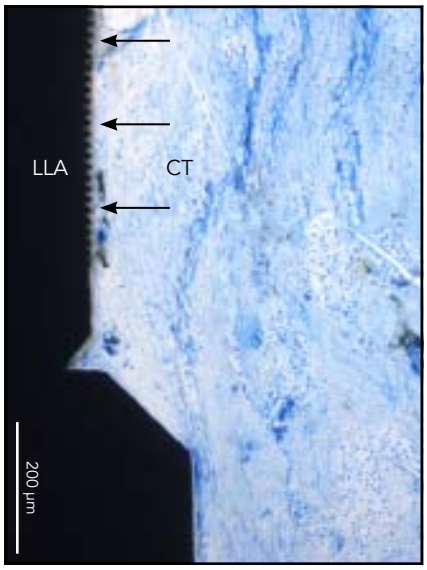

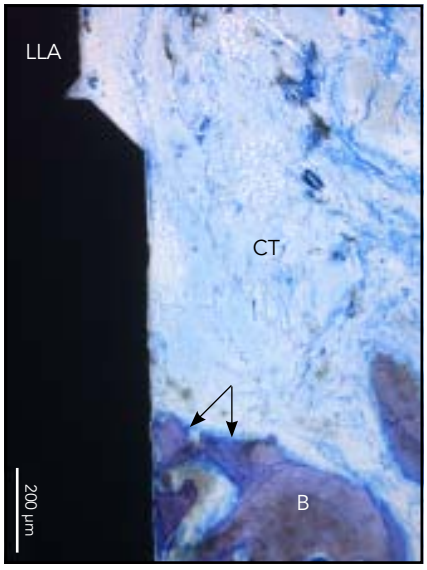

Fig 4c (left) *Crestal bone in close contact with the implant collar surface with new bone formation* (arrows) *and no evidence of bone loss apparent. LLA = Laser-Lok abutment; CT = connective tissue; B = bone.*

Fig 4d (right) *Polarized light image demonstrating obliquely attached connective tissue fibers* (arrows) *to the abutment surface, preventing the development of a long junctional epithelium. LLA = Laser-Lok abutment; CT = connective tissue.*

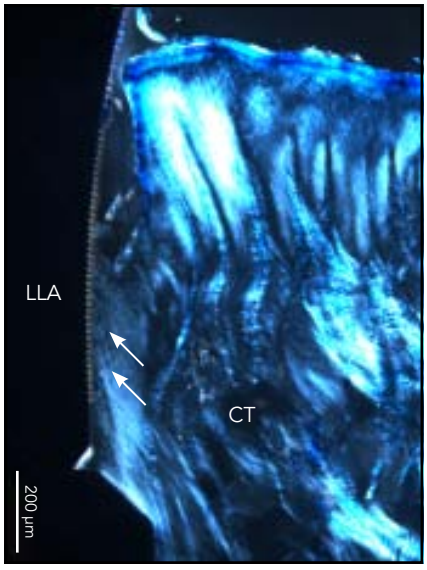

Histologic findings

Biopsy specimens demonstrated normal peri-abutment soft tissues, without evidence of inflammatory cell infiltrate at the IAJ at low magnification (Figs 4a to 4d and 5a to 5f). Excellent bone-to-implant contact was noted at all implant threads and on to the collar of the implant. It extended occlusally up to the polished collar (Fig 4a).

© 2012 BY QUINTESSENCE PUBLISHING CO, INC. PRINTING OF THIS DOCUMENT IS RESTRICTED TO PERSONAL USE ONLY.
NO PART OF MAY BE REPRODUCED OR TRANSMITTED IN ANY FORM WITHOUT WRITTEN PERMISSION FROM THE PUBLISHER.



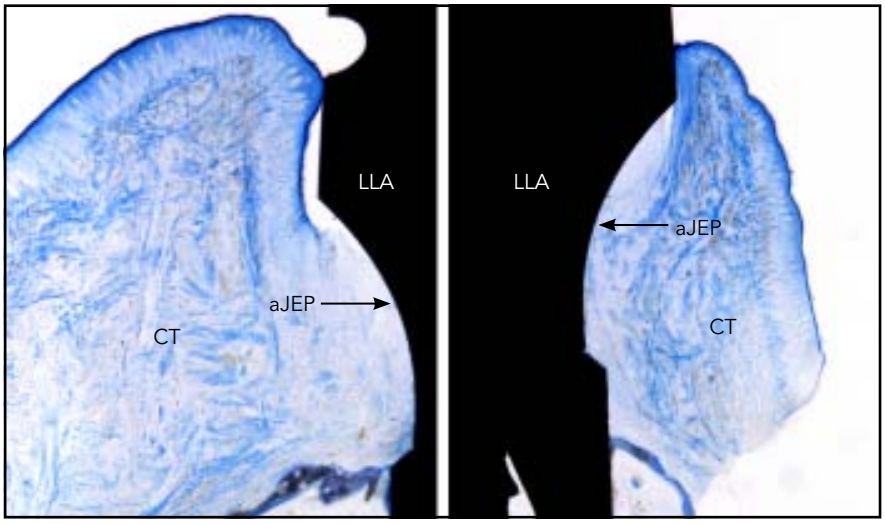

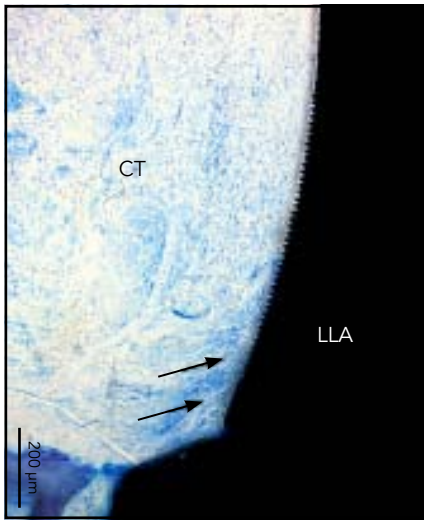



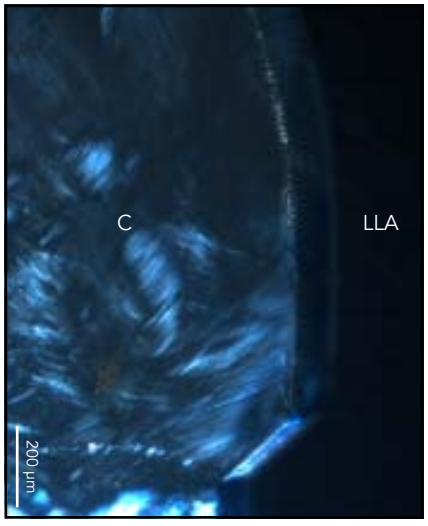

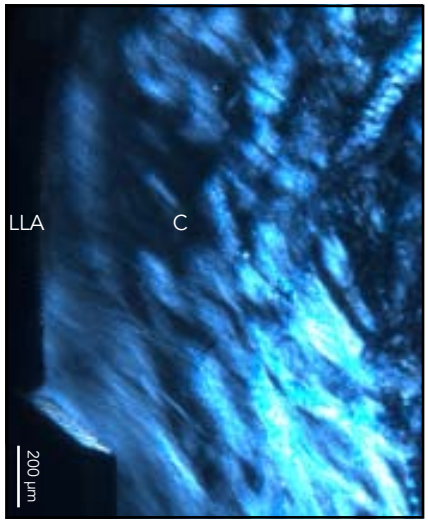

Fig 5a (above) *Low-power view of the en bloc specimen showing healthy connective tissue against all borders of the abutment surface. No evidence of crestal bone loss was seen on either side of the implant collar.*

Fig 5b (above right) *Medium-power view demonstrating healthy connective tissue in contact with the entire length of the Laser-Lok abutment microchannels, preventing the development of a long junctional epithelium. LLA = Laser-Lok abutment; CT = connective tissue; aJEP = apical end of junctional epithelium.*

Figs 5c (center left) **and 5d** (center right) *At higher power, dense connective tissue* (arrows) *was seen in intimate contact with the abutment Laser-Lok microgrooved surfaces. LLA = Laser-Lok abutment; CT = connective tissue.*

Figs 5e (bottom left) **and 5f** (bottom right) *Polarized light images demonstrating dense, obliquely oriented connective tissue fibers inserted directly into the Laser-Lok microgrooved abutment surfaces. LLA = Laser-Lok abutment; CT = connective tissue.*

© 2012 BY QUINTESSENCE PUBLISHING CO, INC. PRINTING OF THIS DOCUMENT IS RESTRICTED TO PERSONAL USE ONLY.
NO PART OF MAY BE REPRODUCED OR TRANSMITTED IN ANY FORM WITHOUT WRITTEN PERMISSION FROM THE PUBLISHER.

Type IV porous bone, typical of maxillary posterior alveolar bony anatomy, surrounded the entire implant from the coronal-most portions of the implant collar to the most apical end of the implant body on the second implant (Fig 5a). There was a slight discrepancy in bone level favoring the palatal crest. The implant was therefore placed at the level of the palatal bone, as reflected by the bone level at approximately the IAJ. The buccal bone extended on to the collar, approximately 1 mm apical to the level of the palatal bone. At higher magnification, dense connective tissue was noted in intimate contact with the entire length of the Laser-Lok microchannels. Importantly, healthy connective tissue extended apically into the IAJ, eliminating signs of an inflammatory cellular response often found in this region. Equally important, there was no evidence of epithelial migration along the surface of the abutment (Figs 4a to 4d and 5c to 5f).

Polarized light imagery of the mesial and distal surfaces revealed dense, obliquely oriented connective tissue fibers attaching directly to the Laser-Lok grooved abutment surfaces. In addition, connective tissue interposed itself directly into the region of the IAJ, effectively eliminating microgap-propagated inflammatory problems often seen at the interface between the abutment and implant (Figs 4d, 5e, and 5f).

Discussion

Preventing commonly observed crestal bone remodeling during the first year following abutment attachment has been an ongoing clinical challenge in implant dentistry. Multiple causes have been identified that contribute to this bone loss, including initial surgical trauma, occlusal overload leading to excessive stress at the crestal bone–implant interface, the need for a minimum biologic width dimension, and the bacterial and inflammatory cell infiltrate present at the IAJ microgap.[1–4,6,12–16] Mitigating the negative effects of the IAJ microgap through alterations in implant and abutment surface topography has been a focus of preclinical and clinical research.[7,9–11,17–20]

Normally, without specific three-dimensional geometric abutment and implant surface alterations, peri-implant connective tissue fibers tend to orient themselves parallel to the abutment-implant interface, permitting apical migration of the junctional epithelium.[21] Precisely configured implant or abutment laser-ablated microchannels, with depths and widths ranging from 8 to 12 μm, appear capable of altering epithelial, fibroblastic, and osteoblastic cellular migratory patterns across this microgrooved surface, resulting in a change in connective tissue orientation against the implant and abutment surfaces.[7,9,11,19,22]

© 2012 BY QUINTESSENCE PUBLISHING CO, INC. PRINTING OF THIS DOCUMENT IS RESTRICTED TO PERSONAL USE ONLY.
NO PART OF MAY BE REPRODUCED OR TRANSMITTED IN ANY FORM WITHOUT WRITTEN PERMISSION FROM THE PUBLISHER.

A prospective human study demonstrated that when placed on the implant collar adjacent to the IAJ, these 8- to 12-μm microchannels allowed direct, perpendicularly oriented supracrestal connective tissue fiber attachment to the implant surface, mitigating the negative influence of the IAJ microgap and preventing the apical migration of the junctional epithelium.[9] The net result was minimal to no crestal bone loss.

As in the natural dentition, a 3-mm width of peri-implant soft tissue analogous to the biologic width has been confirmed in both preclinical and clinical studies.[1–4] However, the microgap created at the IAJ tends to initiate an inflammatory infiltrate that promotes both osteoclast formation and activation and apical repositioning of healthy peri-implant connective tissue, resulting in the 1.5- to 2.0-mm loss of crestal bone seen during the first year following implant placement.[4,13–17]

Precisely configured topographic abutment surface modifications also influence connective tissue fiber attachment and orientation to the abutment surface. A canine study demonstrated the significant effects a 0.7-mm-tall abutment laser-ablated microchanneled zone placed adjacent to the IAJ could have on multiple variables, including inflammatory cell leakage at the IAJ microgap, peri-abutment soft tissue orientation, apical migration of a long junctional epithelium, and stability of peri-implant crestal bone.[10] Although the results of this preclinical study were significantly positive for each of these variables, the authors noted the need for a human prospective investigation to verify the results in human subjects. The current report was initiated as a proof-of-principle study to verify these preclinical findings in humans.

The profound influence specifically engineered three-dimensional abutment surface alterations have on cellular migratory activity and connective tissue fiber orientation was verified in this human study. As in the preclinical canine study, the presence of a 0.7-mm-tall laser-ablated 8- to 12-μm-deep microchanneled zone altered the directional orientation of peri-abutment connective tissue fibers. Unlike traditional abutment surfaces, the current laser-ablated surfaces enabled adjacent connective tissue fibers to attach obliquely to the 0.7-mm microchanneled zone, a directional orientation similar to that seen in the natural dentition. The change in directional orientation allowed the peri-abutment connective tissue to serve as an anatomical barrier to apical junctional epithelium migration. In addition, the oblique connective tissue fiber attachment adjacent to the IAJ appeared to reduce or eliminate the negative inflammatory sequelae commonly found at the IAJ microgap. The net result of the change in connective tissue fiber orientation against the Laser-Lok altered abutment surface was crestal bone stability throughout the duration of this prospective human study.

© 2012 BY QUINTESSENCE PUBLISHING CO, INC. PRINTING OF THIS DOCUMENT IS RESTRICTED TO PERSONAL USE ONLY.
NO PART OF MAY BE REPRODUCED OR TRANSMITTED IN ANY FORM WITHOUT WRITTEN PERMISSION FROM THE PUBLISHER.

Conclusions

This proof-of-principle study presents further documentation that precisely engineered abutment surface modifications can alter cellular soft tissue activity at the periabutment soft tissue interface and, in so doing, prevent commonly seen sequelae at the IAJ microgap from occurring. Clinical studies with high subject enrollment are needed to confirm these findings.

Acknowledgments

Special thanks to Dr Stuart Kay for his help with the organization and production of this manuscript. This study was supported by a grant from BioHorizons.

References

1. Hermann JS, Cochran DL, Nummikoski PV, Buser D. Crestal bone changes around titanium implants. A radiographic evaluation of unloaded nonsubmerged and submerged implants in the canine mandible. J Periodontol 1997;68:1117–1130.
2. Hermann JS, Buser D, Schenk RK, Higginbottom FL, Cochran DL. Biologic width around titanium implants. A physiologically formed and stable dimension over time. Clin Oral Implants Res 2000;11:1–11.
3. Hermann JS, Schoolfield JD, Nummikoski PV, Buser D, Schenk RD, Cochran DL. Crestal bone changes around titanium implants: A methodologic study comparing linear radiographic with histometric measurements. Int J Oral Maxillofac Implants 2001;16:475–485.
4. Berglundh T, Lindhe J. Dimension of the periimplant mucosa. Biological width revisited. J Clin Periodontol 1996;23: 971–973.
5. Richter EJ. Basic biomechanics of dental implants in prosthetic dentistry. J Prosthet Dent 1989;61:602–609.
6. van Steenberghe D, Lekholm U, Bolender C, et al. Applicability of osseointegrated oral implants in the rehabilitation of partial edentulism: A prospective multicenter study on 558 fixtures. Int J Oral Maxillofac Implants 1990;5:272–281.
7. Weiner S, Simon J, Ehrenberg DS, Zweig B, Ricci JL. The effects of laser microtextured collars upon crestal bone levels of dental implants. Implant Dent 2008; 17:217–228.
8. Alexander H, Ricci JL, Hrico GJ. Mechanical basis for bone retention around dental implants. J Biomed Mater Res B Appl Biomater 2009;88:306–311.
9. Nevins M, Nevins ML, Camelo M, Boyesen JL, Kim DM. Human histologic evidence of a connective tissue attachment to a dental implant. Int J Periodontics Restorative Dent 2008;28:111–121.
10. Nevins M, Kim DM, Jun SH, Guze K, Schupbach P, Nevins ML. Histologic evidence of a connective tissue attachment to laser microgrooved abutments: A canine study. Int J Periodontics Restorative Dent 2010;30:245–255.
11. Geurs NC, Vassilopoulos PJ, Reddy MS. Histologic evidence of connective tissue integration on laser microgrooved abutments in humans. Clin Adv Periodontics 2011;1:29–33.
12. Quirynen M, Naert I, van Steenberghe D, Nys L. A study of 589 consecutive implants supporting complete fixed prostheses. Part I: Periodontal aspects. J Prosthet Dent 1992;68:655–663.
13. Quirynen M, van Steenberghe D. Bacterial colonization of the internal part of two-stage implants. An in vivo study. Clin Oral Implants Res 1993;4:158–161.
14. Quirynen M, Bollen CM, Eyssen H, van Steenberghe D. Microbial penetration along the implant components of the Brånemark system. An in vitro study. Clin Oral Implants Res 1994;5:239–244.
15. Piatelli A, Vrespa G, Petrone G, Iezzi G, Annibali S, Scarano A. Role of the microgap between implant and abutment: A retrospective histologic evaluation in monkeys. J Periodontol 2003;74:346–352.
16. Ericcson I, Persson LG, Berglundh T, Marinello CP, Lindhe J, Klinge B. Different types of inflammatory reactions in peri-implant soft tissues. J Clin Periodontol 1995;22:255–261.
17. Abrahamsson I, Berglundh T, Lindhe J. The mucosal barrier following abutment dis/reconnection. An experimental study in dogs. J Clin Periodontol 1997; 24:568–572.
18. Hamilton DW, Chehroudi B, Brunette DM. Comparative response of epithelial cells and osteoblasts to microfabricated tapered pit topographies in vitro and in vivo. Biomaterials 2007;28:2281–2293.
19. Pecora G, Ceccarelli R, Bonelli I, Alexander H, Ricci JL. Clinical evaluation of laser microtexturing for soft tissue and bone attachment to dental implants. Implant Dent 2009;18:57–66.
20. Shapoff CA, Lahey B, Wasserlauf PA, Kim DM. Radiographic analysis of crestal bone levels around Laser-Lok collar dental implants. Int J Periodontics Restorative Dent 2010;30:129–137.
21. Schierano G, Ramieri G, Cortese M, Aimetti M, Preti G. Organization of the connective tissue barrier around long-term loaded implant abutments in man. Clin Oral Implants Res 2002;13:460–464.
22. Frenkel SR, Simon J, Alexander H, Dennis M, Ricci JL. Osseointegration on metallic implant surfaces: Effects of microgeometry and growth factor treatment. J Biomed Mater Res 2002;63:706–713.

© 2012 BY QUINTESSENCE PUBLISHING CO, INC. PRINTING OF THIS DOCUMENT IS RESTRICTED TO PERSONAL USE ONLY.
NO PART OF MAY BE REPRODUCED OR TRANSMITTED IN ANY FORM WITHOUT WRITTEN PERMISSION FROM THE PUBLISHER.