Implant rehabilitation of a denture-wearing patient with microstomia

Ursula Klostermyer, DDS, PhD[1]/Saul Weiner, DDS[2]/
Robert Flinton, DDS, MS[3]

The unusual treatment of a microstomia patient who was edentulous in the mandible is described. Impressions and registrations were taken with the help of sectional trays, and the treatment of choice for the final prosthesis was a two-piece, four-implant (BioHorizons)–supported bar overdenture with a connecting middle segment. *(Quintessence Int 2011;42:193–199)*

Key words: implant-supported overdenture, microstomia, sectional denture, sectional impression

The term *microstomia* is used to describe an abnormally reduced size of the oral aperture, severe enough to compromise esthetics, function, and quality of life. Normal maximal mouth opening is approximately 50 mm (measured from the inferior border of the upper lip to the superior border of the lower lip). The diagnosis of microstomia is made when function or esthetics has been compromised due to a markedly small oral aperture,[1,2] generally less than 20 mm.

Because of this limitation, microstomia patients must keep food bites small, have speech impediments, and may have great difficulty inserting and removing dental prostheses. Routine oral hygiene is difficult, which may result in advanced tooth decay, periodontal disease, and tooth loss. The situation is worsened by difficult access for dental treatment, therefore leading to treatment delays and more extensive dental disease. This article addresses a prosthodontic approach to management of a patient with acquired microstomia.

[1]Prosthodontist and Implant Fellow, New Jersey Dental School, University of Medicine and Dentistry of New Jersey, Newark, New Jersey, USA.

[2]Professor, Department of Prosthodontics and Biomaterials, New Jersey Dental School, University of Medicine and Dentistry of New Jersey, Newark, New Jersey, USA.

[3]Professor and Chair, Department of Restorative Dentistry; Director of the Postgraduate Program in Prosthodontics, New Jersey Dental School, University of Medicine and Dentistry of New Jersey, Newark, New Jersey, USA.

Correspondence: Dr Ursula Klostermyer, New Jersey Dental School, University of Medicine and Dentistry of New Jersey, 110 Bergen Street, Newark, NJ 07101-1709. Email: klosteur@umdnj.edu

CASE PRESENTATION

A 63-year-old woman presented in the Postgraduate Prosthodontic Clinic at the New Jersey Dental School, University of Medicine and Dentistry of New Jersey, with severe microstomia as a result of chemical burns 20 years prior (Fig 1). At the time, the patient was using a small maxillary removable partial denture retained by four remaining maxillary teeth but had been edentulous in the mandibular arch for several years.

© 2010 BY QUINTESSENCE PUBLISHING CO, INC. PRINTING OF THIS DOCUMENT IS RESTRICTED TO PERSONAL USE ONLY.
NO PART OF THIS ARTICLE MAY BE REPRODUCED OR TRANSMITTED IN ANY FORM WITHOUT WRITTEN PERMISSION FROM THE PUBLISHER.



Fig 1 Microstomia patient with limited opening (21 mm) as demonstrated by the diameter of a dental mirror. The maxilla has a removable partial denture on four abutment teeth, while the mandible is edentulous.



Fig 2 Preliminary impression—modified stock trays in two halves.

The maxillary prosthesis was deemed adequate for stability, retention, and function. In the mandibular arch, due to the restricted commissure, insertion of a complete mandibular denture was not possible. Different treatment options were considered[3–8]: The final plan was a two-segment, four-implant–supported bar overdenture.

Regular impression techniques cannot be utilized for a microstomia patient, because the tray cannot be inserted into the patient's mouth. Several sectional impression techniques are described in the literature,[3–7] but due to the complexity of this particular case, a novel technique was utilized.

For the preliminary impression, a modified, sectional stock tray with reduced walls and overlapping handles was used. The left half tray was loaded with alginate (Jeltrate Plus, Dentsply Caulk), inserted into the patient's mouth, and slightly border molded. After removal from the patient's mouth, the excess alginate was trimmed. The tray was lubricated and reinserted in the patient's mouth. Then, the right half tray was loaded with alginate and placed into the patient's mouth. The alginate material was molded around the handle of the left half tray to form a positive interlock or keyway with the right half tray handle. After the material had set, the right half tray was removed first; the left half tray was then removed. Both half trays were rejoined extraorally with the alginate key and stabilized with masking tape wrapped around both handles. The cast was made in improved dental stone (Microstone, Whip Mix).

A sectional impression of the maxillary arch was taken with alginate impression material, and a cast was poured in dental stone (Fig 2).

A trisegmented custom impression tray was fabricated on the mandibular preliminary cast (Fig 3).

Using autopolymerizing resin, the first section of the impression tray covered the left side of the jaw and had two vertical mounting pins placed buccally and lingually along its crest at the midline. After polymerization, a lubricant was applied, and a keyway was developed in the midline. Then, the right half of the impression tray was molded, fit into the keyway, and processed. For the third section of the tray (the stabilizer), a lubricant was applied in the midline area and an overlay stent was fabricated to join the right and left sections. This third part of

© 2010 BY QUINTESSENCE PUBLISHING CO, INC. PRINTING OF THIS DOCUMENT IS RESTRICTED TO PERSONAL USE ONLY.
NO PART OF THIS ARTICLE MAY BE REPRODUCED OR TRANSMITTED IN ANY FORM WITHOUT WRITTEN PERMISSION FROM THE PUBLISHER.



Fig 3 Final impressions—custom trisectioned impression trays.



Fig 4 Sectional trial bases and occlusal registration.

the sectional impression tray stabilized the right and left segments and confirmed a proper relationship between the halves.

For the custom impression-making process, the sectional trays were fitted in the patient's mouth and border molded separately with green stick compound. The stabilizer confirmed the correct position of the left and right sectional trays.

Regular-setting Blu/White-Mousse (Parkell) registration materials were used for final impressions due to the controlled flowability of this material. Each half tray was sequentially loaded, seated in the patient's mouth, and stabilized with the third part of the tray, the stabilizer. The left side was placed first. Lubricant was used to prevent the parts of the impression from adhering to each other. After removal from the patient's mouth, the impression was assembled, boxed, and poured in dental stone.

The trial bases were constructed in a manner similar to the custom tray. Occlusal wax rims were attached to each section, and the trial base parts were inserted and assembled in the patient's mouth to determine the vertical dimension of occlusion and the centric relation (Fig 4).

With a facebow and jaw-relation records, the study casts were mounted on a Hanau semiadjustable Arcon (183) articulator.

A trial denture setup was made. Jaw relations, esthetics, and phonetics were confirmed (Fig 5).

To accurately determine implant placement and avoid the mental foramen, gutta-percha points were placed on the wax trial denture in the area of the canines. A panoramic radiograph for a surgical/radiographic guide was then taken.

During surgery, the anterior crestal bone was flattened, and four 10-mm (regular diameter) BioHorizons implants were placed intraforaminally. This was performed as a two-stage procedure.

After 4 months, the four implants were uncovered. Osseointegration was confirmed with a reverse torque test measurement and radiographs, and healing abutments were placed.

Two weeks after the uncovering of the implants, an implant-level impression was made. The impression copings were seated on the implants and splinted with steel burs united with autopolymerizing resin (GC America) on the buccal and lingual sides to prevent transfer errors. A small

© 2010 BY QUINTESSENCE PUBLISHING CO, INC. PRINTING OF THIS DOCUMENT IS RESTRICTED TO PERSONAL USE ONLY.
NO PART OF THIS ARTICLE MAY BE REPRODUCED OR TRANSMITTED IN ANY FORM WITHOUT WRITTEN PERMISSION FROM THE PUBLISHER.



Fig 5 Wax trial denture ready for try-in in two pieces.



Fig 6 Master cast with casting of two sectional bars with distal extensions. The UCLA abutments were extended in length for ease of handling in the patient's abnormally small mouth opening.

anterior impression tray was fabricated to pick up only the splinted implant impression copings. Polyether impression material (Impregum Penta, 3M ESPE) was used for the pickup impression.

A master cast was made (Die Keen stone, Heraeus Kulzer). Nonengaging UCLA abutments were waxed with two Hader bars between the abutments in the positions of teeth 22 and 24 and 25 and 27 with 4-mm distal extensions of the Hader bar and casted in type III alloy.

The height of the UCLA abutments was increased 2 mm by adding wax to the abutments prior to casting (Fig 6) to allow better access to the screw holes and retain the tray for a secondary impression.

After casting, the bars were tried in the patient's mouth, and the fit was verified with radiographs and a screw test for passive fit. It was determined that there was adequate space for a denture setup.

An altered cast impression technique[9] was used in the mandible. Unilateral edentulous sectional impression trays were fabricated for the right and left sides of the mandible. An opening in the trays was left so the bar and abutments were exposed, so they could be connected intraorally with GC autopolymerizing resin to the trays. Each half tray was extended over the ridge distally to the implants to capture all anatomic structures necessary to support a complete denture. The trays, which were loaded with polyvinyl siloxane (PVS) impression material (Examix NDS, GC America), were border molded, separately inserted, and screwed into the implants. The fixed connection to the implants permitted a nonpressured impression of the posterior mandible. Functional movements were performed as the impression material was setting.

After the final custom impression was completed, the right and left impression trays were screwed onto the anterior mandibular analogue cast (Fig 7), and an altered cast was made from dental stone.

Right and left trial bases were made over the bar frame and screwed into the implants and a new CR record made. The mandibular cast was mounted on the articulator. A new wax trial denture to confirm

© 2010 BY QUINTESSENCE PUBLISHING CO, INC. PRINTING OF THIS DOCUMENT IS RESTRICTED TO PERSONAL USE ONLY.
NO PART OF THIS ARTICLE MAY BE REPRODUCED OR TRANSMITTED IN ANY FORM WITHOUT WRITTEN PERMISSION FROM THE PUBLISHER.

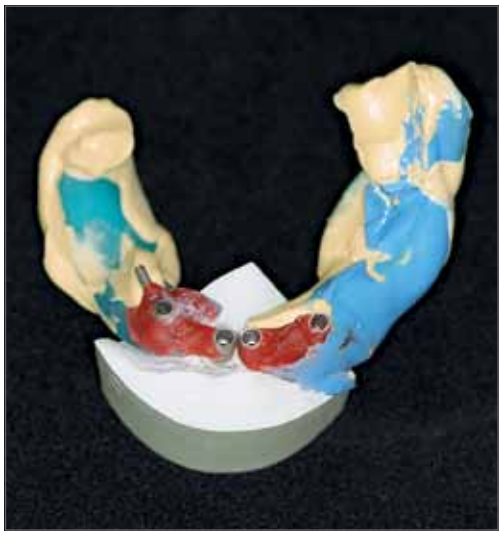

Fig 7 Altered cast technique. Final sectional impression supported by implant/bar structure.



Fig 8 For the implant superstructure fabrication, abutments were reduced to normal length.

Fig 9 Two-piece chrome cobalt framework with four Hader bar clips connected with acrylic ready for try-in.



function and esthetics was made, and a labial plaster index of the mandibular setup was fabricated.

The previously extended vertical height of the UCLA abutments was shortened to the height of the Hader bars (Fig 8). The mounted cast was sent to the laboratory for casting a two-piece, chrome cobalt mesh framework that was to fit over the bars with a VS3 Bredent interlock attachment (Bredent/XPdent) in the midline positioned more lingually to leave space for the denture teeth (Fig 9). The attachment was reduced in size and adapted within the limited space. Four Hader bar clips were connected to the framework with GC resin. The fit of the chrome cobalt framework was verified, the teeth were waxed to the framework using the labial plaster index, and the denture was processed (Fig 10).

In the area where the two denture sections met, a 2-mm sliding acrylic overlay was fabricated on the labial surface to prevent pinching of the patient's lip and food impaction. The lingual surface of the two-piece mandibular prosthesis has an

© 2010 BY QUINTESSENCE PUBLISHING CO, INC. PRINTING OF THIS DOCUMENT IS RESTRICTED TO PERSONAL USE ONLY.
NO PART OF THIS ARTICLE MAY BE REPRODUCED OR TRANSMITTED IN ANY FORM WITHOUT WRITTEN PERMISSION FROM THE PUBLISHER.



Fig 10 Denture in two pieces.

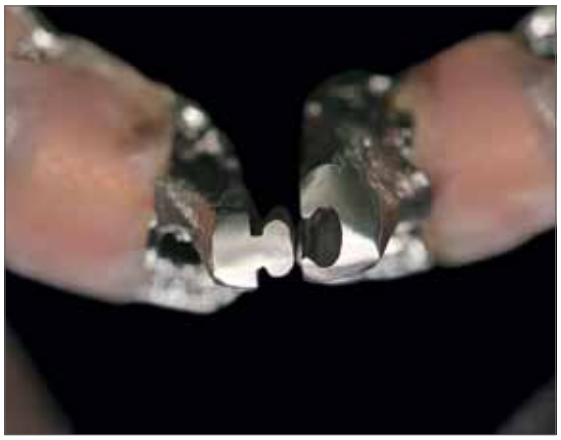

Fig 11 Modified VS3 Bredent attachment.



Fig 12 The framework and attachments in situ.



Fig 13 Final extraoral photograph.

open design to help prevent food impaction (Fig 11). After processing, a laboratory-remount was performed to remove processing errors, and the denture was recovered.

On the day of denture placement, the right and left implant-supported bars were screwed into the four implants and the two-piece bar overdenture was inserted into the patient's mouth (Figs 12 and 13). The border extensions and the occlusion were verified. The patient practiced inserting and removing the two-piece overdenture.

During follow-up visits, the patient reported extreme satisfaction and claimed that she could even chew nuts. The patient returned for several postinsertion examinations, and little or no adjustments were performed. The patient has been placed on a 6-month recall and been informed that the clip attachments will have to be replaced as necessary.

ACKNOWLEDGMENT

The authors wish to express their appreciation to BioHorizons; the Marotta Dental Studio; and the attending faculty of the New Jersey Dental School for their support, guidance, and innovative suggestions in attaining success in the treatment of this unusual and compromised clinical situation.

© 2010 BY QUINTESSENCE PUBLISHING CO, INC. PRINTING OF THIS DOCUMENT IS RESTRICTED TO PERSONAL USE ONLY.
NO PART OF THIS ARTICLE MAY BE REPRODUCED OR TRANSMITTED IN ANY FORM WITHOUT WRITTEN PERMISSION FROM THE PUBLISHER.

REFERENCES

1. National Center for Health Statistics. International Classification of Diseases, Ninth Revision, Clinical Modification (ICD-9-CM).
2. McCord JF, Moody GH, Blinkhorn AS. Overview of dental treatment of patients with microstomia. Quintessence Int 1990;21:903–906.
3. Luebke RJ. Sectional impression tray for patients with constricted oral opening. J Prosthet Dent 1984;52: 135–137.
4. Ohkubo C, Maeda Y, Sugiyama K, Suzuki Y, Ishikawa Y, Hosoi T. Impression techniques for patients with microstomia or constricted oral opening. Tsurumi Univ Dent J 2002;28:145–151.
5. Ohkubo C, Ohkubo C, Hosoi T. Development of sectional custom tray system. The Nippon Dental Review 2001;61:103–105.
6. Whitsitt JA, Battle LW. Technique for making flexible impression trays for the microstomic patient. J Prosthet Dent 1984;52:608–609.
7. Dougherty ME, Warden GD. A thirty-year review of oral appliances used to manage microstomia, 1972 to 2002. J Burn Care Rehabil 2003;24:418–431.
8. Naylor WP, Manor RC. Fabrication of a flexible prosthesis for the edentulous scleroderma patient with microstomia. J Prosthet Dent 1983;50:536–538.
9. Leupold RJ, Kratochvil FJ. An altered-cast procedure to improve tissue support for removable partial dentures. J Prosthet Dent 1965;15:672–678.

© 2010 BY QUINTESSENCE PUBLISHING CO, INC. PRINTING OF THIS DOCUMENT IS RESTRICTED TO PERSONAL USE ONLY.
NO PART OF THIS ARTICLE MAY BE REPRODUCED OR TRANSMITTED IN ANY FORM WITHOUT WRITTEN PERMISSION FROM THE PUBLISHER.