Histologic Evidence of Connective Tissue Integration on Laser Microgrooved Abutments in Humans

Nicolaas C. Geurs,* Philip J. Vassilopoulos,* Michael S. Reddy*

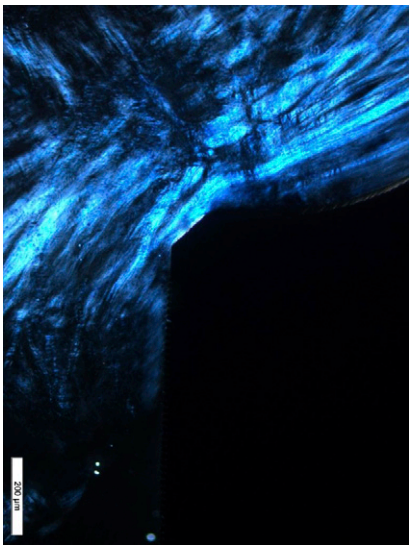



Introduction: Human histology and scanning electron microscopy (SEM) are presented, outlining the soft tissue integration to a laser microgrooved abutment surface.

Case Presentation: In two patients, prosthetic abutments with a laser microgrooved surface were placed on osseointegrated implants. After 6 weeks of healing, the abutments and the surrounding soft tissue were removed and prepared for histology and SEM. The most apical epithelium was found coronal to this surface. Connective tissue demonstrated collagen fibers oriented perpendicular to the microgrooved surface. There was intimate contact between the connective tissues and the microgrooved abutment surface.

Conclusion: The abutments in these patients had connective tissue integration with functionally oriented fibers to the microgrooved surface. *Clin Adv Periodontics* 2011;1:29-33.

Key Words: Connective tissue; dental implant; gingiva; histology.

Background

The success of dental implants is dependent on the establishment of a soft tissue barrier that is able to shelter underlying osseous structures and osseointegration surrounding the implant body. Mucosal attachment is created during the healing process after placement of the implant. The implant surface characteristics can influence apical migration of epithelium and organization of connective tissue attachment.[1,2] In a human histologic and scanning electron microscopy (SEM) evaluation of soft tissue surrounding two-piece implants with laser microgrooved channels† apical to the epithelium, fibers were found in close contact with the microgrooves and were oriented perpendicular to the implant surface, demonstrating more similarities to natural dentition.[2] A similar attachment was also observed to laser microgrooved abutments placed on implants in a canine model.[3] This case series presents the histology of mucosal integration to a laser microgrooved abutment in humans.

*Department of Periodontology, University of Alabama School of Dentistry, Birmingham, AL.

Submitted December 13, 2010; accepted for publication January 18, 2011

doi: 10.1902/cap.2011.100005

Clinical Presentation

Two patients presented to the periodontal research clinic at the University of Alabama School of Dentistry in 2009. They each received a 3.8 mm diameter internal tapered implant† in the maxillary premolar area. The implants were

†Laser-Lok, BioHorizons, Birmingham, AL.

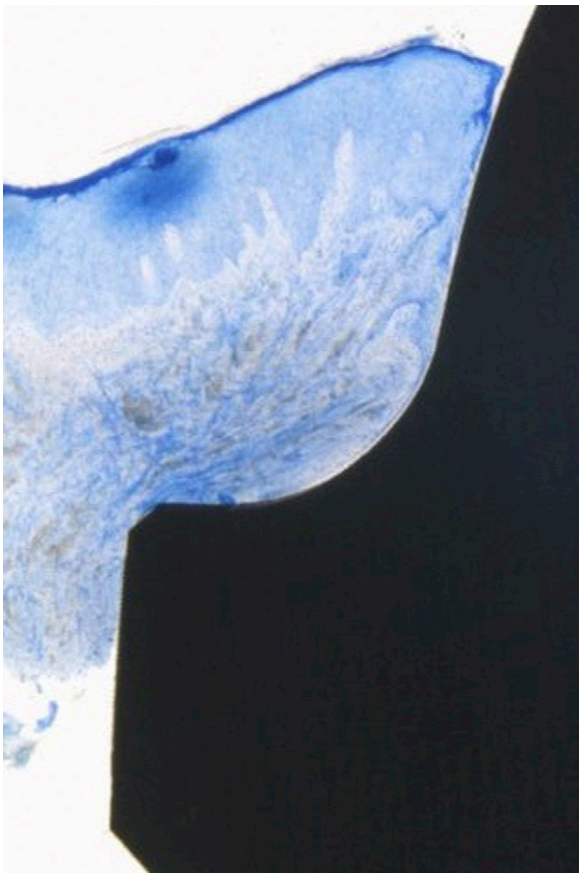

FIGURE 1 Ground section of specimen stained with toluidine blue/Azur II. The oral epithelium and junctional epithelium are tapering off coronal to the microgrooved surface.

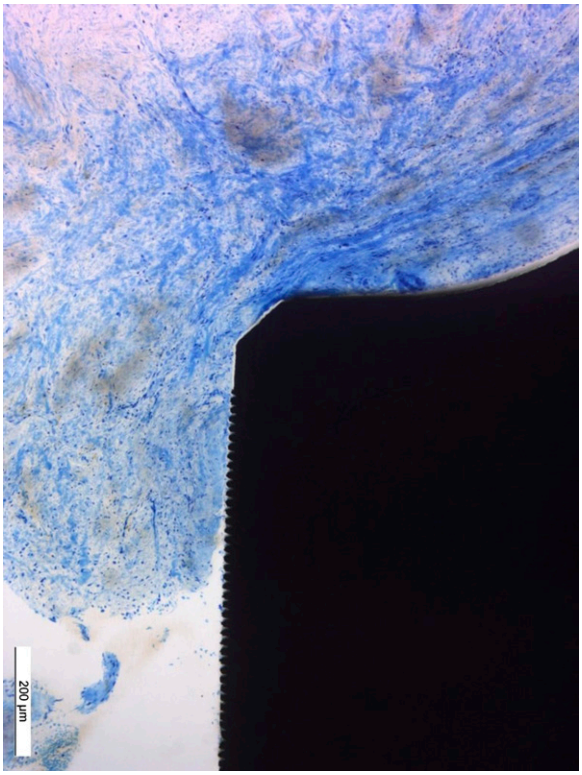

FIGURE 2 Higher magnification of Figure 1 showing connective tissue in close contact with the microgrooved surface of the abutment.

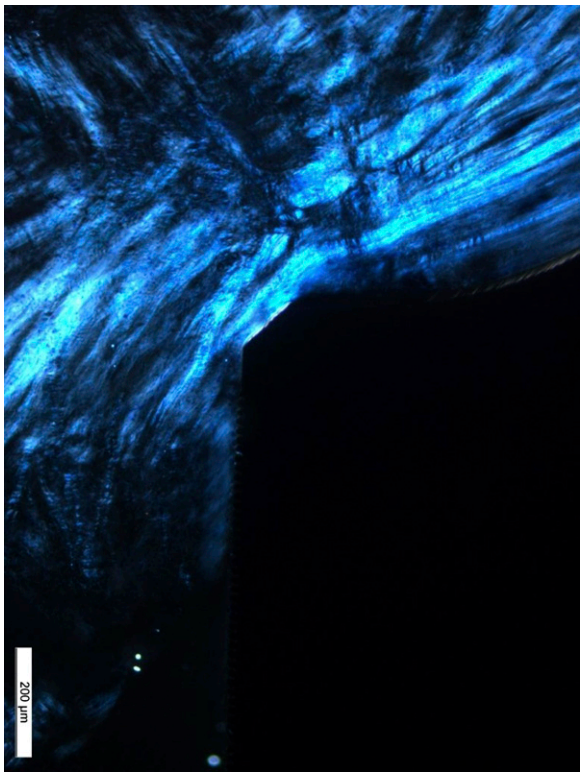

FIGURE 3 Polarized light view of Figure 2 demonstrating collagen fibers in a functional orientation toward the abutment surface.

allowed to heal covered by mucosa. After 6 months of healing, the implants were uncovered. A crestal incision was made, and full-thickness flaps were elevated to expose 3 mm surrounding the osseous structures around the implant. No bone loss was noted, and a special abutment with a 1 mm laser microgrooved zone around the abutment directly coronal to the implant was placed. The flaps were sutured around the abutments. The sutures were removed after 2 weeks. After 6 weeks of healing, a 5 mm diameter tissue punch was used over the abutments to free up a 1 mm mucosal collar. Care was taken to minimize trauma to the mucosal cuff surrounding the abutment. The mucosa and abutment were removed together, and the specimens were stored in 10% formalin solution. A 4.5 mm healing abutment was placed on the implant, and the patients proceeded with the prosthetic phase after 1 month of healing.

Case Management (specimen preparation)

Two specimens, one from each patient, were evaluated. One specimen was prepared for histologic evaluation. In preparation for light microscopy, the non-demineralized specimen was embedded in resin and polymerized. The blocks were sectioned in an axial direction, and the slices were reduced by microgrinding and polishing to a final thickness of 30 to 40 µm. The sections were stained with toluidine blue/Azure II. The other specimen was prepared for SEM by dehydration through a graded series of acetones and dried using carbon dioxide as a transitory fluid.

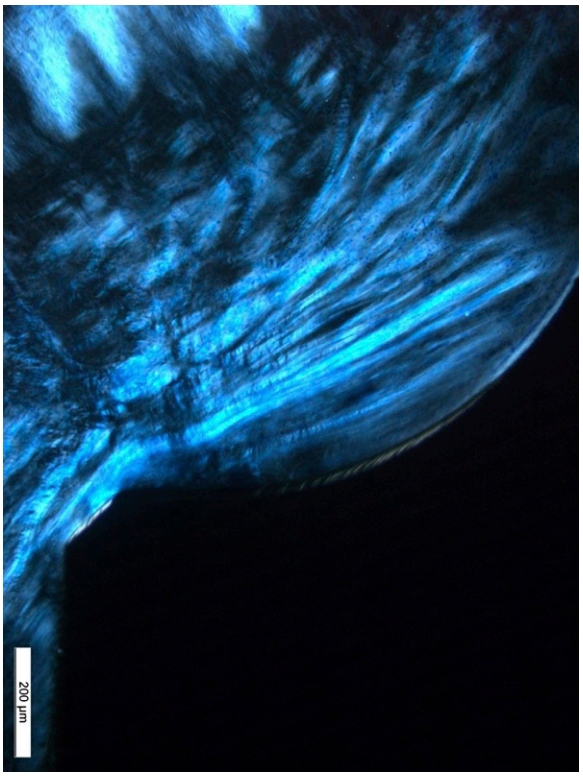

FIGURE 4 Polarized light view from an area coronal to Figure 3. The orientation of the collagen fibers is more parallel to the smooth implant surface.



FIGURE 5 SEM view showing collagen fibers integrated with the microgrooves on the abutment surface.

Clinical Outcomes (specimen analysis)

The histology on the first specimen revealed that the most apical part of the mucosa attached to the osseous tissue was not captured during the tissue harvesting and thus was missing from the histologic sections. Intimate contact of the junctional epithelial cells with the smooth abutment surface was observed with light microscopy (Fig. 1). The most apical epithelium was located on the coronal part of the microgrooved surface. The higher magnification view of the microgrooved area of the abutment showed that it was surrounded by connective tissue (Fig. 2). When viewed with polarized light, perpendicularly oriented collagen fibers running toward the grooves of the abutment surface were observed (Fig. 3). In the machined smooth areas of the abutment, the orientation was more parallel to the implant surface and did not appear to insert into the implant surface (Fig. 4).

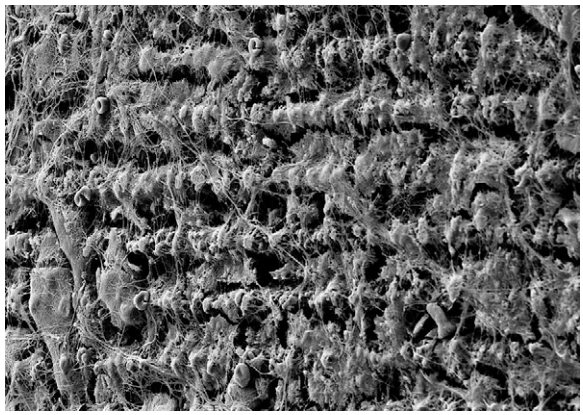

FIGURE 6 Higher magnification (×1.94) of Figure 5.

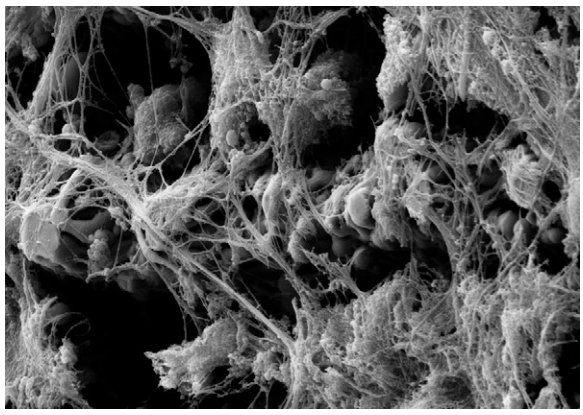

FIGURE 7 Highest magnification (×8.59) of the views. Note the intimate contact between the collagen fibers and the abutment surface.

SEM of the second specimen confirmed the presence of integrated collagen fibers in between and around the microgrooves (Figs. 5 through 7). On the highest magnification, the intimate contact between the collagen fibers and the laser ablated abutment surface can be appreciated.

Discussion

Peri-implant tissue health is essential for long-term stability of the implant. Mucosal integration to the implant or abutment could play an important role in preventing the detrimental effects of microbial and mechanical challenges. These challenges are aggravated by the location and size of the microgap and the micromobility.[4,5] The stability of this attachment may have the potential to better withstand these challenges, especially if the attachment could be established coronal to the microgap or on the abutment. This case series demonstrates the organization of the mucosa and connective tissue surrounding an abutment with a zone of laser ablated microgrooves on the surface. The most apical location of the epithelium was coronal to the microgrooved surface and at least 1 mm coronal to the implant–abutment

connection. Similar location of epithelial attachment has been reported on implants in humans[2] and around abutments in a dog study.[3] The orientation of the collagen fibers parallel to the implant surface has been reported previously.[6-8] The perpendicular orientation on the rough surface[9] and insertion into the microgrooved implant surface[2,3] have also been described previously. The stability of these functionally oriented fibers integrated to the implant surface was shown to be advantageous in the prevention of periimplant bone loss and maintenance of attachment levels.[10] The uniqueness of this report is that these events occurred around the abutment and coronal to the implant–abutment connection. In a canine model, the attachment and osseous healing surrounding the implant were more favorable around implants with a cervical microgrooved surface.[3] This might influence the establishment of a zone of "biologic width." The dimensions of the biologic width in a well-healed two-piece implant without additional challenges are stable.[11] Bone loss and inflammation have been reported in relation to the location of attachment around the microgap.[4,5,12,13] The establishment of mucosal integration coronal to the microgap may have the potential to prevent this bone loss and inflammation.[3] The increased attachment may also offer greater resistance to mechanical or inflammatory challenges and protect the osseous tissue around a dental implant. Further studies are needed to evaluate the significance of the attachment on an abutment on the stability of attachment and bone levels around implants. ■

Summary

Why is this case new information?	To our knowledge, this is the first human case series reported with human histology describing the connective tissue attachment around a microgrooved abutment.
What are the keys to successful management in this case?	The abutment surface characteristics can lead to connective tissue integration with the microgrooved surface, with functionally oriented collagen fibers.
What are the primary limitations to success in this case?	This is only a case series of the histology of the attachment. No clinical outcomes or advantages are reported. Further studies will need to be conducted to demonstrate the clinical advantages.

Acknowledgments

The authors thank Dr. P. Schupbach (Schupbach LTD Service Laboratory for histology and imaging) for providing histologic sections and SEM views. The authors have ongoing research funding from BioHorizons. Dr. Geurs has also received research funding from Biomet 3i (Palm Beach Gardens, FL) and Zimmer Dental (Carlsbad, CA), as well as lecture fees from BioHorizons. Dr. Reddy has received research funding and consulting fees from Biomet 3i, Nobel Biocare USA (Yorba Linda, CA), and Sunstar Americas (Chicago, IL), as well as consulting fees from BioHorizons.

CORRESPONDENCE:
Dr. Nicolaas Geurs, University of Alabama School of Dentistry, SDB 412, 1919 7th Ave. South, Birmingham, AL 35294-0007. E-mail: ngeurs@uab.edu.

References

1. Ricci J, Charvet J, Frenkel S, et al. Bone response to laser microtextured surfaces. In: Davies JE, ed. *Bone Engineering*. Toronto: Em2 Inc.; 2000: 282-294.
2. Nevins M, Nevins ML, Camelo M, Boyesen JL, Kim DM. Human histologic evidence of a connective tissue attachment to a dental implant. *Int J Periodontics Restorative Dent* 2008;28:111-121.
3. Nevins M, Kim DM, Jun SH, Guze K, Schupbach P, Nevins ML. Histologic evidence of a connective tissue attachment to laser microgrooved abutments: A canine study. *Int J Periodontics Restorative Dent* 2010;30:245-255.
4. Hermann JS, Buser D, Schenk RK, Schoolfield JD, Cochran DL. Biologic width around one- and two-piece titanium implants. *Clin Oral Implants Res* 2001;12:559-571.
5. Hermann JS, Schoolfield JD, Schenk RK, Buser D, Cochran DL. Influence of the size of the microgap on crestal bone changes around titanium implants. A histometric evaluation of unloaded non-submerged implants in the canine mandible. *J Periodontol* 2001;72:1372-1383.
6. Berglundh T, Lindhe J, Ericsson I, Marinello CP, Liljenberg B, Thomsen P. The soft tissue barrier at implants and teeth. *Clin Oral Implants Res* 1991;2:81-90.
7. Listgarten MA. Soft and hard tissue response to endosseous dental implants. *Anat Rec* 1996;245:410-425.
8. Tetè S, Mastrangelo F, Bianchi A, Zizzari V, Scarano A. Collagen fiber orientation around machined titanium and zirconia dental implant necks: An animal study. *Int J Oral Maxillofac Implants* 2009;24:52-58.
9. Schwarz F, Ferrari D, Herten M, et al. Effects of surface hydrophilicity and microtopography on early stages of soft and hard tissue integration at non-submerged titanium implants: An immunohistochemical study in dogs. *J Periodontol* 2007;78:2171-2184.
10. Pecora GE, Ceccarelli R, Bonelli M, Alexander H, Ricci JL. Clinical evaluation of laser microtexturing for soft tissue and bone attachment to dental implants. *Implant Dent* 2009;18:57-66.
11. Abrahamsson I, Berglundh T, Moon IS, Lindhe J. Peri-implant tissues at submerged and non-submerged titanium implants. *J Clin Periodontol* 1999;26:600-607.
12. Piattelli A, Vrespa G, Petrone G, Iezzi G, Annibali S, Scarano A. Role of the microgap between implant and abutment: A retrospective histologic evaluation in monkeys. *J Periodontol* 2003;74:346-352.
13. Todescan FF, Pustiglioni FE, Imbronito AV, Albrektsson T, Gioso M. Influence of the microgap in the peri-implant hard and soft tissues: A histomorphometric study in dogs. *Int J Oral Maxillofac Implants* 2002; 17:467-472.

○ indicates key references.