CLINICAL ORAL IMPLANTS RESEARCH

Soo-Yeon Shin
Dong-Hoo Han

Influence of a microgrooved collar design on soft and hard tissue healing of immediate implantation in fresh extraction sites in dogs

Authors' affiliations:
Soo-Yeon Shin, Department of Prosthodontics, College of Dentistry, Dankook University, Choongnam, South Korea
Dong-Hoo Han, Department of Prosthodontics, College of Dentistry, Yonsei University, Seodaemun, Seoul, South Korea

Corresponding author:
Dong-hoo Han
Department of Prosthodontics
College of Dentistry
Yonsei University
134 Shinchon, Seodaemun
Seoul 120-752
South Korea
Tel.: +82 2 2228 3163
Fax: +82 2 312 3598
e-mail: donghoohan@yumc.yonsei.ac.kr

Key words: bone remodeling, dental implant, immediate implant placement in fresh extraction socket, osseointegration, surface topography

Abstract

Objective: This study compared the alveolar bone reduction after immediate implantation using microgrooved and smooth collar implants in fresh extracted sockets.

Material and methods: Four mongrel dogs were used in this study. The full buccal and lingual mucoperiosteal flaps were elevated and the third and fourth premolars of the mandible were removed. The implants were installed in the fresh extracted sockets. The animals were sacrificed after a 3-month healing period. The mandibles were dissected and each implant site was removed and processed for a histological examination.

Results: During healing, the marginal gaps in both groups, which were present between the implant and the socket walls at implantation, disappeared as a result of bone filling and resorption of the bone crest. The buccal bone crests were located apical of its lingual counterparts. At the 12-week interval, the mean bone–implant contact in the microgrooved group was significantly higher than that of the turned surface group. From the observations in some of the microgrooved groups, we have found bone attachment to the 12 μm microgrooved surface and collagen fibers perpendicular to the long axis of the implants over the 8 μm microgrooved surface.

Conclusion: Within the limitations of this study, microgrooved implants may provide more favorable conditions for the attachment of hard and soft tissues and reduce the level of marginal bone resorption and soft tissue recession.

Osseointegration implies a direct and close incorporation into vital bone of threaded titanium fixtures with a defined finish and geometry (Brånemark et al. 1985; Albrektsson et al. 1994). Osseointegration can be achieved if the fixtures are inserted using a delicate surgical technique and are allowed to heal without load for periods not less than 3–4 months in lower and 5–6 months in upper jaws (Adeli et al. 1981). Recently, shorter healing periods were advocated, thus allowing shorter rehabilitation periods for the patient (Cochran et al. 2002). However, bone resorption of the residual ridges is a common occurrence after tooth extraction (Atwood 1962, 1963; Johnson 1963, 1969; Tallgren 1972). Many authors have reported marked dimensional alterations of the height and width of the alveolar ridge after the removal of teeth; furthermore, the healing process after tooth removal apparently results in more pronounced resorption on the buccal aspects than on the lingual aspects of the

Date:
Accepted 16 December 2009

To cite this article:
Shin S-Y., Han D-H. Influence of microgrooved collar design on soft and hard tissue healing of immediate implantation in fresh extraction sites in dogs. *Clin. Oral Impl. Res.* **21**, 2010; 804–814.
doi: 10.1111/j.1600-0501.2010.01917.x

© 2010 John Wiley & Sons A/S

ridge (Pietrokovski & Massler 1967; Botticelli et al. 2004a; Araújo & Lindhe 2005; Araújo et al. 2005).

In order to prevent remodeling and maintain the original shape of the ridge, the installation of implants in the extraction sockets was advocated as a way of reducing the number of surgical procedures, preserving the dimensions of the alveolar ridge, and decreasing the interval between tooth extraction and insertion of the implant restoration. Lazzara (1989) suggested that immediate placement appears to be a valid technique for preserving the bone at the site of implantation as well as for avoiding the possibility of esthetic and/or functional compromise in the implant-supported prosthesis. Paolantonio et al. (2001) reported that implant placement in a fresh extraction socket can counteract this process of tissue modeling and preserve the dimensions of the alveolar ridge. It was reported that when a screw-type dental implant was placed into a fresh extraction socket that is characterized by favorable anatomic conditions, the clinical outcome and degree of osseointegration do not differ from implants placed in healed, mature bone. Based on the results of a 1-year prospective study, Kan et al. (2003) reported that immediate placement and provisionalization of anterior single implants can effectively optimize the peri-implant esthetics by maintaining the existing hard and soft tissue architecture of the replaced tooth and minimize the emotional trauma of losing a maxillary anterior tooth and eliminates the need for a removable provisional restoration.

On the other hand, delayed implants have been proposed to achieve better flap management over barrier membranes. According to such protocols, implants are placed 3–4 or 8–12 weeks after extraction in order to allow complete healing of the soft tissues. However, Covani et al. (2004) suggested that the marked reduction of the buccal–lingual width of the bone ridge might begin immediately after tooth extraction and continue, non-uniformly, even after delayed implant placement and independently of the timing of implant placement. In addition, it has been suggested that the placement of an implant in a fresh extraction site in dogs failed to prevent the remodeling that occurs in the socket walls (Araújo et al. 2005, 2006a, 2006b). Botticelli et al. (2004a) monitored the hard tissue alterations that occurred after implant placement in fresh extraction sockets in humans. They measured the distance between the implant and the inner and outer surfaces of the buccal and lingual bone walls at implant installation and at re-entry after 4 months. During healing, the bone walls underwent significant horizontal resorption. At the 4-month re-entry, there was complete resolution of the large marginal defect that had been present at the time of implant installation. Moreover, although the width of the bone walls was substantially reduced, the rough surface of the implant was covered almost consistently with bone, a thin layer.

Overall, the observations made in these studies indicate that implant placement in a fresh extraction socket may result in an early hard tissue filling of the marginal defect. However, this newly formed marginal bone may be partially lost in the later phase of tissue modeling after tooth extraction.

The aim of this study was to determine whether immediate implantation in fresh extraction sockets influences the modeling of the alveolar ridge that occurs after tooth extraction.

Material and methods

The study protocol was approved by the Ethics Committee for Animal Research at Yonsei University, South Korea.

Four mongrel dogs, approximately 1 year old and weighing about 30 kg each, were used in this study. During the surgical procedure, the animals were initiated with intravenously administered ketamine 10 mg/kg and anesthetized with intravenously administered 1% propofol 6 mg/kg.

The third and fourth premolars in both quadrants of the mandible ($_3P_3$ and $_4P_4$) were used as the experimental teeth. Sulcus incisions were placed along the buccal and lingual aspects of the premolars and full-thickness flaps were elevated in order to disclose the buccal and lingual hard tissue wall of the ridge. The experimental teeth were removed carefully with forceps.

Two types of 16 implants were used in this study: (i) turned surface groups (Silhouette, Biolok Int. Inc., Deerfield Beach, FL, USA) and (ii) microgrooved groups (Silhouette Laser-Lok, Biolok Int. Inc., Deerfield Beach, FL, USA) (Fig. 1). Both types of implants have the same design and the same surfaces treated with resorbable blast media, with the exception that Silhouette Laser-Lok has a dual bio-affinity collar with an implant neck consisting of two types of microgroove. The implant neck is comprised of a 0.5 mm turned surface, a 0.7 mm microgroove with an 8 μm pitch, and a 0.8 mm microgroove with a 12 μm pitch.

Eight implants per group implants, 3.45 mm wide and 10 mm long, were installed in the fresh extraction mesial sockets. The recipient sites were prepared for implant installation according to the manufacturer's guidelines. The implants were

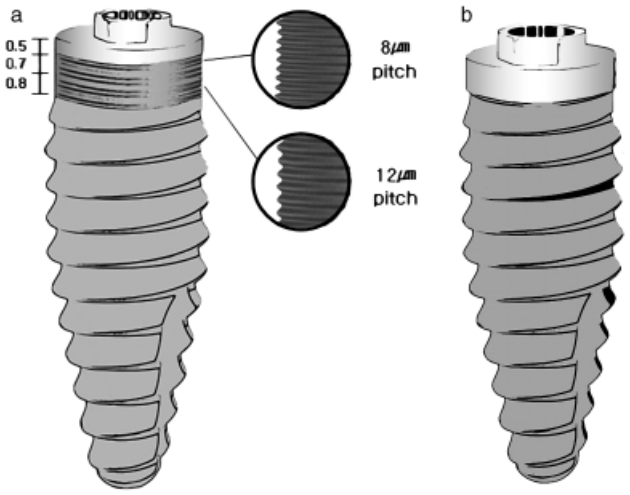

Fig. 1. Two different types of implant collar design. (a) Silhouette Laser-Lok, microgrooved implant group; (b) Silhouette, turned surface implant group.

© 2010 John Wiley & Sons A/S

placed so that the marginal level of the microgrooved surface was flush with or slightly apical of the lingual bone crest close to the lingual bone wall (Fig. 2). Healing caps (Silhouette Laser-Lok, Biolok Int. Inc.) were adjusted to the implants. The mobilized buccal and lingual flaps were replaced in order to allow semi-submerged healing of the implant sites. The wound margins were stabilized with interrupted sutures without bone grafts or a membrane. During the first week after surgery, the animals received amoxicillin (500 mg, twice daily) via a systemic route. Throughout the experiment, the animals were fed a pellet diet and placed on a plaque control regimen, which included teeth cleaning three times per week.

Alizarin red S, oxytetracycline hydrochloride, and calcein 20 mg/kg were administered intravenously for fluorescent observation of new bone formation 1, 6, and 11 weeks after implant installation.

After 3 months of healing, the dogs were sacrificed with an overdose of ketamine. The mandibles were dissected and placed in the fixative. Each implant was sectioned using a diamond saw (Exact® Apparatebeau, Norderstedt, Hamburg, Germany). The biopsies were processed for ground sectioning. The samples were dehydrated in increasing grades of ethanol and infiltrated with Technovit 7200 VLS-resin (Kulzer, Friedrichrsdorf, Germany). Following embedding in acrylic resin, the biopsy samples were polymerized and sectioned in a buccal–lingual plane using a cutting–grinding unit (Exact® Apparatebeau).

From each implant, one buccal–lingual section representing the central area of the site was prepared. By microgrinding and polishing, the sections were reduced to a thickness of approximately 60 μm and stained in hematoxylin and eosin.

The histological examination was performed using an optical microscope. The bone-to-implant contact percentage (BIC%) in the coronal three threads of the implant [mean ± standard deviation (SD)] was calculated. BIC% is the percentage of the length of the implant surface in contact with bone to the entire length of the implant surface in the limited zone.

In the sections, the following landmarks were identified (Fig. 3):

aBE: apical termination of the barrier epithelium;
B/I: marginal level of BIC;
C: marginal level of the bone crest;
PM: margin of the peri implant mucosa; and
M: marginal level of the microgrooved surface or the machined surface of implant.

Linear measurements (magnification × 15.5) were performed to determine the distance between the landmarks. Histological observations were made under a fluorescent microscope with a wavelength of 480 nm.

The mean values and SDs among animals were calculated for each variable. The data were analyzed using Wilcoxon signed rank test and repeated measures one-way analysis of variance (ANOVA) (SPSS software version 11, SPSS Inc., Chicago, IL, USA). A P-value <0.05 was considered significant.



Fig. 2. Photograph illustrating the position of the implants placed.

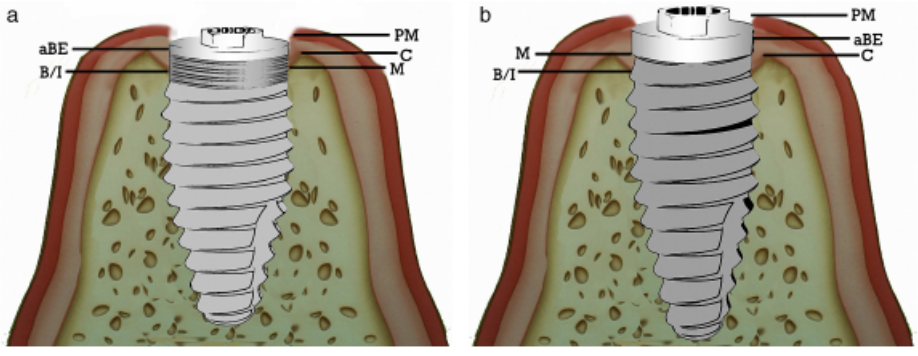

Fig. 3. Schematic drawing describing the different landmarks between which histometric measurements were performed. (a) Microgrooved implant group; (b) turned surface implant group. aBE, apical termination of the barrier epithelium; B/I, marginal level of bone-to-implant contact; C, marginal level of the bone crest; PM, margin of the peri implant mucosa; M, marginal level of the microgrooved surface or machined surface of implant.

Results

Clinical observations

All experimental sites healed eventually. There were no obvious signs of soft-tissue inflammation (swelling and redness) observed during healing. At 3 months, the mucosa adjacent to most implants and teeth, as well as the soft tissue covering the edentulous ridge appeared to be clinically healthy.

All implants showed proper osseointegration, as assessed by clinical means. Two of the 16 implants healing caps were lost (Fig. 4).

Microscopic observations

No residual defect was observed at the buccal and lingual aspect of the implant after healing. The tissue within the wide marginal gap consisted of fibrous

© 2010 John Wiley & Sons A/S



Fig. 4. Photograph illustrating the implant sites at sacrifice after 12 weeks of healing.

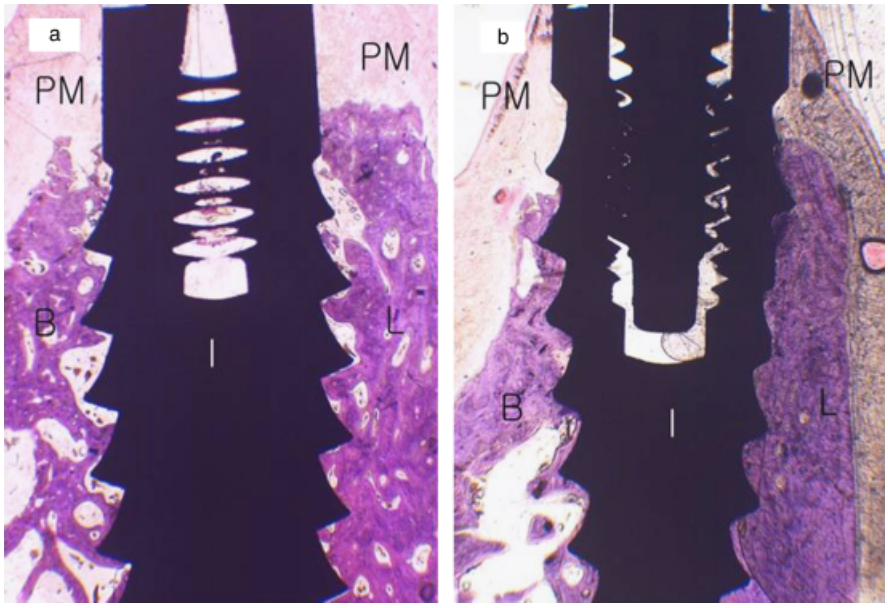

Fig. 5. Micrographs showing longitudinal section of microgrooved groups (a) and turned surface groups (b) after 12 weeks of healing. B, buccal wall; L, lingual wall; I, implant; PM, peri-implant mucosa. H-E staining; original magnification × 10.

tissue and newly formed bone. The histological examination revealed the buccal bone wall of the socket to be thinner and more apical than the lingual wall. The zone of connective tissue attachment was considerably longer at the buccal aspect than at the lingual aspect of the implant. The crest of the lingual bone wall was located close to the marginal level of the microgrooved surface or the machined surface of implant, while the buccal crest had a more apical location (Fig. 5).

In the microgrooved group at both the buccal and the lingual aspects, the connective tissue was attached to the 0.7 mm 8 μm pitch microgroove and the hard tissue was attached to the 0.8 mm 12 μm pitch microgroove. At the lingual bone wall, newly formed bone was observed in direct contact with the 12 μm microgroove. In addition, the lingual crest showed surface irregularities, while the outer surface was smooth. Compared with the lingual aspect, there was less buccal bone attached to the 12 μm microgroove. In addition, the buccal crest region and the outer wall showed an irregular surface (Fig. 6) and the presence of osteoclasts (Fig. 7). The hollowed appearance of Howship's lacunae of osteoclasts was observed on the bone crest and the outer border of the buccal bone wall.

BIC

At the 12-week interval, the mean BIC of the microgrooved implant or the turned surface implant at the lingual aspect was higher than that at the buccal aspect, but the difference was not significant.

The mean BIC in the microgrooved group was significantly higher than that of the turned surface group ($P = 0.031$). On the buccal bone walls, the mean BIC of the microgrooved and the turned surface group was 60.9 ± 10% and 38.7 ± 28.4%, respectively. On the lingual bone walls, the mean BIC of the microgrooved and the turned surface group was 63.6 ± 20.3% and 42 ± 34.7%, respectively (Table 1).

Histometric measurements

The buccal bone crest from the marginal level of the microgrooved or the turned surface of the implant was located more apical to that of the lingual bone crest. In the microgrooved group, the crest of the buccal bone wall was in a significantly more apical location ($P = 0.028$). There were no significant differences in both buccal and lingual aspects between the two groups. In the buccal aspect, the marginal level of bone-to-implant contact (B/I) from the marginal level of the microgrooved or the turned surface of the implant (M) was located more apical than that in the lingual aspect, but the difference was not significant (Table 2).

In the buccal aspect, the margin of the peri implant mucosa (PM) from the marginal level of the microgrooved or the turned surface of the implant (M) was located more coronal than in the lingual aspect, but this was not significant. In the buccal aspect of the microgrooved group, the margin of the peri implant mucosa (PM) from the marginal level of bone-to-implant contact (B/I) was located more coronal than in the lingual aspect, but this was not significant. In the turned surface groups, the margin of the buccal peri implant mucosa had a significantly more coronal location ($P = 0.042$). There were no significant differences between the two groups in both buccal and lingual aspects. The apical termination of the barrier epithelium (aBE) from the margin of the peri implant mucosa (PM) in the buccal aspect was located more apical than that in the lingual aspect, but this was not significant (Table 3).

Fluorescent observations

Alizarin red S, oxytetracycline hydrochloride, and calcein were administered 1, 6, and

© 2010 John Wiley & Sons A/S

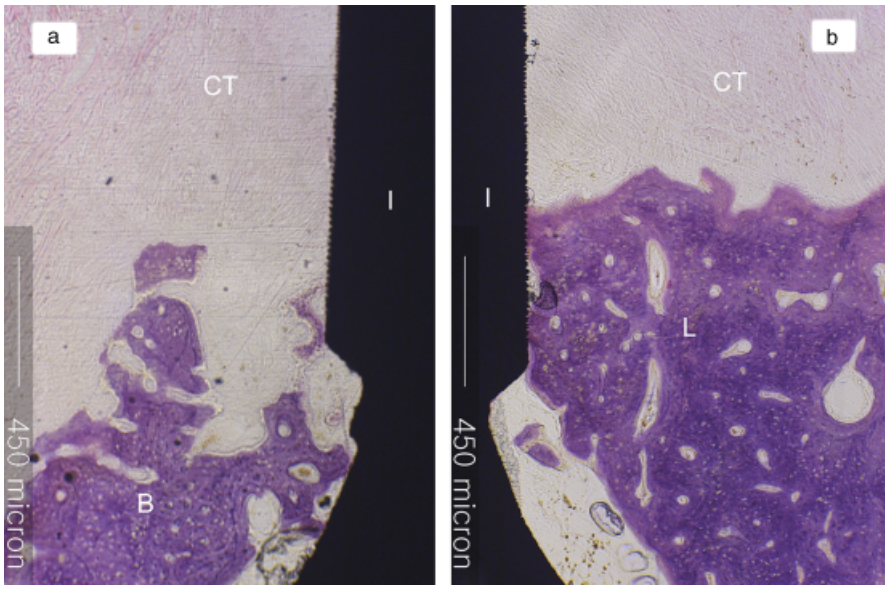

Fig. 6. Micrographs showing longitudinal section of microgrooved group after 12 weeks of healing. The crestal region of the buccal (a) and lingual (b) walls. B, buccal bone; L, lingual bone; CT, connective tissue; I, implant. H-E staining; original magnification × 40.

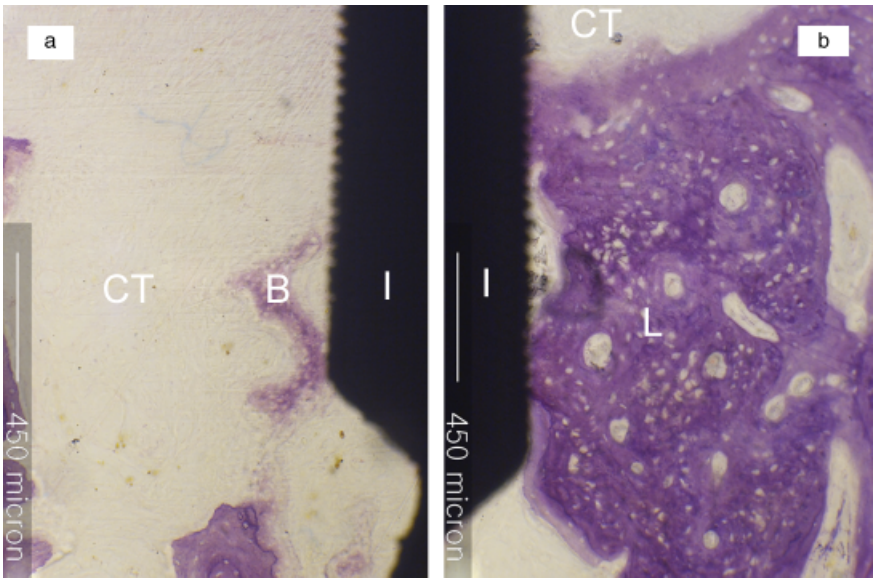

Fig. 7. Micrographs showing longitudinal section of microgrooved group after 12 weeks of healing. The crestal region of the buccal (a) and lingual (b) walls. The surface of the buccal bone crest exhibits signs of ongoing remodeling. B, buccal bone; L, lingual bone; CT, connective tissue; I, implant. H-E staining; original magnification × 100.

Table 1. **Bone-to-implant contact percentage (BIC%) in the coronal three threads of the implant (mean ± SD)**

	Bone-to-implant contact	
	Buccal	Lingual
Microgrooved	60.9 ± 10	63.6 ± 20.3
Turned surface	38.7 ± 28.4	42 ± 34.7

11 weeks after implant placement and these stains were red, yellow, and green under the fluorescent microscope, respectively.

In the outer surfaces of the buccal and lingual bone walls, there were small and regular osteons, suggesting an ongoing remodeling process, while irregular and incomplete osteons were observed in the proximity of the implant surface.

There were definite differences in new bone formation, bone resorption, and bone remodeling between the buccal and the lingual bone walls, particularly around the neck of the implants. The lingual bone walls around the implant neck remained comparatively unchanged and some parts of the osteon circles were lost only in the crestal region of the bone walls. On the other hand, in the buccal aspect of the implant neck, osteon resorption was observed in the crest and the outer border of the bone walls.

The observation of only red and yellow fluorescent lines around the buccal implant neck suggests that bone resorption had occurred from the outer surface of the old bone after the gap between the implant surface and the alveolar ridge had been filled with new bone. As a result, the buccal aspect was thinner and more apical in the crestal region of the bone walls than in the lingual aspect (Figs 8 and 9).

It also showed that in the supracrestal region, there were variations in the attachment and orientation of the connective tissue along the surface texture of the implant. In the microgrooved group, the collagen fibers ran parallel to the implant surface over the turned surface when they faced a machined surface but showed a perpendicular orientation to the implant over the 8 μm pitch microgrooved surface. In the turned surface group, the fibers were parallel to the fixtures (Fig. 10).

Regarding epithelial attachment, in the microgroove groups, epithelium migrated down to where the connective tissue was attached. However, in the turned surface group, epithelium grew downward to where the thread began passing over the turned surface (Fig. 11).

Discussion

Brånemark's original protocol recommended complete healing of the alveolar bone before placing a dental implant after tooth extraction; this process requires 6–12 months. As recommended by Brånemark and colleagues, implants are placed in existing edentulous areas and it can take up to 1 year from the time of placement before restorative therapy can begin, allowing 6 months for postextraction healing and 3–6 months for integration. A less time-consuming protocol that can produce predictable results would be beneficial to both the patient and the clinician. This approach has been termed the ''immediate implant,'' and the clinical and radiographic success of

© 2010 John Wiley & Sons A/S

this technique using various approaches has been documented (Knox et al. 1991; Lang et al. 1994; Schwartz-Arad & Chaushu 1997; Wilson et al. 1998; Steenberghe et al. 2000; Nemcovsky et al. 2002). Lazzara (1989) reported that immediate placement appeared to be a valid technique for preserving the bone at the implantation site and allowed the bone available for osseointegration to be maximized as well as the development of the restoration supported by osseointegrated implants from a functional and esthetic standpoint. In addition, immediate implantation avoids the possibility of an esthetic and/or a functional compromise in the implant-supported prosthesis.

Paolantonio et al. (2001) showed that when implants are placed into a fresh extraction socket characterized by favorable anatomic conditions without the use of barrier membranes or other regenerative materials, the clinical outcome and degree of osseointegration do not differ from implants placed in healed, mature bone. Kan et al. (2003) suggested that favorable implant success rates, peri-implant tissue responses, and esthetic outcomes can be achieved with immediately placed and provisionalized maxillary anterior single implants.

However, Araújo & Lindhe (2005) and Araújo et al. (2005, 2006a, 2006b) reported that the placement of an implant in a fresh extraction site obviously failed to prevent the remodeling that occurs in the socket walls. The resulting height of the buccal and lingual walls at 3 months was similar in implants and edentulous sites and vertical bone loss was more pronounced at the buccal aspect of the ridge than at the lingual aspect. Botticelli et al. (2004a) reported that the bone walls of the extraction underwent a marked change during a 4-month healing period. The horizontal resorption of the buccal bone dimension was approximately 56%, and the corresponding resorption of the lingual/palatal bone was 30%.

These results are similar to those from the present study. The resulting height and width of the buccal and lingual walls at 3 months were reduced and the change in the vertical bone level was more pronounced at the buccal aspect of the ridge than at the lingual aspect. In particular, in the microgrooved group, there was a significant difference between the buccal and the lingual bone walls. But some differences were also found. In the present study, the buccal bone crest shifted less further in the apical direction and showed less vertical bone loss, compared with the previous studies in which smaller dogs were used. Indeed, their dogs had thinner buccal bone walls and were more susceptible to bone resorption than the ones we used.

The tooth is anchored to the jaws via the bundle bone into which the periodontal ligament fibers invest. After the extraction of a tooth, the bundle bone at the site will obviously lose its function and disappear. Araújo & Lindhe (2005) reported that in the 1-week specimens of the extraction socket, the crestal region of the buccal hard tissue wall was made up exclusively of bundle bone, while the corresponding region of the lingual bone consisted of a combination of bundle bone and lamellar bone. Bundle bone, inside the socket and crestal regions, was observed in the experimental sites at 1 and 2 weeks but was not present in specimens after 4–8 weeks of healing. Therefore, the resorption of the buccal/lingual walls of the extraction site occurred in two overlapping phases. During phase 1, the bundle bone that had lost its function after extracting the tooth was resorbed and replaced with woven bone. As the crest of the buccal bone wall was comprised solely of bundle bone, this modeling resulted in a substantial vertical reduction of the buccal crest. Phase 2 included the resorption that occurred from the outer surfaces of both bone walls. The reason for this additional bone loss is not completely understood. Hence, the early resorption of the bundle bone may partly explain the marked decrease in the height of the buccal wall observed.

In preparation for the removal of the teeth, a crevice incision was made and minute full-thickness flaps were elevated at both the buccal and the lingual aspects of the alveolar process. It is well known that such surgical trauma, which includes the separation of the periosteum and rupture of its connective tissue attachment at the bone surface, will induce an acute inflammatory response. This in turn will mediate the resorption of the surface layer of the alveolar bone in the exposed area (Wilderman 1963; Wood et al. 1972).

It was suggested that the blood vessels to the bone walls were severed after elevating the mucoperiosteal flap in conjunction with tooth extraction. The reduced blood supply may have caused the death of osteocytes and necrosis of the surrounding mineralized tissue of the bone walls. During phase 2 of healing, this necrotic bone may be eliminated gradually through surface resorption orchestrated by osteoclasts in the periosteum. Because the buccal bone plate was considerably thinner than the lingual plate, this ''horizontal resorption'' may also cause ''vertical reduction'' of the buccal wall (Araújo et al. 2005). However, other factors may be involved in bone resorption that takes place in phase 2 of modeling, because marked dimensional

Table 2. **Results of histometric measurements (mm) describing the distance between the various landmarks (mean ± SD)**

	M–C		M–B/I	
	Buccal	Lingual	Buccal	Lingual
Microgrooved	−0.21 ± 0.08	−0.13 ± 0.1	−0.25 ± 0.1	−0.22 ± 0.09
Turned surface	−0.21 ± 0.07	−0.16 ± 0.1	−0.33 ± 0.14	−0.28 ± 0.12

Table 3. **Results of histometric measurements (mm) of the peri-implant soft tissue component (mean ± SD)**

	PM–M		PM–B/I		PM–aBE	
	Buccal	Lingual	Buccal	Lingual	Buccal	Lingual
Microgrooved	0.18 ± 0.07	0.17 ± 0.16	0.46 ± 0.08	0.42 ± 0.22	0.22 ± 0.16	0.18 ± 0.2
Turned surface	0.20 ± 0.14	0.16 ± 0.15	0.52 ± 0.23	0.44 ± 0.22	0.19 ± 0.23	0.16 ± 0.2

© 2010 John Wiley & Sons A/S



Fig. 8. Fluorescent images showing longitudinal section of microgrooved group after 12 weeks of healing. Arrows indicate new bone formation 1 week after implant placement. Note that the bone crest is closer to the neck of the implant at the lingual than at the buccal aspect of the implant. B, buccal bone; L, lingual bone; I, implant. Original magnification × 50.

alterations of the extraction also occur after tooth removal without flap elevation. Such factors may include (1) adaptation to the continued lack of function at the extraction site and (2) tissue adjustment to meet ''genetically'' determined demands regarding the ridge geometry in the absence of teeth (Araújo & Lindhe 2005).

Wood et al. (1972) reported that teeth with the thinnest radicular bone consistently demonstrated the most bone loss postoperatively, which occurred after both the full-thickness and the partial-thickness flaps. However, the relative thinness of the gingival and the alveolar mucosa in these areas makes the partial-thickness flap procedure extremely difficult. If the flap is reflected with sufficient connective tissue to maintain the integrity of the epithelium, the connective tissue that remains over the radicular alveolar bone is so thin that it offers little protection to the bone. In this experiment, because the width of the 3rd premolar socket was smaller than that of the 4th, more bone had to be removed in order to prepare the placement of implant, and a thinner alveolar ridge remained in the 3rd premolar sites. Nevertheless, considering that there was no significant difference in the vertical reduction between the two sites, factors other than the remaining bone thickness must play a role.

After tooth extraction, a socket often presents dimensions that may be considerably greater than the diameter of a conventional implant. Therefore, after implant installation, similar to the present experiment, a gap may occur in the marginal part of the recipient site. Botticelli et al. (2003a, 2003b) reported that a marginal defect >1 mm healed with new bone and a high degree of osseointegration to an implant designed with a SLA surface. Wilson et al. (1998) showed that osseointegration was successful in the immediate implant placement sites with horizontal defect dimensions >4 mm in humans when an SLA titanium implant was completely covered with connective tissue membranes. In addition, many authors reported that bone formation was similar in cases with or without a membrane (Cochran & Douglas 1993; Lang et al. 1994; Hämmerle et al. 1998; Covani et al. 2003). Akimoto et al. (1999) reported that a simulated extraction socket defect healed clinically with complete bone filling, regardless of the initial gap size. However, the width of the gap at the time of implant placement had a significant impact on the histological percentage. Moreover, the height of BIC and the clinical bone fill may not indicate true histological integration of the bone to implant. Botticelli et al. (2006) demonstrated that the process of bone modeling and remodeling at an implant placed in a fresh extraction socket differs from the resolution of a marginal defect (Akimoto et al. 1999; Botticelli et al. 2003a, 2003b, 2004b; Schropp et al. 2003) that can occur after implant installation in a healed ridge (Botticelli et al. 2004a; Araújo et al. 2005).

In general, wound healing around an implant can be influenced by the following four material-related factors: (i) physiochemical properties of the implant material, (ii) mechanical properties of the implant, (iii) surface topography of the material, i.e., the macrotopography and microtopography, and (iv) the overall shape and design of the implant (Walboomers & Jansen 2001). The material surface topography can be divided into roughness and texture. Roughness denotes non-standardized discontinuities, and texture denotes a standardized and controlled pattern.

Botticelli et al. (2005) reported that the marginal defects around rough surface implants showed substantial bone filling and a high degree of osseointegration, while healing at turned implants was characterized

© 2010 John Wiley & Sons A/S

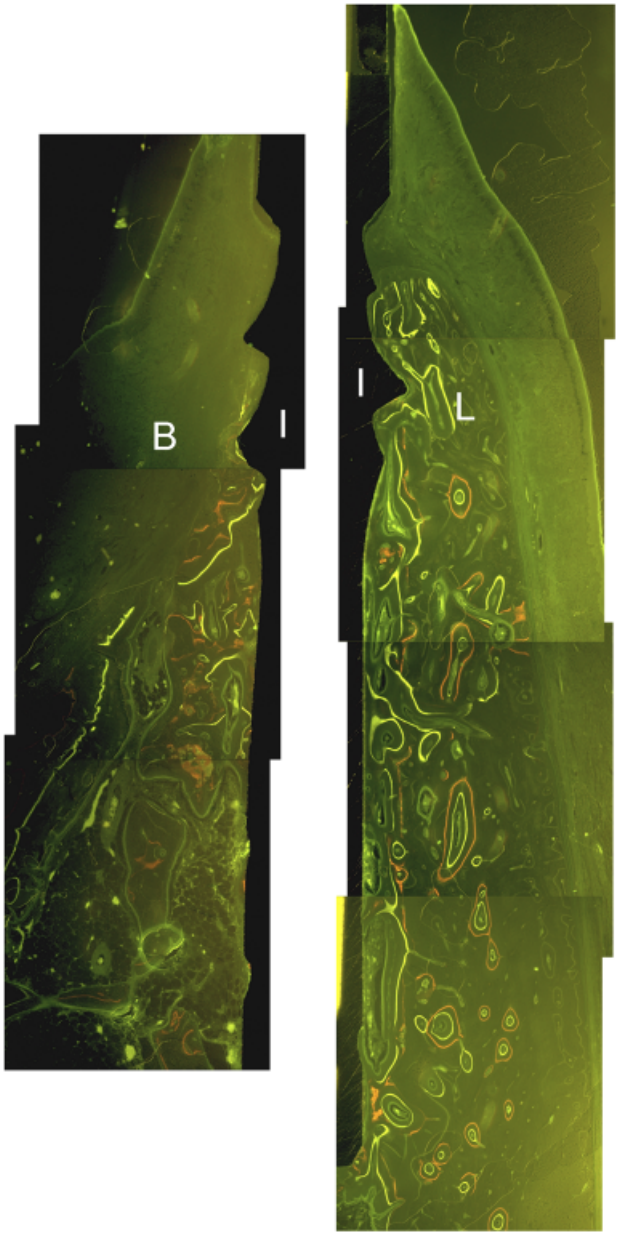

Fig. 9. Fluorescent images showing longitudinal section of turned surface group after 12 weeks of healing. Note that the bone crest is closer to the neck of the implant at the lingual than at the buccal aspect of the implant. B, buccal bone; L, lingual bone; I, implant. Original magnification × 50.

by incomplete bone filling and the presence of a connective tissue zone between the implant and newly formed bone. Osseointegration at the implant placed in sites with marginal defects is influenced by the surface characteristics of the implant. In addition, it was suggested that a rough implant surface in contrast to a smooth surface may stimulate osteoblast attachment and proliferation. Berglundh et al. (2003) reported that healing showed similar characteristics with the resorptive and appositional events for both SLA and turned surfaces. However, the rate and degree of osseointegration were superior for the SLA compared with the turned surfaces. Davies (1998) suggested that a rough implant surface provides optimal conditions for healing by promoting coagulum stability and the maintenance of contact between the metal surface and the blood clot during the initial healing stage. Furthermore, it was suggested that a rough implant surface, in contrast to a smooth surface, may stimulate osteoblast attachment and proliferation. Kim et al. (2006) evaluated the connective tissue attachment to titanium implants with various well-defined surface topographies and reported that the roughest surface displayed significantly thinner fibrous capsules, greater connective tissue attachment, and the least tissue–implant separation. An exception to this general rule was an acid-etched surface. The etched surface, despite its low roughness value, promoted connective tissue integration comparable to that of a much rougher surface. It is possible that the unique geometry created by the etching procedure can play a role in promoting connective tissue integration.

The possibility of influencing the behavior of cells by the topographical morphology of the surface onto which these cells are cultured was discovered during the first half of the twentieth century, and the changes in cell behavior were termed as ''contact guidance.'' No further attention was paid to this guidance phenomenon until the early 1970s, where it was rediscovered that the behavior of cells is affected by the topography of the substratum surface (Rovensky et al. 1971; Maroudas 1972). In other words, ''contact guidance'' is the response of cells to microgrooved surfaces. This suggests that, while the response is cell type dependent, the cell elongates in the direction of the groove and its travel is guided by the grooves.

Epithelium plays an important role in implant function by sealing the percutaneous and dental implants from contaminants in the external environment. However, the tendency of the epithelium to proliferate and migrate along an implanted device can create sinus tracts that may undermine the implant and lead to its loss. Aggressive epithelial downgrowth can be impeded by firm attachment between the soft connective tissue and the implant, with cells and fibers attached to the implant surface, as is the case with Sharpey's fibers around natural teeth. In healthy tissue, collagen bundles insert into the root cementum, and this connection deters the downgrowth migration of the overlying epithelium. Connective tissue does not usually attach to the titanium substrata in this manner. Instead, the connective tissue typically becomes organized into a fibrous capsule, with collagen fibers oriented parallel to the implant surface. The presence of this fibrous capsule often

© 2010 John Wiley & Sons A/S

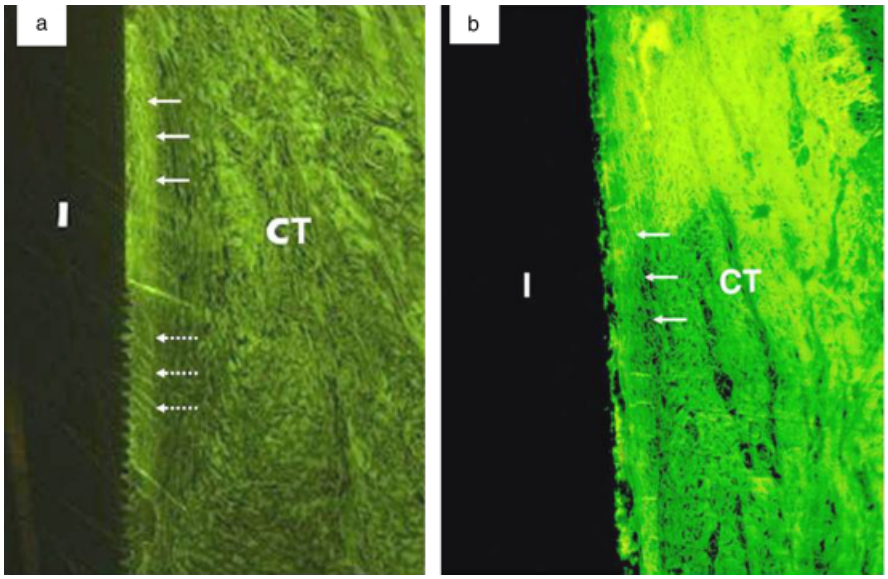

Fig. 10. Fluorescent images under polarizing microscope showing longitudinal section of microgrooved group (a) and turned surface group (b) after 12 weeks of healing. The solid arrows indicate the collagen fiber direction which are parallel to the implant surface over the turned surface and the dotted arrows point the collagen fibers perpendicular to the implant over the 8μm pitch microgrooved surface. CT, connective tissue; I, implant. Original magnification × 200.

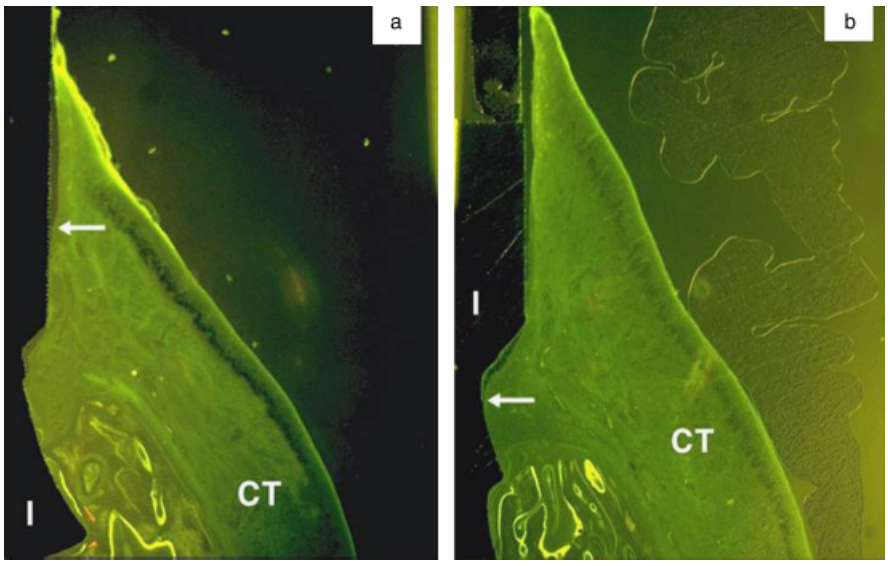

Fig. 11. Fluorescent images showing longitudinal section of microgrooved group (a) and turned surface group (b) after 12 weeks of healing. The arrows indicate the apical level of the junctional epithelium. CT, connective tissue; I, implant. Original magnification × 50.

indicates a failure of the implant to integrate with the soft tissues. In addition to compromising the local blood supply, thick fibrous capsules are associated with a persistent fluid space between the tissue and the implant, which precludes stable implant fixation (Kim et al. 2006). The mobility of the peri-implant mucosa is highly deleterious because when the tearing of connective tissue occurs with microbleeding, the protective role of the junctional epithelium induces apicalization of the latter. Therefore, a layer of connective tissue of 1 mm needs to reform more apically, which is often at the expense of the bone crest. In order to optimize the esthetic results, efforts must be made essentially in two directions: (i) to optimize the soft tissue seal or (ii) to prevent bone remodeling (Touati & Rompen 2005). Chehroudi et al. (1989, 1990) reported that micromachined surfaces with horizontally oriented grooves, 3 or 10 μm deep, inhibited epithelial downgrowth, possibly through a mechanism of contact guidance. Furthermore, it was demonstrated that the micromachined grooved surfaces of sufficient depth can produce obliquely oriented connective tissue ingrowth, and it was inferred that such a connective tissue/implant interface was responsible for the inhibition of epithelial downgrowth observed on that surface. However, in those studies, connective tissue and epithelium interacted with the same surface. Hence, the effect of the surfaces on each population could not be determined separately. In a successive study, an implant system was designed to allow connective tissue to contact the surfaces of various topographies, whereas epithelial cells only contacted the smooth flat surface (Chehroudi et al. 1992). This suggests the apical migration of the epithelium is inhibited by those micromachined surfaces that allow connective tissue ingrowth to the base component.

Matsuzaka et al. (2003) cultured osteoblast-like cells on the smooth and microgrooved substrates for periods up to 16 days and reported that the groove depth had no obvious effects. However, apparent differences were found in the attachment behavior between the various textures used. On the narrow grooves (< 2 μm), cells spread on the ridge only, whereas on the wider grooves (> 5 μm), the substrate surface was completely covered by the cells. This is in accordance with a study on fibroblasts (Walboomers et al. 1998). Such focal adhesion-mediated information is known to influence various bone cell processes such as adhesion, spreading, proliferation, migration, differentiation, matrix production, apoptosis, etc. Surprisingly, matrix deposition was enhanced, particularly on these smaller microgrooved surfaces. This leads to the following assumption: a smaller texture to the cells might give the appearance of an extracellular matrix (ECM) network. This leads to an altered shape of focal adhesions on the cell membrane. The signaling function of the integrins then accounts for the transfer of environmental clues into the cell, resulting in altered and enhanced matrix production. Transmission electron microscopy showed that the cell layer closest to the substrate surface exhibited more endoplasmatic reticulum than the superficial cell layers. The

© 2010 John Wiley & Sons A/S

dominant presence of endoplasmic reticulum is associated before with a high level of protein synthesis. This is an additional indication of the relationship between the surface modifications, such as microtexturing, and the cellular behavior, i.e. ECM production of the adherent cells. On the other hand, the cells on a smooth substrate form a monolayer that has very little support from the surrounding ECM. This has a negative effect on the proliferation and differentiation characteristics of these cells. Therefore, microgrooves can influence bone-cell behavior in a variety of ways, i.e. by (i) determining the alignment of cells and cellular extensions, (ii) altering the formation and placement of cell focal adhesions, and (iii) altering ECM production. Hence, the texturing of a substrate surface might be an important tool for establishing a three-dimensional environment for bone cells.

The results from this study on the attachment of soft and hard tissues to a microgrooved surface of implants are similar to those from the previous study. The data show that in the supracrestal region, the attachment and orientation of connective tissue varied along the surface texture of the implant. In the microgrooved group, the collagen fibers ran parallel to the implant surface over the machined surface, while they showed a perpendicular orientation to the implant over the 8 μm pitch microgrooved surface. In the turned surface group, the fibers were parallel to the fixtures.

The BIC of the microgrooved group was significantly higher than that of the turned surface group. This concurs with fluorescent microscopy observations in that new bone formation in the area of buccal and lingual bone crest, which is indicated by the light yellow and green images, suggests that later bone remodeling and further bone formation can be expected.

While the connective tissue fibers run parallel to the surface of the implant in the turned surface group, they showed an oblique, almost perpendicular orientation on the surface of the implant of the microgrooved group. This orientation of the connective tissue bundle is similar to that observed in natural teeth and can be expected to prevent epithelial downgrowth and saucerization of the soft tissue around implants.

There were no significant differences between the buccal and the lingual aspect of bone walls. There was no inflammatory tissue or connective tissue interposition between the implant and hard tissue. This can be explained by the bone formation from the inside of the bone defect. In a review paper, Davies (1998) described ''mechanisms of endosseous integration'' and suggested that there are two different phenomena by which the bone can become juxtaposed to an implant surface, namely (i) distance osteogenesis, in which new bone reaches the implant surface through appositional growth from the existing peri-implant bone, and (ii) contact osteogenesis or osteoconduction, in which *de novo* bone formation occurs directly on the implant surface. It was further suggested that an implant with a roughened surface, as opposed to an implant with a smooth surface, may promote osteoconduction by both increasing the available surface area for fibrin attachment and providing surface features to which fibrin could become entangled. However, with respect to the histomorphometric measurements, the buccal bone crest was located more apical than the lingual bone crest and fluorescent microscopy indicated an irregular bone surface on the buccal bone crest. This suggests bone resorption of the marginal bone and failure in preventing tissue remodeling after tooth extraction.

Generally, early implantation procedures are preferred in the anterior maxillary region, which is frequently affected by a significant degree of atrophy immediately after extraction and where esthetics is of prime importance. This study demonstrated that marked dimensional alterations occurred in the implant site of dogs after 3 months of healing following tooth extraction. Bone loss was more pronounced at the buccal aspect of the ridge than at the lingual aspect. The placement of an implant in the fresh extraction socket failed to prevent the remodeling that occurs in the socket walls. The resulting height and width of the buccal and lingual walls at 3 months were reduced and the vertical bone-level change was more pronounced at the buccal aspect of the ridge than at the lingual aspect. This suggests that the resorption of the socket walls that occurs after tooth extraction must be considered in conjunction with implant placement in fresh extraction sockets. However, from the observations in some of the microgrooved group, we have found bone attachment to the 12 μm microgrooved surface and collagen fibers perpendicular to the long axis of the implants over the 8 μm microgrooved surface. Within the limitations of this study, microgrooved implants may provide more favorable conditions for the attachment of hard and soft tissues and may reduce the level of marginal bone resorption and soft tissue recession.

Conclusion

From the observations in some of the microgrooved groups, we have found bone attachment to the 12 μm microgrooved surface and collagen fibers perpendicular to the long axis of the implants over the 8 μm microgrooved surface. This orientation of the connective tissue bundle is similar to that observed in natural teeth and can be expected to prevent epithelial downgrowth and saucerization of the soft tissue around implants. Therefore, we conclude that microgrooved implants may provide more favorable conditions for the attachment of hard and soft tissues and may reduce the level of marginal bone resorption and soft tissue recession.

References

Adeli, R., Lekholm, U., Rockler, B. & Brånemark, P.I. (1981) A 15-year study of osseointegrated implants in the treatment of the edentulous jaw. *International Journal of Oral Surgery* **10**: 387–416.

Akimoto, K., Becker, W., Persson, R., Baker, D.A., Rohrer, M.D. & O'Neal, R.B. (1999) Evaluation of titanium implants placed into simulated extraction sockets: a study in dogs. *International Journal of Oral & Maxillofacial Implants* **14**: 351–360.

Albrektsson, T.O., Johansson, C.B. & Sennerby, L. (1994) Biological aspects of implant dentistry: osseointegration. *Periodontology 2000* **4**: 58–73.

Araújo, M.G. & Lindhe, J. (2005) Dimensional ridge alterations following tooth extraction. An

© 2010 John Wiley & Sons A/S

experimental study in the dog. *Journal of Clinical Periodontology* **32**: 212–218.

Araújo, M.G., Sukekeva, F., Wennström, J.L. & Lindhe, J. (2005) Ridge alterations following implant placement in fresh extraction sockets: an experimental study in the dog. *Journal of Clinical Periodontology* **32**: 645–652.

Araújo, M.G., Sukekeva, F., Wennström, J.L. & Lindhe, J. (2006a) Tissue modeling following implant placement in fresh extraction sockets. *Clinical Oral Implants Research* **17**: 615–624.

Araújo, M.G., Wennström, J.L. & Lindhe, J. (2006b) Modeling of the buccal and lingual bone walls of fresh extraction sites following implant installation. *Clinical Oral Implants Research* **17**: 606–614.

Atwood, D.A. (1962) Some clinical factors related to rate of resorption of residual ridges. *The Journal of Prosthetic Dentistry* **12**: 441–450.

Atwood, D.A. (1963) Postextraction changes in the adult mandible as illustrated by microradiographs of midsagittal sections and serial cephalometric roentgenograms. *The Journal of Prosthetic Dentistry* **13**: 810–825.

Berglundh, T., Abrahamsson, I., Lang, N. & Lindhe, J. (2003) De novo alveolar bone formation adjacent to endosseous implants. A model study in the dog. *Clinical Oral Implants Research* **14**: 251–262.

Botticelli, D., Berglundh, T., Buser, D. & Lindhe, J. (2003a) Appositional bone formation in marginal defects at implants. An experimental study in the dog. *Clinical Oral Implants Research* **14**: 1–9.

Botticelli, D., Berglundh, T., Buser, D. & Lindhe, J. (2003b) The jumping distance revisited. An experimental study in the dog. *Clinical Oral Implants Research* **14**: 35–42.

Botticelli, D., Berglundh, T. & Lindhe, J. (2004a) Hard tissue alterations following immediate implant placement in extraction sites. *Journal of Clinical Periodontology* **31**: 820–828.

Botticelli, D., Berglundh, T. & Lindhe, J. (2004b) Resolution of bone defects of varying dimension and configuration in the marginal portion of the peri-implant bone. An experimental study in the dog. *Journal of Clinical Periodontology* **31**: 309–317.

Botticelli, D., Berglundh, T., Persson, L.G. & Lindhe, J. (2005) Bone regeneration at implants with turned or rough surfaces in self-contained defects. An experimental study in the dog. *Journal of Clinical Periodontology* **32**: 448–455.

Botticelli, D., Persson, L.G., Lindhe, J. & Berglundh, T. (2006) Bone tissue formation adjacent to implants placed in fresh extraction sockets. An experimental study in dogs. *Clinical Oral Implants Research* **17**: 351–358.

Brånemark, P.I., Zarb, G. & Albrektsson, B. (1985) *Tissue-Integrated Prostheses – Osseointegration in Clinical Dentistry*. Quintessence Publishing Co. Inc., Hanover Park, IL, USA.

Chehroudi, B., Gould, T.R.L. & Brunette, D.M. (1989) Effects of a grooved titanium-coated implant surface on epithelial cell behavior *in vitro* and *in vivo*. *Journal of Biomedical Materials Research* **23**: 1067–1085.

Chehroudi, B., Gould, T.R.L. & Brunette, D.M. (1990) Titanium-coated micromachined grooves of different dimensions affect epithelial and connective-tissue cells differently *in vivo*. *Journal of Biomedical Materials Research* **24**: 1203–1219.

Chehroudi, B., Gould, T.R.L. & Brunette, D.M. (1992) The role of connective tissue in inhibiting epithelial downgrowth on titanium-coated percutaneous implants. *Journal of Biomedical Materials Research* **26**: 493–515.

Cochran, D.L., Buser, D., ten Bruggenkate, C.M., Weingart, D., Taylor, T.M., Bernard, J.-P., Peters, F. & Simpson, J.P. (2002) The use of reduced healing time on ITI® implants with a sandblasted and acid-etched (SLA) surface: early results from clinical trials on ITI® SLA implants. *Clinical Oral Implants Research* **13**: 144–153.

Cochran, D.L. & Douglas, H.B. (1993) Augmentation of osseous tissue around nonsubmerged endosseous dental implants. *International Journal of Periodontal and Restorative Dentistry* **13**: 507–519.

Covani, U., Bortolaia, C., Barone, A. & Sbordone, L. (2004) Bucco-lingual crestal bone jaw. Changes after immediate and delayed implant placement. *Journal of Periodontology* **75**: 1605–1612.

Covani, U., Cornelini, R. & Barone, A. (2003) Bucco-lingual bone remodeling around implants placed into immediate extraction sockets: a care series. *Journal of Periodontology* **74**: 268–273.

Davies, J.E. (1998) Mechanisms of endosseous integration. *The International Journal of Prosthodontics* **11**: 391–401.

Hämmerle, C.H.F., Brägger, U., Schmid, B. & Lang, N.P. (1998) Successful bone formation at immediate transmucosal implants: a clinical report. *The International Journal of Oral & Maxillofacial Implants* **13**: 522–530.

Johnson, K. (1963) A study of the dimensional changes occurring in the maxilla after tooth extraction – part I. Normal healing. *Australian Dental Journal* **8**: 428–433.

Johnson, K. (1969) A study of the dimensional changes occuring in the maxilla following tooth extraction. *Australian Dental Journal* **14**: 241–244.

Kan, J.Y.K., Rungcharassaeng, K. & Lozada, J. (2003) Immediate placement and provisionalization of maxillary anterior single implants: 1-year prospective study. *The International Journal of Oral & Maxillofacial Implants* **18**: 31–39.

Kim, H., Murakami, H., Chehroud, I.B., Textor, M. & Brunette, D.M. (2006) Effects of surface topography on the connective tissue attachments to subcutaneous implants. *The International Journal of Oral & Maxillofacial Implants* **21**: 354–365.

Knox, R., Caudill, R. & Meffert, R. (1991) Histological evaluation of dental endosseous implants placed in surgically created extraction defects. *Clinical Oral Implants Research* **11**: 365–375.

Lang, N.P., Brägger, U., Hämmerle, C.H.F. & Sutter, F. (1994) Immediate transmucosal implants using the principle of guided tissue regeneration. I. *Clinical Oral Implants Research* **5**: 154–163.

Lazzara, R.J. (1989) Immediate implant placement into extraction sites: surgical and restorative advantages. *International Journal of Periodontal and Restorative Dentistry* **9**: 333–343.

Maroudas, N.G. (1972) Anchorage dependence: correlation between amount of growth and diameter of bead, for single cells grown on individual glass bead. *Experimental Cell Research* **74**: 337–342.

Matsuzaka, K., Walboomers, X.F., Yoshinari, M., Inoue, T. & Jansen, J.A. (2003) The attachment and growth behavior of osteoblast-like cells on microtextured surfaces. *Biomaterials* **24**: 2711–2719.

Nemcovsky, C.E., Artzi, Z., Moses, O. & Gelernter, I. (2002) Healing of marginal defects at implants placed in fresh extraction sockets of after 4–6 weeks of healing. A comparative study. *Clinical Oral Implants Research* **13**: 410–419.

Paolantonio, M., Dolci, M., Scarano, A., d'Archivio, D., Placido, G., Tumini, V. & Piatelli, A. (2001) Immediate implantation in fresh extraction sockets. A controlled clinical and histological study in man. *Journal of Periodontology* **P72**: 1560–1571.

Pietrokovski, J. & Massler, M. (1967) Alveolar ridge resorption following tooth extraction. *The Journal of Prosthetic Dentistry* **17**: 21–27.

Rovensky, Y.A., Slavanaja, I.L. & Vasiliev, J.M. (1971) Behavior of fibroblast-like cells on grooved surfaces. *Experimental Cell Research* **65**: 193–201.

Schropp, L., Wenzel, A., Kostopoulos, L. & Karring, T. (2003) Bone healing and soft tissue contour changes following single-tooth extraction: a clinical and radiographic 12-month prospective study. *International Journal of Periodontal and Restorative Dentistry* **23**: 313–323.

Schwartz-Arad, D. & Chaushu, G. (1997) Placement of implants into fresh extraction sites: 4 to 7 years retrospective evaluation of 95 immediate implants. *Journal of Periodontology* **68**: 1110–1116.

Steenberghe, D., Callens, A., Geers, L. & Jacobs, R. (2000) The clinical use of deproteinized bovine bone mineral on bone regeneration in conjunction with immediate implants installation. *Clinical Oral Implants Research* **11**: 210–216.

Tallgren, A. (1972) The continuing reduction of the residual alveolar ridges in complete denture wearers: a mixed-longitudinal study covering 25 years. *The Journal of Prosthetic Dentistry* **27**: 120–132.

Touati, B. & Rompen, E. (2005) A new concept for optimizing soft tissue integration. *Practical Procedures and Aesthetic Dentistry* **17**: 711–715.

Walboomers, X.F., Croes, H.J.E., Ginsel, L.A. & Jansen, J.A. (1998) Growth behavior of fibroblasts on microgrooved polystyrene. *Biomaterials* **19**: 1861–1868.

Walboomers, X.F. & Jansen, J.A. (2001) Cell and tissue behavior on micro-grooved surfaces. *Odontology* **89**: 2–11.

Wilderman, M.N. (1963) Repair after a periosteal retention procedure. *Journal of Periodontology* **34**: 487–503.

Wilson, T.G., Schenk, R., Buser, D. & Cochran, D. (1998) Implants placed in immediate extraction sites: a report of histologic and histometric analyses of human biopsies. *The International Journal of Oral & Maxillofacial Implants* **13**: 333–341.

Wood, D.L., Hoag, P.M., Donnenfeld, W.O. & Rosenfeld, L.D. (1972) Alveolar crest reduction following full and partial thickness flaps. *Journal of Periodontology* **43**: 141–144.

© 2010 John Wiley & Sons A/S