Osseointegration on Metallic Implant Surfaces: Effects of Microgeometry and Growth Factor Treatment

Sally R. Frenkel,[1] Jordan Simon,[1] Harold Alexander,[2] Michael Dennis,[1] John L. Ricci[3]

[1] Department of Orthopaedic Surgery, Musculoskeletal Research Center, New York University Hospital for Joint Diseases, New York, New York 10003

[2] Orthogen, Inc., Springfield, New Jersey

[3] University of Medicine and Dentistry of New Jersey, Newark, New Jersey

Received 20 December 2001; revised 2 May 2002; accepted 14 May 2002

Abstract: Orthopedic implants often loosen due to the invasion of fibrous tissue. The aim of this study was to devise a novel implant surface that would speed healing adjacent to the surface, and create a stable interface for bone integration, by using a chemoattractant for bone precursor cells, and by controlling tissue migration at implant surfaces via specific surface microgeometry design. Experimental surfaces were tested in a canine implantable chamber that simulates the intramedullary bone response around total joint implants. Titanium and alloy surfaces were prepared with specific microgeometries, designed to optimize tissue attachment and control fibrous encapsulation. TGFβ, a mitogen and chemoattractant (Hunziker EB, Rosenberg LC. J Bone Joint Surg Am 1996;78:721–733) for osteoprogenitor cells, was used to recruit progenitor cells to the implant surface and to enhance their proliferation. Calcium sulfate hemihydrate (CS) was the delivery vehicle for TGFβ; CS resorbs rapidly and appears to be osteoconductive. Animals were sacrificed at 6 and 12 weeks postoperatively. Results indicated that TGFβ can be reliably released in an active form from a calcium sulfate carrier *in vivo*. The growth factor had a significant effect on bone ingrowth into implant channels at an early time period, although this effect was not seen with higher doses at later periods. Adjustment of dosage should render TGFβ more potent at later time periods. Calcium sulfate treatment without TGFβ resulted in a significant increase in bone ingrowth throughout the 12-week time period studied. Bone response to the microgrooved surfaces was dramatic, causing greater ingrowth in 9 of the 12 experimental conditions. Microgrooves also enhanced the mechanical strength of CS-coated specimens. The grooved surface was able to control the direction of ingrowth. This surface treatment may result in a clinically valuable implant design to induce rapid ingrowth and a strong bone-implant interface, contributing to implant longevity. © 2002 Wiley Periodicals, Inc. J Biomed Mater Res (Appl Biomater) 63: 706–713, 2002

Keywords: joint prosthesis; implant loosening; growth factor; textured surface; animal model

INTRODUCTION

Uncemented total hip arthroplasty is often indicated for younger patients who are likely to place a higher demand on their prostheses than elderly recipients. Long-term survival of uncemented hip components is dependent on biological fixation. To achieve biological fixation of uncemented or press-fit implants, close apposition of bone to the implant surface and initial mechanical stability are required.[1] Osteoconductive coatings not only enhance both the integration of an implant with host bone and the strength of the bone–implant interface, but also prolong the implant's useful life.[2] Titanium and titanium alloy implants with such coatings are widely used to encourage biological fixation,[3] due to the biocompatibility and mechanical properties of the metals, and the stability and conductivity of the coatings.[4–6]

Orthopedic implants often loosen due to the invasion of fibrous tissue. The natural tendency for surface dynamics to shift from bone attachment to fibrous encapsulation is governed by surface chemistry, strain, and microgeometry. The aim of this study was to devise a novel implant surface that would speed healing adjacent to the surface, and create a stable interface for bone integration, by selectively attracting bone precursor cells using an osteogenic cell mitogen, and by

Correspondence to: Sally R. Frenkel, Musculoskeletal Research Center, New York University Hospital for Joint Diseases, 301 East 17th Street, New York, NY 10003 (e-mail: sally.frenkel@excite.com)

Contract grant sponsor: NIH STTR; contract grant number: A-11133608934
Contract grant sponsor: Orthogen Corporation, Springfield, NJ

© 2002 Wiley Periodicals, Inc.

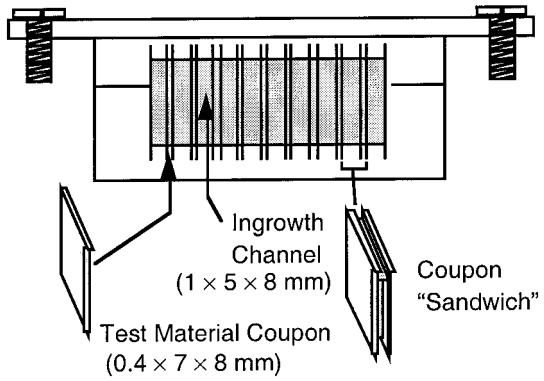

Figure 1. Schematic of implant chamber.

controlling tissue migration at implant surfaces via specific surface microgeometry design.

The experimental surfaces were tested in a canine implantable chamber. This chamber has been used to examine tissue response to a variety of implants and coatings, including metal and plastic surfaces with different compositions and surface textures, hydroxyapatite coatings and particulate, and resorbable polymers.[7–10] The model simulates the intramedullary bone response around total joint implants. The chamber has multiple bone ingrowth channels that can be lined with different test materials, and used for side-by-side comparison of bone response to these materials. Metal and alloy surfaces were prepared with specific microgeometries, designed to optimize tissue attachment and control fibrous encapsulation, while encouraging bone integration. Transforming growth factor beta (TGFβ), a mitogen and chemoattractant[11] for osteoprogenitor cells *in vitro* and *in vivo*,[12–14] was used to recruit a population of progenitor cells to the implant surface and to enhance their proliferation. Calcium sulfate hemihydrate (CS) was the delivery vehicle for TGFβ; CS resorbs rapidly and appears to be osteoconductive [15]

MATERIALS AND METHODS

Evaluation of Surface Microgeometry of Laser-Micromachined Test Samples

Experimental coupons for this study were fabricated by the Orthogen Corporation, Springfield, NJ. These consisted of (1) alumina grit-blasted titanium alloy (6% aluminum, 4% vanadium); (2) commercially pure titanium (CP-TI) samples with 12-μm square-wave microgrooves 12 μm in depth and with 12-μm spacing (MG); and (3) alumina grit-blasted CP-Ti. Samples of laser-micromachined coupons as well as controls were analyzed before use for feature size, shape, and spacing by light and scanning electron microscopy, using calibrated standards, to ensure consistency and adherence to design protocols.

In Vivo Evaluation of Tissue Response to CS/GF Composite and Micromachined Surfaces

Each of the surfaces described above (alloy, MG, and CP-Ti) were used to line channels in the experimental chamber model, as described below, and the chambers were implanted either uncoated, filled with CS, or filled with CS/TGFβ. Thus nine combinations of surfaces, carriers, and growth factor, were used:

1. Alloy (uncoated) 4. Alloy/CS 7. Alloy/CS/TGFβ
2. MG (uncoated) 5. MG/CS 8. MG/CS/TGFβ
3. CP-Ti (uncoated) 6. CP-Ti/CS 9. CP-Ti/CS/TGFβ

Chamber Configurations, Time Periods, and Animal Numbers. Sixteen skeletally mature tricolor hounds were used in this study. Four time periods were used: 2 and 4 weeks ($N = 5$ each), and 6 and 12 weeks ($N = 3$ each).

Chambers were machined out of medical-grade ultrahigh-molecular-weight polyethylene (Figure 1). Twenty coupons of the three experimental surfaces were placed in pairs in slots cut into the top and bottom of the central space in the implant, lining the ten 1 × 5 × 8-mm ingrowth channels created. Each chamber thus contained 10 channels lined with two coupons per channel. The assembled chambers were sterilized with ethylene oxide. Three configurations of chambers were used: (1) chambers with all channels left uncoated; (2) chambers with all channels filled with CS hemihydrate (US Gypsum Corp., Chicago, IL) and (3) chambers with all channels filled with CS/TGFβ. In the 4-, 6-, and 12-week groups, 200 ng of TGFβ3 (gift of Novartis, Inc., Basel, Switzerland) were contained in each channel. Implants for the 2-week animals received 60 ng of TGFβ per channel. Uncoated channels, channels with CS, and channels with CS/TGFβ were not mixed within one chamber because of the potential for bleed of the released components into adjacent channels. An outer lip of 2 mm was built onto the UHMW polyethylene implant to seal off the intramedullary space from ingrowth of periosteal new bone. The row of ingrowth channels was offset by 2 mm from the outer lip of the implant so that after implantation they were wholly within the intramedullary canal and not adjacent to any transcortical bone surface.

Surgical Procedure. Chambers were implanted through a rectangular longitudinal cortical defect in the lateral metaphysis of the distal femur. The supracondylar region of the femur was approached by an incision extending along the lateral border of the patellar tendon to the tibial tubercle. The lateral cortex of the distal femur was reached through the plane between the vastus lateralis and the lateral hamstrings. The patella was dislocated medially to facilitate the exposure. A drill template was fixed to the lateral metaphysis with the use of Kirshner wires, and an 8 × 25-mm rectangle was marked by serial drill holes. The drill holes were connected with an osteotome and the lateral window removed. A 10-mm-deep rectangle of cancellous metaphyseal bone was removed flush with the sides of the defect, and the implant was inserted with a snug fit. Blood filling the intramedullary defect was used to fill the implant channels, so that no air was left in the channels. The chamber was held in place with



Figure 2. Scanning electron micrograph of coupon with 12-μ-wide grooves machined in the surface. Bar = 10 μ.

unicortical bone screws. After implantation, the channel openings faced the endosteal surface of the intact anterior and posterior cortices. Interrupted sutures were used to close the fascia lata and patellar retinaculum and to reapproximate the subcutaneous tissue, with stainless steel sutures for the skin. Animals were given intramuscular penicillin-G procaine preoperatively and for 5 days postoperatively.

Sacrifice, Removal of Chambers, Sample Numbers, and Analysis. Dogs were sacrificed at the specified time periods postoperatively and femurs harvested. A diamond wire saw was used to isolate each implant.

Faxitron Histomorphometry. Faxitron morphometry was conducted on all chambers through digitization of the high-resolution X-rays of the intact chambers. Maximum lengths of radiographically visible bone ingrowth through the 1-mm-thick channels were calculated as percentages of total channel length. Some implants were then disassembled for mechanical testing.

Sample Numbers and Analysis. Five dogs each were sacrificed at 2 and 4 weeks. This produced 30 channels containing neither CS nor CS/TGFβ; 30 channels containing CS; and 40 channels containing CS/TGFβ. In each of the three groups, 10–14 channels were lined with the alloy, MG, or CP-Ti surface.

Three dogs each were sacrificed at 6 and 12 weeks, yielding 20 channels containing neither CS nor CS/TGFβ; 20 channels containing CS; and 20 channels containing CS/TGFβ. Of the 20 channels in each group, 6–7 were lined with the alloy, MG, or CP-Ti surface.

Statistical Analysis. Multivariate repeated-measures analysis of variance (ANOVA) was used to analyze the mechanical testing and Faxitron data. The Tukey test was used for all post hoc multiple comparisons.

Mechanical Testing. Each sample consisted of a pair of plates of the experimental materials and the ingrown bone and soft tissue. This sandwich was tested in tensile mode to failure in an Instron servohydraulic mechanical testing system by applying tensile force to the top and bottom plates, at a rate of 2.5% strain per second. This mode of testing induced a state of plane strain in the sample at a rate within the range of physiological bone loading. Failure strengths were expressed in Newtons.



Figure 3. Radiograph of implant channels at : (a) 2 weeks postoperative. Note thin trabeculae of bone ingrowth at ends of channel, with soft tissue and residual CS in the central portion of the channel. (b), 4 weeks postoperative. Trabeculae are thicker and longer than at earlier time point. (c), 6 weeks postoperative. Bone nearly fills the channel. (d) 12 weeks postoperative. Although bone still bridges the entire channel, remodeling and resorption have begun.



Figure 4. Scanning electron micrograph showing bone growth within the grooves of the microgrooved surfaces, oriented parallel to the grooves. Bar = 100 μ.

RESULTS

Scanning-electron microscopy revealed that the feature size, shape, and spacing of the micromachined coupons were consistent with standards and reproducibly adhered to the design protocols (Figure 2).

TABLE I. Percentage of Bone Ingrowth into Canine Femoral Implant Chambers

Surface Type	Uncoated	$CaSO_4$	$CaSO_4$/ TGFB
2 weeks postimplantation			
Alloy	6.9 ± 11.4	9.2 ± 11.6	45.5 ± 16.9
CP-Ti	18.2 ± 15.0	26.8 ± 24.7	32.9 ± 25.1
Microgrooved CP-Ti	24.6 ± 10.0	51.6 ± 16.2	36.6 ± 9.9
4 weeks postimplantation			
Alloy	58.8 ± 10.3	81.4 ± 21.6	4.0 ± 10.1
CP-Ti	31.2 ± 12.8	59.2 ± 30.9	20.5 ± 9.7
Microgrooved CP-Ti	50.5 ± 6.2	85.4 ± 16.0	61.2 ± 33.0
6 weeks postimplantation			
Alloy	31.8 ± 16.0	77.4 ± 23.1	36.9 ± 12.8
CP-Ti	58.1 ± 4.6	79.3 ± 12.3	8.6 ± 9.0
Microgrooved CP-Ti	88.9 ± 12.2	100 ± 0	64.2 ± 22.4
12 weeks postimplantation			
Alloy	19.8 ± 10.3	51.8 ± 26.9	66.8 ± 22.6
CP-Ti	27.2 ± 10.9	66.4 ± 30.8	42.0 ± 7.9
Microgrooved CP-Ti	45.5 ± 13.5	96.2 ± 7.5	39.6 ± 8.1

CS Resorption

Faxitron imaging showed a progressive resorption of the CS over time, occurring from the open ends of the channels inward toward the center. At 2 weeks, a residual central portion of the CS was seen in some channels, and by 4 weeks the CS was almost completely dissolved in most channels. No identifiable CS was seen in the 6- or 12-week samples.

Tissue Ingrowth

Faxitron images showed an organized progression of soft tissue and bone ingrowth into the individual channels of the implantable chamber, with the amounts of the tissues dependent on the contents of the channel and the composition of the channel walls. At 2 weeks [Figure 3(a)], the open ends of the channels showed bone ingrowth consisting of thin trabeculae of bone, while the central portions of the channels contained soft tissue and CS. At 4 and 6 weeks, bone ingrowth was more extensive and consisted of thicker trabeculae [Figure 3(b)]. In many of these channels, by 6 weeks the bone filled or nearly filled the channels [Figure 3(c)]. By 12 weeks, the ingrown bone had begun remodeling. [Figure3(d)]. At this time period, the CS channels were almost completely filled with bone, whereas in many of the unlined channels, significant bone resorption was seen. The retention of bone in the CS channels may be due to the direct mechanical bond (discussed below) between the bone and the CS surfaces. Scanning-electron microscopy demonstrated that bone grew

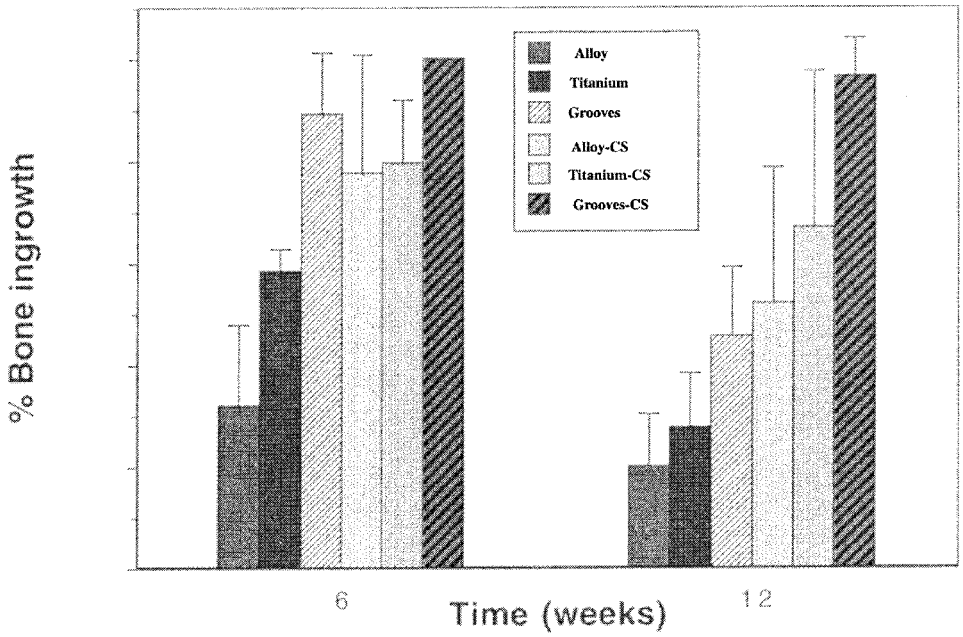

Figure 5. Percentage of bone ingrowth into channels at 6 and 12 weeks.

within the grooves of the microgrooved surfaces, and was therefore oriented parallel to the grooves (Figure 4).

Faxitron Data

Two Weeks Postimplantation. Percentage of bone ingrowth into the chamber channels is shown in Table I and Figure 5. At 2 weeks, CS/TGFβ-lined channels showed significantly greater ingrowth than uncoated channels, regardless of the coupon surface (Figure 6). On alloy surfaces, the percentage of ingrowth was 6.9 $\pm$ 11.4% in uncoated chambers, 9.2 $\pm$ 11.6% in CS chambers, and 45.4 $\pm$ 16.9% with CS-TGFβ. Ingrowth was also greater with CS/TGFβ than with CS alone, except on the microgrooved (MG) surfaces; MG combined with CS showed a 51.6 $\pm$ 16.2% filling, a large amount of bone for this early time point.

Ingrowth into channels lined with CS alone did not differ significantly from uncoated channels in the alloy and CP-Ti groups. However, in the alloy and CP-Ti groups, the MG surfaces contained more bone.

Four Weeks Postimplantation. At 4 weeks, the CS-TGFβ appeared to have inhibited bone growth on alloy and CP-Ti coupon surfaces. Only with MG treatment was CS-TGFβ able to induce greater ingrowth than in uncoated channels, although not as much as CS alone. In the CS treatment group, there was no significant difference between



Figure 6. Radiograph of implant chamber at 2 weeks postoperative. (a) Channels contain uncoated MG surfaces. (b) Channels contain MG surfaces coated with CS/TGF-b. CS/TGFβ-coated channels showed significantly greater ingrowth than uncoated channels.



Figure 7. Radiograph of implant chamber at 4 weeks postoperative. (a) Channels contain uncoated Ti surfaces. (b) Channels contain Ti surfaces coated with CS. CS induced significantly greater bone ingrowth.



Figure 8. Radiograph of implant chamber at 6 weeks postoperative. From the top, Channels 1–6 contain uncoated alloy surfaces, Channels 7–10 contain uncoated MG surfaces. Channels containing MG surfaces showed significantly greater bone ingrowth.

the percent penetration on alloy or MG surfaces (81.4 ± 21.6% alloy, 85.4 ± 16% MG). However, in the uncoated chambers, the channels containing alloy surfaces showed significantly more ingrowth (58.8 ± 10.3) than those with MG surfaces (50.5 ± 6.2). In comparing CS treatment to uncoated chambers, CS induced a significantly greater ingrowth regardless of the surface type (Figure 7).

Six Weeks Postimplantation. At 6 weeks, channels containing MG surfaces showed significantly greater ingrowth whether in uncoated, CS, or CS-TGFβ-treated chambers (Figure 8). With MG surfaces and CS, the channels were 100% filled. At this time point, chambers containing alloy or MG surfaces demonstrated their peak ingrowth; CS-TGFβ chambers had a continued increase in ingrowth at 12 weeks (from 36.3 ± 28% to 49.7 ± 15%), but the difference was not statistically significant.

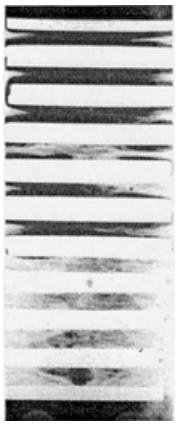

Figure 9. Radiograph of implant chamber at 12 weeks postoperative. From the top, Channels 1–6 contain CS-coated alloy surfaces, Channels 7–10 contain CS-coated MG surfaces. CS/MG channels remained almost completely filled at this time point, while other channels showed some remodeling.

TABLE II. Mechanical Testing Results at 6 Weeks

Surface	Failure Strength (N)
Uncoated channels	
Alloy	–
CP-Ti	–
MG	12.5 ± 9.8
CS-filled channels	
Alloy	1.25 ± 3.06
CP-Ti	0.57 ± 1.51
MG	48.9 ± 28.9

Twelve Weeks Postimplantation. At the final time point in this study, remodeling was reflected in the reduced amounts of ingrowth seen in the uncoated and CS-lined channels. However, the MG surface treatment again resulted in greater ingrowth in both uncoated and CS-lined channels. With 96.2 ± 7.5%, the MG-CS channels remained almost completely filled (Figure 9). In the CS-TGFβ-filled channels, ingrowth was significantly greater on the alloy coupons than either CP-Ti or MG. At 12 weeks, the percentage of ingrowth into uncoated, CS-, or CS-TGFβ-lined channels did not differ significantly, probably due to the large standard deviations. The mean percentages of ingrowth were 31 ± 13.5% in uncoated chambers, 71.3 ± 22.5% with CS, and 49.7 ± 15% with CS-TGFβ.

Mechanical Testing Data

Failure strengths of the various specimens are shown in Table II and Figure 10. The only uncoated channels with enough integrity to be tested at 6 weeks were those lined with MG. They had a failure strength of 12.5 ± 9.8 N. In CS chambers, MG surfaces showed far greater strength than the other coupons. CS-TGFβ samples had insufficient ingrowth for testing. At 12 weeks, only MG-CS coupons could be tested; they failed at 42 N, which was not significantly different than the 6-week strength.

DISCUSSION

In the implantable chamber used in this study, bone ingrowth is most variable at the early time periods, thus requiring more samples at these time periods. In a previous study involving CS carrier, maximum bone ingrowth was noted by 6 weeks.[15] Thus the 2- and 4-week samples were necessary to examine early effectiveness of the TGFβ, and to determine the early effects of the test substrates. TGFβ-3, which had not been widely studied in bone, was used. Although TGFβ-1 or TGFβ-2, both of which have anabolic effects on bone, were not tested in this model, it is expected that the isoforms would produce similar results based on the similarities between these molecules and their effects on skeletal tissues reported by others. [16,17]

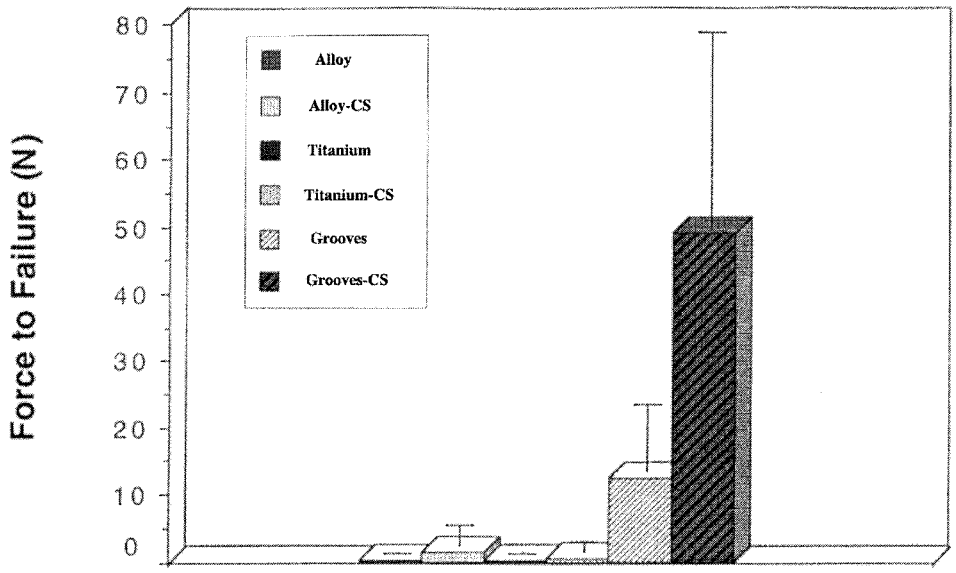

Figure 10. Force to failure of 6- and 12-week specimens.

Faxitron imaging has the advantage of showing the amount of bone ingrowth before any processing occurs or before the chamber is dismantled. This technique shows all of the bone in the channel, superimposed in cross section, so the maximum amount of bone penetration is observed. The technique also allows analysis of every sample produced, because it is nondestructive and is done before samples are mechanically tested or processed for histology. However, Faxitron imaging does not differentiate between the types and quality of mineralized tissue.

Effects of Growth Factor. An increase in bone ingrowth into the channels resulted from TGFβ (low dose) administration for the 2-week alloy and CP-Ti samples. However, this effect was not seen at 4 or 6 weeks (high dose), when the CS channels had significantly greater bone ingrowth than the TGFβ groups.

Optimum dosing and timing of the TGFβ release are difficult to determine. Studies have shown that TGFβ increases osteoblast and fibroblast proliferation.[18] However, in high doses it may be inhibitory. TGFβ is found naturally in bone matrix, which suggests a possible role in long-term maintenance.[19] Furthermore, the duration of exposure to the TGFβ, even in the short term, has not been optimized. In vitro testing has shown a positive dose-response curve of fetal rat calvarial cells over a range of 0.1–100 ng/ml.[20]

In the 4-, 6-, and 12-week groups, 200 ng of TGFβ3 were contained in each channel. This dosage was based on published *in vivo* studies.[21] Calculations of release kinetics in previous laboratory studies indicated that the growth factor would be released over 4 weeks as the CS carrier resorbed.[10] However, the thin coating of CS and CS-TGFβ applied to the coupons may have released the TGFβ at too rapid a rate, thereby allowing unacceptably high, inhibitory levels to be present within the channels at 4 weeks. The 6-week animals were the first to be sacrificed in this study. Upon seeing the low amount of bone ingrowth in those samples, the dose of growth factor given to the 2-week animals was sharply reduced to 60 ng of TGFβ per channel (remaining groups had already been implanted with the high dose). This reduction did indeed result in a statistically significant increase in ingrowth with TGFβ at 2 weeks.

Effects of CS. CS correlated with increases in the amount of bone ingrowth at all time points. As early as 1892, Dreesman[22] reported on the use of CS for filling bone defects of various sizes. More recently, CS was shown to resorb slowly, with gradual replacement by bone; Peltier found that the rate of resorption depends on exposure to the periosteum.[23] If the CS is isolated, a very slow pattern of resorption is seen. However, with periosteal exposure, replacement of the CS by bone was seen within 90 days. Peltier believed that CS alone is not osteoinductive, but that when exposed to periosteum or bone it can act as an accelerator of bone ingrowth. In addition, many others continue to report on the successful use of CS in orthopedic applications. These applications include CS as a bone-graft substitute and extender, for repair of osteochondral defects and benign bone lesions, and in sinus augmentation and spine fusion.[24–30] In the present study, the CS also showed a pattern of early resorption (4–6 weeks in an intramedullary location), with the simultaneous replacement by bone.

Effects of Surface Treatment. CP-Ti and alloy surfaces did not demonstrate in a consistent fashion that one was superior to the other; rather, there was considerable variability at the different time points. However, the MG-treated surfaces caused more ingrowth in 9 of the 12 experimental conditions. Others have reported positive effects of surface topography on cell growth and orientation.[31,32] In this study, microgrooved surfaces enhanced the mechanical strength of CS-coated specimens, and were the only specimens with enough mechanical strength to be tested at the early time point of 6 weeks. Bone on the MG surfaces appeared to have

undergone less resorption at the end point of the study than did bone on the other surfaces. In addition, it is extremely significant that the grooved surface was able to control the direction of ingrowth.

CONCLUSION

Recombinant human transforming growth factor beta can be reliably released in an active form from a calcium sulfate carrier *in vivo*. The growth factor had a significant effect on bone ingrowth into implant channels at an early time period, although this effect was not seen with higher doses at later periods. Adjustment of dosage may render TGFβ more potent at later time periods.

CS treatment resulted in a significant increase in bone ingrowth throughout the 12-week time period studied. It has been shown earlier that CS causes local precipitation of calcium phosphate deposits, which act as a nidus for new bone formation.[33] This process may be the mechanism for the bone replacement seen in earlier orthopedic use of CS. Finally, bone response to the MG implants was dramatic; this surface treatment may result in a clinically valuable implant design to induce rapid ingrowth and a strong bone–implant interface, contributing to implant longevity.

REFERENCES

1. Jaffe WL, Scott DF. Total hip arthroplasty with hydroxapatite-coated prostheses. J Bone Jt Surg 1996;78A:1918.
2. Labat B, Demonet N, Rattner A, Aurelle JL, Rieu J, Frey J, Chamson A. Interaction of a plasma-sprayed hydroxyapatite coating in contact with human osteoblasts and culture medium. J Biomed Mater Res 1999;46:332.
3. Ding SJ, Ju CP, Chern Lin JH. Characterization of hydroxyapatite and titanium coatings sputtered on Ti-6Al-4V substrate. J Biomed Mater Res 1999;44:266.
4. Carlsson L, Rostlund T, Albrektsson B, Albrektsson T, Branemark P, Osseointegration of titanium implants. Acta Orthop Scand 1986;57:285.
5. Cook SD, Kay JF, Thomas KA, Jarcho M. Hydroxylapatite coated titanium for orthopaedic implant applications. Clin Orthop 1988;232:225.
6. Hench LL. Bioactive ceramics: From concept to clinic. J Am Ceram Soc 1992;74:1487.
7. Suganuma J, Alexander H. Biological response of intramedullary bone to poly-L-lactic acid. J Appl Biomater 1993;4:13–28.
8. Spivak JM, Ricci JL, Blumenthal NC, Alexander H. A new canine model to evaluate the biological response of intramedullary bone to implant materials and surfaces. J Biomed Mater Res 1990;24:1121–1149.
9. Choueka J, Charvet JL, Koval KJ, Alexander H, James KS, Hooper KA, Kohn J. Canine bone response to tyrosine-derived polycarbonates and poly(L-lactic acid). J Biomed Mater Res 1996;31:35–41.
10. Rosenblum S, Frenkel S, Ricci J, Alexander H. Diffusion of fibroblast growth factor from a plaster of Paris carrier. J Appl Biomater 1993;4:67–72.
11. Hunziker EB, Rosenberg LC. Repair of partial-thickness defects in articular cartilage: Cell recruitment from the synovial membrane. J Bone Joint Surg Am 1996;78:721–733.
12. Centrella M, McCarthy TL, Canalis E. Transforming growth factor B is a bifunctional regulator of replication and collagen synthesis in osteoblast-enriched cell cultures from fetal rat bone. J Biol Chem 1987;262:2869–2874.
13. Ashhurst DE, Bland YS, Crtichlow MA. The effects of exogenous TGFβ2 on the distribution of cells that synthesize types I and II collagen in developing bones. Trans Orthop Res Soc 1994;19:324.
14. Lind M, Deleuran B, Eriksen EF, Bunger C. Chemotaxis of human osteoblasts in response to osteotropic growth factors. Trans Orthop Res Soc 1994;19:128.
15. Ricci JL, Rosenblum SF, Brezenoff L, Blumenthal NC. Stimulation of bone ingrowth into an implantable chamber through the use of rapidly resorbing calcium sulfate hemihydrate. Trans World Biomat Congress 1992;15:49.
16. Rosier RN, O'Keefe RJ, Hicks DG. The potential role of transforming growth factor beta in fracture healing. Clin Orthop 1998;(355 Suppl):S294–S300.
17. Hunziker EB, Driesang IM, Morris EA. Chondrogenesis in cartilage repair is induced by members of the transforming growth factor-beta superfamily. Clin Orthop 2001;(391 Suppl): S171–S181.
18. Joyce ME, Roberts AB, Sporn MB, Bolander ME. Transforming growth factor-beta and the initiation of chondrogenesis and osteogenesis in the rat femur. J Cell Biol 1990;10:2195–207.
19. Joyce ME, Jingushi S, Bolander ME. Transforming growth factor-beta in the regulation of fracture repair. Orthop Clin North Am 1990;21:199–209.
20. Basic N, Basic V, Bulic K, Grgic M, Kleinman HK, Luyten FP, Vukicevic S. TGF-beta and basement membrane matrigel stimulate the chondrogenic phenotype in osteoblastic cells derived from fetal rat calvaria. J Bone Miner Res 1996;11:384–391.
21. Joyce ME, Terek RM, Jingushi S, Bolander ME. Role of TGFβ in fracture repair. In: Piez KA and Sporn M, editors, Transforming growth factor βs. New York: New York Academy of Sciences, 1990. pp 107–123.
22. Dreesman H, Ueber knochenplombierung. Beitr Klin Chir 1892; 9:804.
23. Peltier LF. The use of plaster of Paris to fill large defects in bone: A preliminary report, 1959. Clin Orthop 2001;382:3–5.
24. Parsons JR, Ricci JL, Alexander H., Bajpai PK. Osteoconductive composite grouts for orthopedic use. Ann NY Acad Sci1988;190–207.
25. Alexander DI, Manson NA, Mitchell MJ. Efficacy of calcium sulfate plus decompression bone in lumbar and lumbosacral spinal fusion: Preliminary results in 40 patients. Can J Surg 2001;44:262–266.
26. Mirzayan R, Panossian V, Avedian R, Forrester DM, Menendez LR. The use of calcium sulfate in the treatment of benign bone lesions. A preliminary report. J Bone Joint Surg Am 2001;83-A:355–358.
27. Kelly CM, Wilkins RM, Gitelis S, Hartjen C, Watson JT, Kim PT. The use of a surgical grade calcium sulfate as a bone graft substitute: results of a multicenter trial. Clin Orthop 2001;382:42–50.
28. al Ruhaimi KA. Effect of adding resorbable calcium sulfate to grafting materials on early bone regeneration in osseous defects in rabbits. Int J Oral Maxillofac Implants 2000;15:859-864.
29. Niederauer GG, Slivka MA, Leatherbury NC, Korvick DL, Harroff HH, Ehler WC, Dunn CJ, Kieswetter K. Evaluation of multiphase implants for repair of focal osteochondral defects in goats. Biomaterials 2000;21:2561–2574.
30. De Leonardis D, Pecora GE. Prospective study on the augmentation of the maxillary sinus with calcium sulfate: Histological results. J Periodontol 2000;71:940–947.
31. Chehroudi B, Gould TRL, Brunette DM. Effects of a grooved titanium-coated implant surface on epithelial cell behaviour *in vitro* and *in vivo*. J Biomed Mater Res 1990;24:1067–1085.
32. Brunette DM. The effects of implant surface topography on the behaviour of cells. Int J Oral Maxillofac Implants 1988;3:231–246.
33. Ricci JL, Charvet J, Frenkel SR, Chang R, Nadkarni P, Turner J, Alexander H. Bone response to laser microtextured surfaces. Trans Am Acad Orthop Surg, San Francisco, 2001.