The Effects of Laser Microtextured Collars Upon Crestal Bone Levels of Dental Implants

Saul Weiner, DDS,* Joshua Simon, MS,† David S. Ehrenberg, DDS, MS,‡ Barry Zweig, DDS,§ and John L. Ricci, PhD‖

Purpose: *The purpose of this study was to examine the crestal bone, connective tissue, and epithelial cell response to a laser microtextured collar compared with a machined collar, in the dog model.*

Materials: *Six mongrel dogs had mandibular premolars and first molars extracted and after healing replaced with BioLok implants 4 × 8 mm. Each dog had 3 control implants placed on one side of the mandible and 3 experimental, laser microtextured, implants placed contralaterally. After 3 months, 1 dog was killed. Bridges were placed on the implants of 4 of the dogs. The sixth dog served as a negative control for the duration of the experiment. Two of the dogs were killed 3 months after loading, of the dogs were killed 6 months after loading as was the negative (unloaded) control. Histology, electron microscopy, and histomorphometric analysis wasdone on histologic sections obtained from block sections of the mandible containing the implants.*

Results: *Initially the experimental implants showed greater bone attachment along the collar. With time the bone heights along the control and experimental collars were equivalent. However, the controls had more soft tissue downgrowth, greater osteoclastic activity, and increased saucerization compared with sites adjacent to experimental implants. There was closer adaptation of the bone to the laser microtextured collars.*

Conclusion: *Use of tissue-engineered collars with microgrooving seems to promote bone and soft tissue attachment along the collar and facilitate development of a biological width. (Implant Dent 2008;17:217–228)*

Key Words: implant collar, tissue engineering, laser microtexturing, biological width, crestal bone

Implant surface topography is important for the establishment of a stable bone-implant interface.[1] During the initial phases of healing, ie, osseointegration, adherence of platelets to the implant surface is critical. More recently, the value of a roughened surface to attract greater numbers of platelets and a denser fibrin clot has been demonstrated as useful for more rapid osseointegration with a resultant greater bone-implant contact.[2] Although these developments have enhanced osseointegration along the threaded portion of the implant, soft tissue and bone attachment to the collar may still be problematic. Dieback or crestal resorption in the bone adjacent to the coronal aspect of the implant to the first thread has been observed.[3]

Various theories have been advanced to explain this phenomenon. These include excessive stress to the crestal bone, surgical trauma, stress shielding, the microgap, and the establishment of the biological width.[4–6] Excessive stress to the crestal bone, commonly associated with occlusal overload, is considered a major cause of implant failure.[7–9] Often the crestal bone acts as a fulcrum for off-axis, *ie*, horizontal, forces during occlusal loading that can damage the interseptal bone with resorption and remodeling.[10] Surgical trauma has also been proposed[11] as a cause of crestal bone resorption, but there is little available evidence. At the time of second stage surgery, there is no correlation of surgical trauma with the crestal bone topography.[12]

The interface between the implant and the abutment, termed the microgap, serves as a reservoir of microorganisms.[13] The connective tissue in the microgap area contains a peak of inflammatory cells[14] and is associated with increased bone loss in experimental animal models. Similarly, there is strong evidence that the biological width observed at the dentogingival junction[15] has a similar form adjacent to the dental implant.[16] Placement of the implant below the bony crest will result in bone resorption and remodeling to re-establish a biologic width.[5] Finally, there is evidence that the topography of the implant collar, its dimensions and size are important factors for maintenance of the crestal bone. Cortical bone has poor resistance to shear stresses and machined, smooth collars may result in shear stresses that contribute to crestal bone resorption. Roughened surfaces, however, may convert these stresses to tensile and compressive stresses and

*Professor, Department of Restorative Dentistry, New Jersey Dental School, Newark, NJ.
†Research Scientist, Biomet, Inc. Parsippany, NJ.
‡Associate Professor, Department of Restorative Dentistry, New Jersey Dental School, Newark, NJ.
§Professor, Department of Oral and Maxillofacial Surgery, New Jersey Dental School, Newark, NJ.
‖Associate Professor, Department of Biomaterials and Biomimetics, New York University College of Dentistry, New York, NY.

ISSN 1056-6163/08/01702-217
Implant Dentistry
Volume 17 • Number 2
Copyright © 2008 by Lippincott Williams & Wilkins
DOI: 10.1097/ID.0b013e3181779016

Copyright © Lippincott Williams & Wilkins. Unauthorized reproduction of this article is prohibited.

result in a more stable crestal bone dimension.[17]

This study was undertaken to test a novel approach, using principles of tissue engineering, to stabilize the crestal bone, while at the same time using a specific surface geometry to develop an organized biological width. As the basis of this development, in a related series of *in vitro* and *in vivo* experiments, the effects of specific substrate surface microstructure on the attachment, spreading, orientations and growth of fibroblast and osteoblast cell types were examined.[18,19] The most significant result of these studies was the development of a series of microgrooved surfaces with groove widths and depths in the range of 6 to 12 μm. These tissue engineered surfaces, it is hypothesized, encourage soft tissue and bone attachment by controlling cell attachment, proliferation, and differentiation, and allow stress transfer from the implant to the supporting bone with significant compression and tension stress transfer to the crestal bone. The presence of these topographies results in changes in cytoskeletal structure, stimulation of tyrosine phosphorylation, and expression of m-RNA for fibronectin.[20]

These surfaces were found to optimally control orientation of cells, prevent cell migration perpendicular to the microgrooves, and substantially inhibit fibroblast growth by inhibition of cell spreading. Specifically, 12-μm grooves showed the best potential for inhibition of fibrous tissue growth relative to bone cell growth, and 8-μm grooves showed the most effective inhibition of epithelial cell migration across the grooves; in effect, acting as a migration barrier. In a separate series of experiments, these surfaces were also found to directionally inhibit migration of epithelial cells.[19]

In the above-noted *in vivo* study, bone and soft tissue responses to these experimental surfaces and to blast-roughened surfaces of the same metal composition were examined in a canine implantable chamber model.[19] As expected, the laser-microgrooved surfaces showed less fibrous encapsulation and more extensive bone integration than their blast-roughened counterparts and a spatial orientation of bone microstructure. The surface microgrooves exhibited interdigitation with bone, resulting in a mechanical interlock whose integrity could be demonstrated in tensile testing.[20]

These *in vitro* and *in vivo* studies provided evidence that surface microtexturing may enhance osseointegration. Roughened surfaces allowed cell attachment but limited spread and migration. Ridge-groove widths in the order of magnitude of the cells themselves guided cell migration and orientation.[20] Microgrooved surfaces optimally restrict apical migration of fibroblast proliferation and spreading, allowing the slower growing osteoblasts to proliferate and migrate coronally along the implant collar. Stress transfer from the implant to the crestal bone interlocked through the microgrooved surface of the collar produces a stable crestal bone topography that may be less likely to show resorption during the initial year of function.[21–23] The purpose of this study was to further test this hypothesis, namely, that the bone interface can be enhanced qualitatively and quantitatively when laser microtexturing is applied to the implant collar in the dog model.

Materials and Methods

The LaserLok Silhouette implant (BioLok International, Deerfield Beach, FL) was used in these experiments. It is a tapered titanium alloy tapered screw-type dental implant, 8 mm in length and 3.75 mm in maximum diameter, with a surface-textured body and a 2-mm-high collar (Fig. 1a). Surface texturing (OsseoLok surface) was produced by air-blasting with apatitic blast medium (RBM) that creates a highly roughened surface that can be cleaned without acid etching (Fig. 1b, bottom). Technically, RBM blast media (tricalcium phosphate) was placed into a medium blaster in a blast chamber. After masking the laser machined collar, the threads of the implants were blasted and then measured using a profilometer (on a test plate) to provide a R_a value of 3.0 $\pm$ 0.5 μm.

The 2-mm collar of each control implant (Silhouette design without the LaserLok surface) was a simple machined surface, not textured (Fig. 1b, top). The collar of each experimental LaserLok implant (Fig. 2a) was prepared with 3 zones. The bottom 2 zones were laser micro textured with an Excimer laser applied through a large area mask. The lower 0.8 mm of the collar was textured with 12-μm microgrooves. The etch depth of these grooves was 10 $\pm$ 3 μm. The pitch for the 12 μm wide grooves was 24 μm $\pm$ 2 μm. The middle 0.7 mm of collar was microtextured with 8 μm wide grooves. The etch depth for these grooves was 4 $\pm$ 1 μm. The pitch for these grooves was 16 $\pm$ 1.6 μm. The upper 0.5 mm of the collar was left as machined. Blasted and laser machined implants were then ultrasonically cleaned and bathed in dilute nitric acid to remove residual blast media and passivate the Ti-6-4 titanium alloy before sterilization.



Fig. 1. a, Low-power light micrograph of experimental implant showing the tapered screw design and the 2-mm collar. The collar is divided into 3 zones, 2 of which are laser-microgrooved. b, Scanning electron micrograph of machined (upper part of figure) and textured (lower part of figure) surfaces of implant. The textured region is the OsseoLok surface. Bar = 10 μm.

Fig. 2. a, Scanning electron micrograph of an experimental implant with a 2-mm collar. The collar has 3 zones, of which the lower 2 are laser-micromachined with microgrooves. b, Scanning electron micrograph of the 12-μm microgrooves (MG12, lower zone) and microtextured OsseoLok surface (upper zone). Bar = 100 μm.

Implant Placement

Six mongrel dogs 15 to 20 kg in weight were anesthetized and intu-

Copyright © Lippincott Williams & Wilkins. Unauthorized reproduction of this article is prohibited.

bated for the surgical removal of the mandibular premolars and first molar bilaterally. After a 2-month healing period, each dog was again anesthetized and intubated, and 3 endosseous titanium implants 8 mm long by 3.75 mm wide were inserted into the areas of healed bone where the teeth had been removed on each side of the mandible following the standard protocol. All drilling was conducted at low speed with irrigation. Self-tapping implants were threaded into the bone, with the crestal bone level located at approximately the middle of the implant collar. One side of each mandible received 3 implants with the laser-micromachined collar configuration (experimental implants). The other side received control implants with unmodified machined collars. The mucosa was sutured to cover the implants and allowed to heal.

After 3 months of healing, 5 of the 6 animals were each anesthetized and intubated. The mucosa over the crest of the jaw overlying the implants was incised and the implants were exposed. The sixth animal was a negative control. Impressions were taken for a bar prosthesis in 4 of the 5 animals, and healing caps were placed and healing abutments were placed. Two weeks later each animal was again anesthetized and intubated, and a bar prosthesis connecting the 3 implants on each side was placed in 4 of the 5 animals. The fifth animal was killed.

Animal Killing and Implant Retrieval

One animal that was uncovered but did not receive a prosthesis was killed at the time of prosthesis insertion (3 months after implant placement), 2 were killed at 12 weeks after prostheses insertion (6 months after implant placement, 3 months after loading), and 2 were killed at 24 weeks after insertion of the prostheses (9 months after implant placement, 6 months after loading). The sixth dog, serving as a negative control, which was not uncovered, was killed along with the 24-week animals. Gingival attachment sites, alveolar ridge heights, and relative amounts and types of tissue attachment to the implants were observed and recorded. Block sections were removed, preserved, and the implants and surrounding bone and soft tissue were embedded in polymethylmethacrylate for hard tissue histology and histomorphometry according to standard protocols.

Histopathology

Specimens intended for light histology were placed in a container with formalin. After 2 weeks, specimens were dehydrated by immersing the tissue in a series of ethanol solutions ranging from 40% to 100%. After dehydration, specimens were immersed in clearing agent and embedded in a hard polymethylmethacrylate solution consisting of methylmethacrylate and benzoyl peroxide, in which the monomer polymerizes with increasing concentrations of catalyst (benzoyl peroxide). When polymerization was complete, blocks were trimmed with a hacksaw to minimum size and then cut with a low-speed carbon/cubic boron nitrite wafering blade (Beuhler Isomet, Beuhler, Lake Bluff, IL) with 70% ethanol as a lubricant. Samples were sectioned parallel to the long axis of the implant to provide specimens approximately 0.5 mm in thickness, rinsed in 100% ethanol, glued cut side down with cyanoacrylate adhesive onto clear acrylic slides, and ground down to a final thickness of 100 μm. Polished specimens were stained with Stevenel's blue and Van Gieson's picrofuchsin to render mineralized bone red or reddish brown and soft tissues blue or blue-green. Histologic slides were examined in transmitted incandescent light for evaluation of cellular detail, tissue organization, and collagen alignment. Photomicrographs were taken using a light microscope with a 35 mm camera attachment.

Electron Microscopy

Selected polymer blocks were polished to 600 grit or higher, carbon-coated using a Denton Vacuum evaporation system (Denton Vacuum USA, Moorestown, NJ), and examined using either a Hitachi S2500 scanning electron microscope or a JEOL 5400 scanning electron microscope in backscattered electron imaging mode to image the bone-implant interface without disturbing it by thin-sectioning and polishing. In some cases, multiple images were combined to produce large-area, low-magnification collages.

Histomorphometric Analysis

Histologic sections were digitized using a calibrated Nikon Microphot-FX transmitted light microscope, an Optronics digital video camera system, and BioQuant (version 3.50.6, BioQuant Imaging, Memphis, TN) PC software. Bone height, expressed as a percentage of collar height, was used to compare local bone response with control and experimental surfaces along the implant collars at each time period.

Nonparametric Histomorphometry

Histologic sections were evaluated using nonparametric histomorphometric methods to qualitatively determine bone and soft tissue response to specific regions of the implant collar. Four scores were recorded for each image (A–D).

A. *Osteoclast activity:* 0 = no osteoclast activity; 1 = low numbers of active osteoclasts; 2 = moderate osteoclast activity; 3 = rampant activity and jagged edged bone surfaces.
B. *Saucerization:* 0 = bone at the implant interface showing a level configuration; 1 = bone at the implant surface exhibiting a downward-sloping interface, indicating bone resorption.
C. *Bone upgrowth:* 0 = level bone height at interface the same or lower than at a distance from the interface; 1 = higher bone apposition at the collar interface when compared to bone height at a distance from the interface.
D. *Soft tissue downgrowth:* 0 = no soft tissue between the bone and implant collar (direct bone apposition at the collar); 1 = soft tissue in contact with the implant collar and between the bone and implant collar.

In many cases multiple histologic samples were processed from a single implant site, representing different portions of the implant interface (buccal, lingual, *etc*). In these cases, where multiple histologic specimens represent a single implant, the data from those sections was averaged to produce numbers representing that single

Copyright © Lippincott Williams & Wilkins. Unauthorized reproduction of this article is prohibited.

Table 1. Nonparametric Histomorphometric Analysis Data (±Standard Error)

	Osteoclastic Activity	Saucerization	Bone Upgrowth	Soft Tissue Downgrowth
3-mo loaded specimens				
Control/smooth (8 sections from 3 implants)	1.50 ± 0.29	0.92 ± 0.05	0 ± 0	0.83 ± 0.10
Laser micromachined (6 sections from 4 implants)	0.88 ± 0.16	0.50 ± 0.10	0 ± 0	0.25 ± 0.13
6-mo loaded specimens				
Control/smooth (12 interfaces)	1.75 ± 0.22	0.55 ± 0.07	0.15 ± 0.04	0.55 ± 0.07
Laser-micromachined (14 interfaces)	1.30 ± 0.17	0.22 ± 0.04	0.90 ± 0.04	0 ± 0

The 3-months and 9-months unloaded specimens were not included in evaluations.



Fig. 3. Scanning electron photomicrograph (backscattered electron imaging mode) of bone integration of an experimental implant at 3 months(uncovering). Left: Overview (collage) of several images showing bone integration of the body of the implant and direct bone integration of the laser-micromachined collar. Right: Higher-magnification image of bone integration of the implant body. Thread pitch = 1 mm.

implant. For this reason, Table 1 indicates the numbers of sections and implants for each data entry, and the averages and standard errors are based on the implant numbers rather than section numbers.

Results

Animal Model

Surgeries and postoperative recovery of all animals were uneventful. At the times of uncovering, restoration, and killing, no significant clinical observations of infection or inflammation were noted.

Histologic and Histomorphometric Evaluation

Histologic Description

Specimens examined at uncovering of the implants (3 months after placement). Backscattered electron imaging and light histology from these implants showed evidence of early osseointegration. The textured surface of the implant body exhibited significant bone-implant contact at this time period which was 3 months after implant placement, at uncovering (Fig. 3). In most cases, bone density was lower around the apical portion of the implant, where the bone was trabecular in nature. Coronally, the bone density was higher, similar in some areas to cortical bone. Bone adjacent to the implant surface often showed signs of immaturity as evidenced by thin trabeculae and scalloping from osteoclast resorption, indicative of active remodeling.

Bone adjacent to the implant collars was relatively immature. Most of the laser-micromachined collars showed some regions of direct bone attachment, with mineralized bone evident within the depths of the microgrooves (Fig. 4). Microgrooved surfaces that were buried in soft tissue showed soft tissue cell and tissue elements within the microgrooves. All control implants with machined collars exhibited few regions of direct bone apposition, and all exhibited signs of soft tissue invasion of the interface (Fig. 5).

Specimens examined 3 and 6 months after loading. Histological evaluations of these specimens were similar: all specimens exhibited bone that was more mature than in the specimens examined at the time of uncovering, including the bone at the implant interface. Mature bone was observed at the interface with the roughened surface of the threads (Fig. 6a). Bone was consistently observed to directly attach to the laser-micromachined collars (Fig. 6b) and fully penetrate the depths of the grooves (Fig. 6c). Most implants at these time periods exhibited a more mature epithelial interface at the machined surface of the upper part of the collar of the implants (Fig. 7a). In some cases, the epithelial layer was observed to end in a burst of cells at the beginning of the laser-micromachined collar in a manner similar to that of the junctional epithelium observed adjacent to the tooth (Fig. 7a). Below this level a zone of connective tissue attachment was often observed between the epithelium and the attached bone (Fig. 7b). At the control (machined surface) collars some specimens showed direct bone contact, but most showed extensive connective tissue migration into the interface between the bone and implant surface (Fig. 7c).

Copyright © Lippincott Williams & Wilkins. Unauthorized reproduction of this article is prohibited.

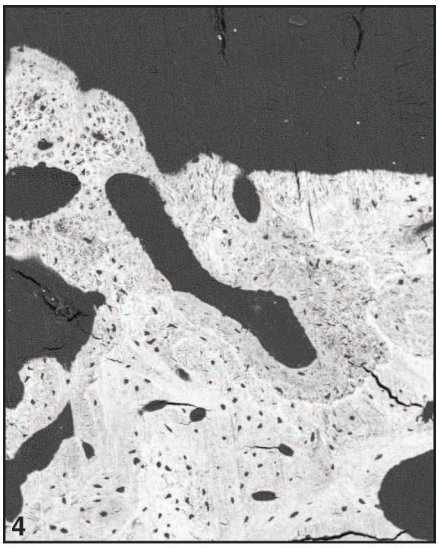

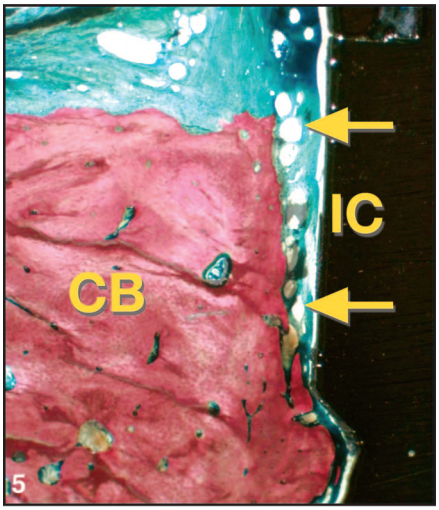

Fig. 4. Backscattered electron image of direct bone integration of the laser-micromachined portion of an experimental implant collar at 3 months (uncovering). The microgrooves in the lower portion of the implant are 12 μm in width (24-μm repeat spacing).

Fig. 5. Light photomicrograph of a control implant at 3 months (uncovering) showing soft tissue ingrowth (arrows) between the crestal bone (CB) and the implant collar (IC) and a lack of direct bone integration of the collar. Collar height = 2 mm.

Histomorphometric Evaluation

The histomorphometric analysis of bone height along the collars of smooth (control) and textured collar (laser-micromachined) implants indicated a general increase in bone height along the collar over time (Fig. 8). However, the bone adjacent to the laser microtextured collars showed an early, more rapid increase in bone height.

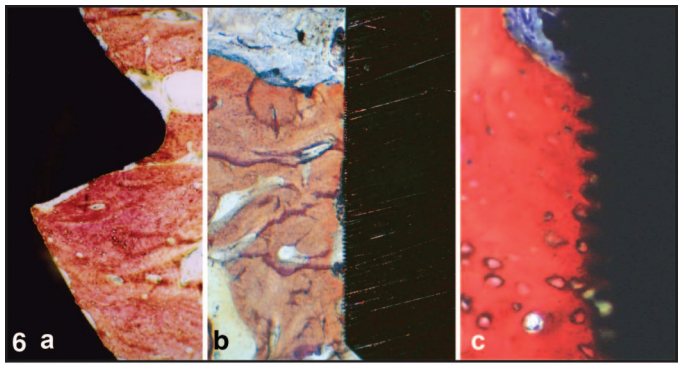

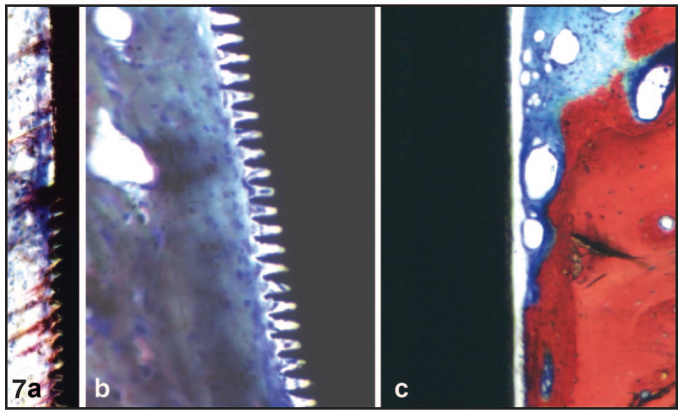

Fig. 6. Light photomicrographs of bone integration of the textured body (a) and laser-micromachined collars (b and c) of experimental implants at 3 months after loading. Direct, mature bone integration is observed at these interfaces.

Fig. 7. Light photomicrographs of epithelial and soft connective tissue interaction with experimental (a and b) and control (c) surfaces at 6 months (3 months after loading). An epithelial layer is seen in the upper portion of (a), which ends in a burst of epithelial cells that are attached at the edge of the laser-micromachined region (center of photo). The lower part of (a) and all of (b) show connective attachment to the laser-micromachined surfaces. c, Soft tissue downgrowth between the bone and implant interface in a control implant.

Nonparametric Histomorphological Evaluation

The histomorphometric features summarized in Table 1 represent a heuristic approach that is meant to summarize key features observed in the histologic specimens. Because of small animal and implant numbers used for analysis, no statistical analysis is attempted or reported here. The observations made here represent observed trends and are not meant to imply statistical significance. Of the key features of the histologic specimens observed at 3 and 6 months postloading, osteoclastic activity was lower in experimental (laser-micromachined) than in control implants (Table 1). Saucerization at the implant interface was greater at the control implant surfaces than at the laser-micromachined ones; this difference seemed to be greater for the specimens loaded for 6 months than those only loaded for 3 months. Bone upgrowth (an upward pattern of bone growth at the implant interface) did not differ between surfaces for both experimental and controls loaded for 3 months, but was greater in laser-micromachined implants than in control implants for specimens loaded for 6 months. Soft tissue downgrowth around the implant collar, a measure of lack of bone integration, was greater at control surfaces for both time periods, and the difference was greater in the 6 months than the 3 month samples.

Discussion

The results of this study in the dog model support the hypothesis that a patterned tissue-engineered surface on the implant collar can limit epithelial downgrowth, attach soft tissue and bone, and effectively create biologic width at a tissue engineered implant surface, Furthermore, long-term, the laser microtex-

Copyright © Lippincott Williams & Wilkins. Unauthorized reproduction of this article is prohibited.

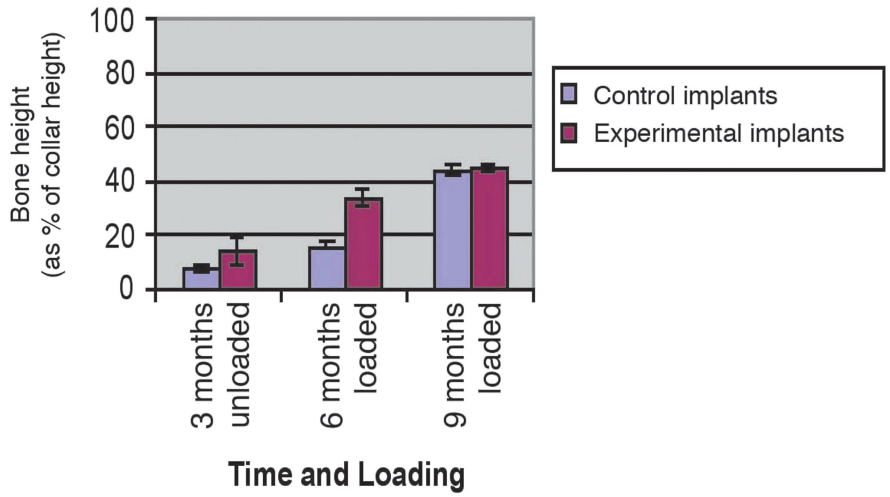

Fig. 8. Histomorphometric bone height in control (smooth) and experimental (laser-micromachined) implants at 3 (uncovering), 6 (3 months after loading), and 9 (6 months after loading) months.

tured collar seems to influence remodeling such that there is an improved quality to the bone adjacent to the implant. It might be further hypothesized that the cell types attached to the patterned surface would facilitate remodeling and development of mature, well mineralized bone.[23,24]

These results suggest that early osseointegration occurs more rapidly adjacent to implants with laser microtextured collars. With time, as the interface matures and remodels, the amount of bone contact along both the machined and laser microtextured collars becomes equivalent but the quality of the bone is still influenced by the early differences in the cell types populating the implant surface as shown in the histologic analysis above. Related studies suggest that in the presence of the microgrooves the osteoblasts change their morphology from a round to an oblong shape with pseudopodia that embrace the grooves. Production of extracellular matrix, initially a collagen stroma, which then is calcified, creates a mechanical lock between the bone and the implant. This allows a direct stress transfer from the implant to the bone.[25] Strain in the crestal bone results in intracellular production of nitrous oxide that stabilizes osteocytes, and prevents apoptosis and prostaglandin E_2, that attracts and causes differentiation of osteoblasts. Both of these processes result in bone of improved quality and quantity.[26]

Another group of issues that must be considered are the reproducibility, specificity, and cleanliness of the laser microtextured surface modification technique. The microgrooved surfaces in this study were produced using computer-controlled laser-micromachining. That is a significant advance over pre-existing surface-roughening technology. It results in a clean, reproducible surface microgeometry that can be applied to surfaces of most metal implants and other biomaterials as well. The technique is, moreover, precise and can be used regionally, in selected areas, to create specific microstructure organization and orientation. Other implant-textured systems employ nonspecific roughness in a range of sizes.[27] Although these may result in increases in bone apposition, the broad distribution of surface structure size may make them suboptimal.

Human studies, based on radiographic evidence, have reported dieback to the first thread of the implant.[28,29] However, most of these reports used implants with machined collars, similar to the control implants in this study.[30] More recent reports using textured surfaces suggested that the crestal bone can be maintained more coronal to the first thread along the collar.[31,32] These clinical results seem to be similar to the histological findings in this study; namely, that the presence of texturing along the collar results in a more stable osseous crest without dieback to the first thread. In either circumstance a biological width of 1 to 2 mm is established. The biological width, which has as its apical margin the crestal bone is composed of connective tissue and epithelium.[33] It may be that a tissue engineered surface which preferentially guides specific cell types to establish a biological width may result in a more stable hard and soft tissue interface; but this requires further investigation.

As noted previously the attachment of the osteoblasts to the microgrooved surface allows stress transfer from the implant to the surrounding bone.[33] Stress from occlusal loading, mandibular flexure, tongue, cheek and lip forces that load the implant-supported prosthesis, either a crown, bridge or overdenture are transferred through the implant to the implant-bone interface. Depending upon the load and direction of force, regions of the crestal bone may be either overloaded or stress shielded.[34] Frost, in the orthopedic model offered a range of strain, bone distortion, that will result in physiological remodeling. Strain of lesser magnitude will result in resorption and disuse atrophy. Strain of greater magnitude will result in overload, stress fractures and resorptive break down.[35] The reported dieback to the first thread has been hypothesized to be associated with excessive loading of the crestal bone.[36] It is of interest, however, that implant systems with roughened collars seem to resist dieback to the first thread.[27] This suggests that the major cause for this problem is stress shielding and disuse atrophy.

Soft tissue attachment to the implant collar has been problematic. The soft tissue architecture around dental implants has been dependent on the bone morphology alone. Teeth, unlike machined implants, have a connective tissue attachment to the root surface (Sharpey's fibers) and this provides further support for the gingival soft tissue.[15] The analogous structure for the implant is the collar. The connective tissue fiber bundles in the gingiva surrounding the implants have been reported to circle the implant neck.[25] This does not allow the implant collar to support the

Copyright © Lippincott Williams & Wilkins. Unauthorized reproduction of this article is prohibited.

soft-tissue in a manner similar to a tooth. Attachment of the soft tissue to the collar would provide greater soft tissue stability and predictability. This study provides evidence of limited epithelial downgrowth and soft tissue attachment to the laser microtextured collar and suggests that the microtexturing allows embedment of fibers and provides support for the soft tissue in an organized manner similar to the biologic width around the tooth. In addition, Chehroudi *et al*[33] has reported attachment of oblique fibers projecting outward, from a microgrooved collar. Evaluation of fibroblast cytoarchitecture suggests that similar to osteoblasts, fibroblasts flatten out, attach and orient to the microgrooves, and secrete collagen fibers that allow attachment between the collar area and the adjacent connective tissue.

Conclusion

In summary, laser microtexturing provides a new dimension to the implant-host interface permitting the use of tissue engineering principles to control tissue attachment and allow stress transfer that enables bone remodeling and attachment of collagen fibers to the implant surface to allow a more predictable soft tissue architecture. In previous work,[15,16] tissue culture and animal experiments were used to examine the effects of controlled microstructure on cell response and to establish design parameters for fabrication of controlled-micromachined titanium alloy surfaces. The results of this experiment support this thesis and help to establish the efficacy of applying laser-micromachined surfaces to the crestal interfacial regions of dental implants. Application of controlled, oriented, laser-microstructuring to dental implant collars represents a specific and effective means to control soft tissue integration, establish biologic width, and enhance bone growth adjacent to the critical crestal regions of dental implants. This may have significant implications for retention of bone, control of soft tissue aesthetics around implants, and long-term success of dental implants. Clinical studies are being conducted comparing these tissue-engineered surfaces to machined surface collars.

Disclosures

Dr. John Ricci claims to have a financial interest in BioLok, whose product LaserLok implant, is mentioned in this article. All other co-authors claim to have no financial interest in any company or any of the products mentioned in this article.

References

1. Albrektsson T, Wennerberg A. Oral implant surfaces. Part I—Review focusing on topographic and chemical properties of different surfaces in vivo responses to them. *Int J Prosthodont*. 2004;17:536-543.

2. Cooper L. A role for surface topography in creating and maintaining bone at titanium endosseous implants. *J Prosthet Dent*. 2000;84:522-534.

3. Quirynen M, Naert I, Van Steenberghe D. Fixture design and overload influence marginal bone loss and fixture success in the Branemark system. *Clin Oral Implants Res*. 1992;3:104-111.

4. Hoshaw SJ, Brunski JB, Cochran GVVB. Mechanical loading of Branemark implants affects interfacial bone modeling and remodeling. *Int J Oral Maxillofac Implants*. 1994;9:345-360.

5. Hermann JS, Buser D, Schenk RK, et al. Crestal bone changes around titanium implants. A histometric evaluation of unloaded, nonsubmerged and submerged implants in the canine mandible. *J Periodontal*. 2000;71:1412-1424.

6. Simmons CA, Megiud SA, Pilliar RM. Mechanical regulation of localized and appositional bone formation around bone-interfacing implants. *J Biomed Mater Res*. 2001;55:63-71.

7. Cox JF, Zarb GA. The longitudinal clinical efficacy of osseointegrated dental implants: A 3-year report. *Int J Oral Maxillofac Implants*. 1987;2:91-100.

8. Bidez MW, Misch CE. Force transfer in implant dentistry: Basic concepts and principles. *Oral Implantol*. 1992;18:264-274.

9. Kilamura E, Slegaroui R, Nomura S, et al. Biomechanical aspects of marginal bone resorption around osseointegrated implants: Consideration based in a three dimensional finite element analysis. *Clin Oral Implant Res*. 2004;15:401-412.

10. Isidor F. Histological evaluation of peri-implant bone at implants subjected to occlusal overload or plaque accumulation. *Clin Oral Implant Res*. 1997;8:1-9.

11. Bragger U, Pasquali L, Krnman KS. Remodeling of interdental alveolar bone after periodontal flap procedures assessed by means of computer-assisted densitometric image analysis. *J Cloin Perio*. 1988; 15:558-564.

12. Sennerby L, Roos J. Surgical determinants of clinical success of osseointegrated oral implants. A review of the literature. *Int J Prosthodont*. 1998;11:408-420.

13. Quirynen M, Van Steenburghe D. Bacterial colonization of the internal part of two-stage implants. An in vivo study. *Clin Oral Implants Res*. 1993;4:158-161.

14. Broggini M, McManus LM, Hermann JS, et al. Persistent acute inflammation at the implant-abutment interface. *J Dent Res*. 2003;82:232-237.

15. Garguilo A, Wentz F, Orban B. Dimensions and relations of the dentogingival function in humans. *J Periodontol*. 1961;32:261-268.

16. Hermann JS, Buser D, Schenk RK, et al. Biologic width around one- and two-piece titanium implant. *Clin Oral Implants Res*. 2001;12:559-571.

17. Curtis A, Wilkinson C. Topographical control of cells. *Biomaterials*. 1997;18: 1573-1583.

18. Ricci J, Charvet J, Frenkel SR, et al. Response to laser microtextured surfaces. In: Davies J, ed. *Bone Engineering*. 2nd ed. Toronto: em squared incorporated; 2000: 282-294.

19. Frenkel SR, Simon J, Alexander H, et al. Osseointegration on metallic implant surfaces: Effects of microgeometry and growth factor treatment. *J Biomed Mater Res*. 2002;63:706-713.

20. Clark P, Connolly P, Curtis ASG, et al. Cell guidance by ultrafine topography in vitro. *J Cell Sci*. 1991;99:73-77.

21. Simmons CA, Meguid SA, Pilliar RM. Differences in osseointegration rate due to implant surface geometry can be explained by local tissue strains. *J Orthop Res*. 2001;19:187-194.

22. Britland S, Clark P, Connolly P, et al. Micro patterned substratum adhesiveness: A model for morphogenic cues controlling cell behavior. *Exp Cell Res*. 1992;198:124-129.

23. Carter DR, Giori NJ. Effect of mechanical stress on tissue differentiation in the bony implant bed. In: Davies JE, ed. *The Bone—Biomaterial Interface*. Toronto: University of Toronto Press; 1991:367-379.

24. DeLeonardis D, Garg AK, Pecora GE, et al. Osseointegration of rough acid-etched implants: 5-year follow-up of 100 minimatic implants. *Int J Oral Maxillofac Implants*. 1999;14:384-391.

25. Hansson S. The dental implant meets bone—A clash of two paradigms. *Appl Osseointegration Res*. 2006;5:5-17.

26. Zaman G, Pitsillides AA, Rawlinson SC, et al. Mechanical strain stimulates nitric oxide production by rapid activation of

Copyright © Lippincott Williams & Wilkins. Unauthorized reproduction of this article is prohibited.

endothelial nitric oxide synthase in osteocytes. *J Bone Miner Res*. 1999;14:1123-1131.

27. Oxby G, Lindgvist J, Nilsson P. Early loading of AstraTech Osseospeed implants placed in thin alveolar ridges and fresh extraction sockets. *Appl Osseointegration Res*. 2006;5:68-72.

28. Misch CE, Qu M, Bidez MW. Mechanical properties of trabecular bone in the human mandible: Implications of dental implant treatment planning and surgical placement. *J Oral Maxillofac Surg*. 1999; 57:700-706.

29. Zechner W, Trinki N, Watzek G, et al. Radiographic follow-up of per-implant bone loss around machined-surface and rough-surfaced interforaminal implants in the mandible functionally loaded for 3 to 7 years. *Int J Oral Maxillofac Implants*. 2004; 19:216-222.

30. Adell R, Lekhol U, Rockler B, et al. A 15-year study of osseointegrated implants in the treatment of the edentulous jaw. *Int J Oral Surg*. 1981;6:387-416.

31. Wiskott HW, Belser UC. Lack of integration of smooth titanium surfaces: A workup hypothesis based on strains generated in the surrounding bone. *Clin Oral Implant Res*. 1999;10:429-444.

32. Schierno G, Ramieri G, Cortese M, et al. Organization of the connective tissue barrier around long-term loaded implant abutments in man. *Clin Oral Implant Res*. 2002;13:460-464.

33. Chehroudi B, Gould T, Brunette DM. The role of connective tissue in inhibiting epithelial downgrowth on titanium coated percutaneous implants. *J Biomed Mater Res*. 1992;26:493-515.

34. Miyata T, Kobayashi Y, Araki H, et al. The influence of controlled occlusal overload on perimplant tissue. A histologic study in monkeys. *Int J Oral Maxillofac Implants*. 1998;13:677-683.

35. Frost HM. Wolff's law and bone's structural adaptations to mechanical usage: An overview for clinicians. *Angle Orthod*. 1994;64:175-188.

36. Miyata T, Kobayashi Y, Araki H, et al. The influence of controlled occlusal overload on peri-implant tissue. Part 3: A histologic study in monkeys. *Int J Oral Maxillofac Implants*. 2000;15:425-431.

Reprint requests and correspondence to:
Saul Weiner, DDS
Department of Restorative Dentistry
New Jersey Dental School
110 Bergen Street, P.O. Box 1709
Newark, NJ 07101-1709
Fax: 973-972-0370
E-mail: weiner@umdnj.edu

ID Abstract Translations

GERMAN / DEUTSCH

AUTOR(EN): Saul Weiner, DDS, Joshua Simon, MS, David S. Ehrenberg, DDS, MS, Barry Zweig, DDS, John L. Ricci, PhD. *Korrespondenz an: Saul Weiner, DDS, zahnmedizinische Fachhochschule New Jersey (New Jersey Dental School), 110 Bergen Street, Postfach 1709 (P.O. Box 1709), Newark, NJ 07101-1709. Fax: 973-972-0370, e-Mail: weiner@umdnj.edu*

Auswirkungen von Laser-Mikrotextur-Bändern auf Kammknochenebenen von Zahnimplantaten

ZUSAMMENFASSUNG: Zielsetzung: Die vorliegende Studie zielte darauf ab, die Reaktionen des Kammknochengewebes, Bindegewebes sowie der Epithelzellen auf ein Laser-Mikrotextur-Band im Vergleich zu einem maschinell hergestellten Band im Hundemodell zu untersuchen und zu beurteilen. ***Materialien und Methoden:*** Sechs Mischlingshunden wurden die Prämolaren sowie ersten Dentes molares im Unterkiefer gezogen und nach erfolgter Heilung durch BioLok-Implantate von 4 × 8 mm ersetzt. Bei jedem Hund wurden auf der einen Seite des Unterkiefers drei Kontrollimplantate eingepflanzt sowie drei Versuchsimplantate mit Laser-Mikrotextur auf der gegenüber liegenden Seite. Nach drei Monaten wurde einer der Hunde eingeschläfert. Bei vier der Hunde wurden Brücken auf die Implantate aufgebracht. Der sechste Hund wurde als Negativkontrolle für die Dauer des Versuchs eingesetzt. Zwei der Hunde wurden drei Monate nach erfolgter Belastung eingeschläfert, weitere zwei nach sechs Monaten ebenso wie das als negative und damit unbelastet gebliebene Kontrolltier. Histologie, EM und histomorphometrische Analysen wurden an den aus den Blockabschnitten des Unterkiefers, die die Implantate enthielten, vorgenommen. ***Ergebnisse:*** Ursprünglich wiesen die Versuchsimplantate einen größeren Knochenkontakt im Bereich des Bands auf. Nach einem gewissen Zeitraum aber glichen sich die Knochengewebshöhen an den Kontroll- sowie den Versuchsbändern aneinander an. Allerdings verfügten die Kontrollen über ein größeres Tiefenwachstum im Weichgewebsbereich, eine größere osteoklastische Aktivität und eine gesteigerte Flachgestaltung im Vergleich zu den an die Versuchsimplantate angrenzenden Bereiche. Es war eine engere Anbindung des Knochengewebes an die Laser-Mikrotextur-Bänder feststellbar. ***Schlussfolgerung:*** Die Verwendung von Gewebsbearbeiteten Bändern mit Mikrofurchungen scheint den Halt von Knochen und Weichgewebe entlang der Bänder zu begünstigen und die Entwicklung einer biologischen Weite zu erleichtern.

SCHLÜSSELWÖRTER: Implantatband, Gewebsbearbeitung, Laser-Mikrotextur, biologische Weite, Kammknochen

SPANISH / ESPAÑOL

AUTOR(ES): Saul Weiner, DDS, Joshua Simon, MS, David S. Ehrenberg, DDS, MS, Barry Zweig, DDS, John L. Ricci, PhD. *Correspondencia a: Saul Weiner, DDS, New Jersey Dental School, 110 Bergen Street, P.O. Box 1709, Newark, NJ 07101-1709. Fax: 973-972-0370, Correo electrónico: weiner@umdnj.edu*

Los efectos de los collares con microtextura por láser en los niveles de hueso crestal de los implantes dentales

ABSTRACTO: Propósito: El propósito de este estudio fue examinar el hueso crestal, tejido conectivo y respuesta de la célula epitelial a un collar con microtextura por láser com-

Copyright © Lippincott Williams & Wilkins. Unauthorized reproduction of this article is prohibited.

parado con un collar hecho a máquina en un modelo en perros. ***Materiales y Métodos:*** Se extrajeron los premolares de la mandíbula y el primer molar de perros cruzados y luego de su cicatrización fueron reemplazados con implantes BioLok de 4 × 8 mm. Cada perro recibió 3 implantes dentales de control colocados en un costado de la mandíbula y 3 implantes experimentales, con microtextura por láser, colocados contralateralmente. Después de 3 meses, se sacrificó un perro. Se colocaron puentes en los implantes de cuatro perros. El sexto perro se usó como control negativo durante el experimento. Dos de los perros fueron sacrificados tres meses después de la carga, uno de los perros fue sacrificado 6 meses después de la carga igual que el de control negativo (sin carga). Se realizaron análisis histológicos, EM e histomorfométricos en secciones histológicas obtenidas de secciones de la mandíbula que contenían a los implantes. ***Resultados:*** Inicialmente, los implantes experimentales demostraron una mayor fusión con el hueso alrededor del collar. Con el tiempo, las alturas del hueso a lo largo de los collares de control y experimentales fueron las mismas. Sin embargo, los controles tenían más tejido blando en el crecimiento hacia abajo, mayor actividad osteoclástica y mayor saucerización comparado con los sitios adyacentes a los implantes experimentales. Se logró una adaptación más estrecha del hueso a los collares microtexturizados por láser. ***Conclusión:*** El uso de collares fabricados con tejido con microranuras parece promover la fusión del hueso y del tejido blando a lo largo del collar y facilitar el desarrollo del ancho biológico.

PALABRAS CLAVES: Collar del implante, ingeniería de tejidos, microtextura por láser, ancho biológico, hueso crestal

PORTUGUESE / PORTUGUÊS

AUTOR(ES): Saul Weiner, Cirurgião-Dentista, Joshua Simon, Mestre em Ciência, David S. Ehrenberg, Cirurgião-Dentista, Mestre em Ciência, Barry Zweig Cirurgião-Dentista, John L. Ricci, PhD. *Correspondência para: Saul Weiner, DDS, New Jersey Dental School, 110 Bergen Street, P.O. Box 1709, Newark, NJ 07101-1709. Fax: 973-972-0370, e-mail: weiner@umdnj.edu*

Os Efeitos de Anéis Microtexturados a Laser sobre os Níveis de Osso da Crista de Implantes Dentários

RESUMO: Objetivo: O objetivo deste estudo era examinar o osso da crista, o tecido conjuntivo e a resposta da célula epitelial a um anel microtexturado a laser em comparação com um anel usinado, no modelo cachorro. Materiais e Métodos: Seis vira-latas tiveram pré-molares e primeiros molares extraídos e após a cura foram substituídos por implantes BioLok 4 × 8 mm. Cada cachorro teve 3 implantes de controle colocados num lado da mandíbula e 3 implantes experimentais e microtexturados a laser colocados contralateralmente. Após 3 meses, um cachorro foi sacrificado. Pontes foram colocadas nos implantes de 4 dos cachorros. O sexto cachorro serviu como controle negativo pela duração do experimento. Dois dos cachorros foram sacrificados três meses após a carga, dos cachorros foram sacrificados 6 meses após a carga, já que era o controle negativo (não-carregado). A análise histológica, de EM e histomorfométrica foi feita em seções histológicas obtidas de seções em bloco da mandíbula contendo os implantes. ***Resultados:*** Inicialmente, os implantes experimentais mostraram maior encaixe do osso ao longo do anel. Com o tempo, as alturas do osso ao longo dos anéis de controle e experimentais ficaram equivalentes. Contudo, os controles tinham mais invasão de tecido mole, maior atividade osteoclástica e craterização aumentada em comparação com locais adjacentes a implantes experimentais. Houve adaptação mais completa do osso aos anéis microtexturados a laser. ***Conclusão:*** O uso de anéis de tecido usinado com micro-ranhuras parece promover o encaixe do osso e do tecido mole ao longo do anel e facilitar o desenvolvimento de uma largura biológica.

PALAVRAS-CHAVE: Anel de implante, usinagem de tecido, microtexturização de tecido, largura biológica, osso da crista.

RUSSIAN / РУССКИЙ

АВТОРЫ: Saul Weiner, доктор стоматологии, Joshua Simon, магистр естественных наук, David S. Ehrenberg, доктор стоматологии, магистр естественных наук, Barry Zweig, доктор стоматологии, John L. Ricci, доктор философии. *Адрес для корреспонденции: Saul Weiner, DDS, New Jersey Dental School, 110 Bergen Street, P.O. Box 1709, Newark, NJ 07101-1709. Адрес для электронной почты: weiner@umdnj.edu, Факс: 973-972-0370*

Воздействие шеек имплантатов, микротекстурированных лазером, на высоту кости альвеолярного гребня зубных имплантатов

РЕЗЮМЕ. **Цель:** Цель этого исследования – изучить реакцию кости альвеолярного гребня, соединительной ткани и эпителиальных клеток на шейку имплантата, микротекстурированную лазером, в сравнении с полированной шейкой имплантата, на примере собак. **Материалы и методы:** У шести дворняжек были удалены нижнечелюстные премоляры и первые моляры, а после заживления, они были заменены имплантатами BioLok размером 4 x 8 мм. Каждой собаке установили 3 контрольных имплантата на одной стороне нижней челюсти и 3 экспериментальных имплантата, микротекстурированных лазером, на противоположной стороне. Спустя три месяца одна собака была умерщвлена. На имплантаты четырех собак были поставлены мосты. Шестая собака служила в качестве контрольного экземпляра в течение всего эксперимента. Спустя три месяца после нагрузки им-

Copyright © Lippincott Williams & Wilkins. Unauthorized reproduction of this article is prohibited.

плантатов две собаки были умерщвлены, собаки были умерщвлены шесть месяцев спустя после нагрузки имплантатов, будучи использованы в качестве контрольных экземпляров (без нагрузки имплантатов). Гистологические срезы, полученные из блочных участков нижней челюсти, содержащих имплантаты, были подвергнуты гистологическому, электронномикроскопическому и гистоморфометрическому исследованию. **Результаты:** На начальном этапе экспериментальные имплантаты продемонстрировали более крепкое сцепление имплантата с костью вдоль шейки имплантата. Со временем высота кости вдоль контрольных и экспериментальных шеек имплантатов стала одинаковой. Однако на контрольных участках было отмечено снижение роста мягкой ткани, более высокая остеокластическая активность и усиленное формирование блюдцеобразного углубления по сравнению с участками, примыкающими к экспериментальным имплантатам. Наблюдалась более тесная адаптация кости к шейкам имплантатов, микротекстурированных лазером. **Вывод:** Использование шеек имплантатов с обработанной тканью с прорезанием микропазов способствует сцеплению имплантата с костью и мягкой тканью вдоль шейки имплантата и росту биологической ширины.

КЛЮЧЕВЫЕ СЛОВА: Шейка имплантата, технология обработки тканей, лазерное микротекстурирование, биологическая ширина, кость альвеолярного гребня.

TURKISH / TÜRKÇE

YAZARLAR: Saul Weiner, DDS, Joshua Simon, MS, David S. Ehrenberg, DDS, MS, Barry Zweig, DDS, John L. Ricci, PhD. *Yazışma için: Saul Weiner, DDS, New Jersey Dental School, 110 Bergen Street, P.O. Box 1709, Newark, NJ 07101-1709 ABD. Faks: 973-972-0370, e-posta: weiner@umdnj.edu*

Dental İmplantların Kret Kemik Düzeyleri Üzerinde Lazerle Mikrotekstüre Edilmiş Çemberlerin Etkileri

ÖZET: Amaç: Bu çalışmanın amacı köpek modelinde, lazerli mikrotekstüre çember ile makinede yapılmış çemberi karşılaştırarak kret kemiği, bağ dokusu ve epitel hücreden alınan yanıtı incelemekti. ***Gereç ve Yöntem:*** Altı melez köpeğin mandibular premolar ve birinci molar dişleri çekildi. İyileşme sonrasında yerlerine 4 x 8 mm boyutlarında BioLok implantları yerleştirildi. Köpeklerin her birinde mandibulanın bir tarafında 3 kontrol implantı ve kontralateral konumda da 3 adet deneysel, lazerle mikrotekstüre edilmiş (yivlenmiş) implant yerleştirildi. Üç ay sonra köpeklerden birinin yaşamına son verildi. Köpeklerin dördünde bulunan implantlarda köprü monte edildi. Deney boyunca altıncı köpek negatif kontrol işlevi gördü. Yüklemeden üç ay sonra iki köpeğin yaşamına son verildi. Geri kalan köpekler ile negatif kontrol (yükleme yapılmayan) köpeğin yaşamına yüklemeden 6 ay sonra son verildi. Mandibuladan alınan ve implantı içeren bloklardan elde edilen histolojik bölümlerde histoloji, EM ve histomorfometrik analiz yapıldı. ***Bulgular:*** İlk önce, deneysel implantlarda çember boyunca daha büyük kemik bağlantısı görüldü. Zamanla, kontrol ve deneysel çemberler boyunca izlenen kemik yüksekliği eşitti. Ancak, deneysel implantların yanındaki yerlere nazaran kontrollerde daha fazla yumuşak doku aşağı büyümesi (downgrowth), daha fazla osteoklastik aktivite ve artmış tabaklaşma (saucerization) vardı. Lazerle mikroyivlenmiş çemberlere daha yakından kemik adaptasyonu izlendi. ***Sonuç:*** Dokudan mühendisliği yapılmış ve mikro yivlere sahip çemberler, çember boyunca kemik ve yumuşak doku bağlantısını arttırmakta ve biyolojik genişliğin gelişmesini kolaylaştırmaktadır.

ANAHTAR KELİMELER: İmplant çemberi, doku mühendisliği, lazerle mikrotekstüre etmek, biyolojik genişlik, kret kemiği

Copyright © Lippincott Williams & Wilkins. Unauthorized reproduction of this article is prohibited.

JAPANESE / 日本語

デンタルインプラント歯槽頂部骨レベルにおけるレーザー•マイクロテクスチャード•カラーの効果

共同研究者氏名: サウル•ワイナー（Saul Weiner）DDS, ジョシュア•サイモン（Joshua Simon）MS, デヴィッド•S•アーレンバーグ（David S. Ehrenberg）DDS, MS, バリー•ズワイグ（Barry Zweig）DDS, ジョン•L•リッチ（John L. Ricci）PhD.

研究概要:
目的: 当研究はイヌの実験モデルで、 歯槽頂部骨および接続組織と上皮細胞に影響するレーザー•マイクロテクスチャードカラー対マシーンドカラーの反応比較調査を目的とした。

研究素材と方法: 雑種犬6匹の下顎小臼歯と第一臼歯を抜歯し、治癒後4 x 8 mmの BioLokインプラントを埋入した。それぞれのイヌの下顎骨片側に3本のコントロールインプラント、反対側面には3本の実験用レーザー•マイクロテクスチャードインプラントを埋入した。3ヶ月後1匹を殺処分した。4匹のイヌのインプラントにはブリッジを装着し、6匹目は実験期間中ネガティブコントロールの役割を果たした。負荷3ヶ月後に2匹を殺処分した。負荷6ヶ月後にはネガティブ（負荷無し）コントロールの1匹も同時に殺処分した。インプラントを埋入した下顎骨ブロックセクションから採取した組織部分を組織学、エナメルマトリックス（EM）、組織計測学の面で分析した。

結果: 初期には実験用インプラントはカラーにそって比較的多量の骨付着が見られたが、時間経過につれコントロールと実験用カラーにそった骨高径は等価値を示した。ただしコントロールでは実験用インプラントに隣接した部位と比較して多分な軟組織下方成長と破骨細胞活動、そして皿状陥凹（saucerization）増加が確認された。またレーザー•マイクロテクスチャードカラーでは比較的密接度の高い骨適合が見られた。

結果: マイクログルービング付組織工学設計カラーの使用はカラーにそった骨と軟組織付着を促進し、明らかに生体原理開発を助成する。

キーワード: インプラントカラー, 組織工学, レーザー•マイクロテクスチャリング, 生体原理（biological width), 歯槽頂部骨.

ご質問の宛先: Saul Weiner, DDS, New Jersey Dental School, 110 Bergen Street, P.O. Box 1709, Newark, NJ 07101-1709.
電子メール: weiner@umdnj.edu FAX: 973-972-0370

CHINESE / 中国語

牙科植體骨脊層雷射細質紋理牙冠的效果

作者：Saul Weiner DDS；Joshua Simon MS；David S. Ehrenberg DDS, MS；Barry Zweig DDS；John L. Ricci PhD.

摘要：
目的：本研究透過狗模型比較機械製牙冠，目的是檢查骨脊、結締組織及上皮細胞對雷射細質紋理牙冠的反應。

資料與方法：六隻混血狗拔除下顎前臼齒和第一臼齒，並於癒合後放入 4X8 mm 的 BioLok 植體。每隻狗有 3 顆控制植體置入一邊下頷，還有 3 顆雷射細質紋理的實驗植體置入對側。3 個月後，犧牲其中一隻狗。將牙橋放入 4 隻狗的植體上。第六隻狗則做為實驗期間的負面控制。載入後三個月再犧牲兩隻狗，載入六個月後再犧牲其中x 隻狗，作為負面控制 (未載入)。將包含植體的下頷的塊狀骨切下的組織學切片進行組織學、EM 及組織形態學分析。

Copyright © Lippincott Williams & Wilkins. Unauthorized reproduction of this article is prohibited.

結果：實驗植體剛開始沿著牙冠出現較大的骨附連，一段時間後，控制和實驗的牙冠的骨質高度相等。然而，和鄰近實驗植體的部位比較，控制出現較多軟組織向根端生長、較大的破骨細胞活動以及更多的造碟術。雷射細質紋理牙冠有較接近的骨適應性。

結論：利用具有微溝槽的組織工程牙冠似乎會促進沿著牙冠的骨質及軟組織附連，讓生物寬度的發展更容易。

關鍵字：植體頸部/牙冠、組織工程、雷射細質紋理、生物寬度、骨脊

通訊方式：Saul Weiner, DDS, New Jersey Dental School, 110 Bergen Street, P.O. Box 1709, Newark, NJ 07101-1709.
電郵信箱：weiner@umdnj.edu　　傳真：973-972-0370

KOREAN / 한국어

치조정골을 덮는 레이저 미세표면 처리된 임플란트 칼라(Laser Microtextured Collars)의 효과

저자: 사울 와이너(Saul Weiner), 구강외과 의사(DDS), 조슈아 사이몬(Joshua Simon), 이학석사(MS), 데이비드 S. 에렌베르크(David S. Ehrenberg), 구강외과 의사(DDS), 이학석사(MS), 베리 츠바이크(Barry Zweig), 구강외과 의사(DDS), 존 L. 리치(John L. Ricci), 이학박사(PhD).

초록:
목적: 본 연구의 목적은 규격화된 칼라 (machined collar)와 비교한 레이저 미세표면 칼라에 대한 성견의 치조정골, 결합 조직 및 상피 세포의 반응을 검사하기 위함에 있다.

재료 및 방법: 6마리의 잡종견을 대상으로 하악골의 소구치와 제1대 구치를 발치하고 치료 후 4 ′ 8 mm의 바이오록(BioLok) 임플란트를 식립하였다. 각 실험견의 한 쪽 하악에 3개의 임플란트 대조군을 식립하였고 반대쪽 하악에 3개의 레이저 미세표면 임플란트 실험군을 식립하였다. 3개월 후, 실험견 한 마리가 죽었다. 4마리 실험견들의 임플란트에 치교를 식립하였다. 6 번째 실험견은 실험 기간 동안 음성 대조군 역할을 했다. 로딩 3개월 후 실험견 두 마리가 죽었고 로딩 6개월 후 죽은 실험견들도 음성 대조군(로딩되지 않은)이었다. 임플란트가 식립된 하악 블록 부위로부터 얻어진 조직학적 부위에 조직학, EM 및 조직형태계량 분석이 이루어졌다.

결과: 실험 초기에는 임플란트 실험군이 칼라에 더 큰 골 부착 경향을 보였다. 그러나 시간이 경과할수록 대조군 및 실험군 칼라의 골 높이가 동등해졌고, 대조군에서 더 부드러운 조직 성장을 보일수록 임플란트 실험군에 인접한 부위와 비교하여 더 활발한 파골 세포의 활동과 증가된 배형성(saucerization)을 보였다. 즉 뼈는 레이저 미세표면 칼라에 더 높은 적응을 보였다.

결론: 미세한 홈이 난 조직 공학형 칼라의 사용은 칼라에 뼈와 연조직 부착을 활성화하고 생물학적 폭경의 발달을 촉진시킨다.

키워드: 임플란트 칼라, 조직 공학, 레이저 미세표면, 생물학적 폭경, 치조정골

연락처: 사울 와이너(Saul Weiner), 구강외과 의사(DDS), New Jersey Dental School
주소: 110 Bergen Street, P.O. Box 1709, Newark, NJ 07101-1709.
이메일: Email: weiner@umdnj.edu　　팩스: 973-972-0370

Copyright © Lippincott Williams & Wilkins. Unauthorized reproduction of this article is prohibited.