PRACTICAL PROCEDURES & AESTHETIC DENTISTRY

PPAD

Prosthodontics • Periodontics • Endodontics • Research • Laboratory Considerations

A Peer-Reviewed Journal

VOLUME XIX

November/December 2007

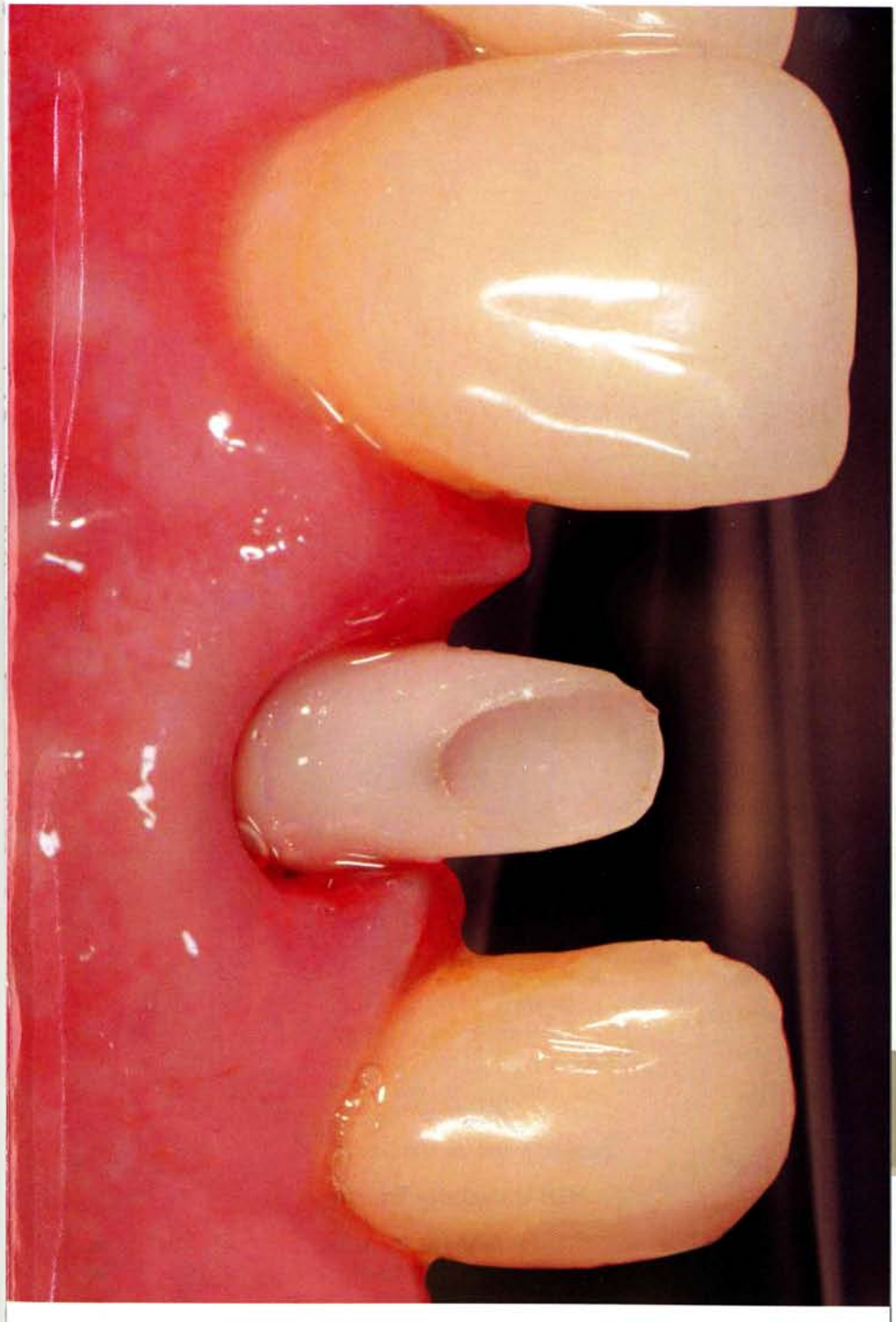

In this Issue:

- The Aesthetic Replacement of Mandibular Incisors Using an Implant-Supported Fixed Partial Denture with Gingival-Colored Ceramics
- Immediate Implant Placement and Provisionalization—Two Case Reports
- Decision-Making in Aesthetics: Root Coverage in Periradicular Surgery
- Aesthetic Full-Mouth Rehabilitation Using Prefabricated Endodontic Posts and Metal-Free Restorations
- Predictable Tissue Integration and Natural Aesthetics Using a Zirconia CAD/CAM Abutment and Crowns
- Subjects to be Considered in Ni-Ti Rotary Instrumentation
- The Benefits of Adjunct Chemo-Mechanical Therapy in the Treatment of Periodontal Disease

In This Issue

Improving Practice Profitability Using Online Communication Tools



A Montage Media Publication

www.PPAD.com

IMMEDIATE IMPLANT PLACEMENT AND PROVISIONALIZATION—TWO CASE REPORTS

Stuart J. Froum, DDS* • Sang-Choon Cho, DDS† • Helena Francisco, DDS‡ • Young-Sang Park, DMD§
Nicolas Elian, DDS‖ • Dennis P. Tarnow, DDS**



Endosseous dental implants have traditionally been placed using a two-stage surgical procedure with a 6- to 12-month healing period following tooth extraction. In order to decrease healing time, protocols were introduced that included immediate implant placement and provisionalization following tooth extraction. Although survival rates for this technique are high, postoperative gingival shrinkage and bone resorption in the aesthetic zone are potential limitations. The two case reports described herein present a surgical technique for the preservation of anterior aesthetics that combines minimally invasive extraction, immediate implant placement, provisionalization, and the use of implants with a laser micro-grooved coronal design.

Learning Objectives:
This article describes the use of an immediate implant placement and provisionalization technique. Upon completing this exercise, the reader should:

- Be aware of the clinical implications associated with an immediate implant placement and provisionalization technique.
- Recognize the role of implant design on overall aesthetic and functional success.

Key Words: immediate implant placement, provisionalization, minimally invasive

**Clinical Professor, Department of Periodontology and Implant Dentistry, New York University College of Dentistry, New York, NY; private practice, New York, NY.*
†Assistant Clinical Professor, Department of Periodontology and Implant Dentistry, New York University College of Dentistry, New York, NY.
‡Resident, Department of Periodontology and Implant Dentistry, New York University College of Dentistry, New York, NY.
§Former Resident, Department of Periodontology and Implant Dentistry, New York University College of Dentistry, New York, NY.
‖Assistant Professor and Director, Department of Periodontology and Implant Dentistry, New York University College of Dentistry, New York, NY.
***Professor and Chair, Department of Periodontology and Implant Dentistry, New York University College of Dentistry, New York, NY; private practice, New York, NY.*
Dr. Stuart J. Froum, 17 West 54th Street, Suite 1C/D, New York, NY 10019
Tel: (212) 586-4209 • E-mail: dr.froum@verizon.net

Dental implants have been successfully used during the last 30 years to restore partially and fully edentulous patients.[1,2] Prior to implant placement, the traditional protocol recommended a six- to 12-month healing period for the alveolar bone following tooth extraction. In addition, a load-free healing period of three to six months was generally recommended for osseointegration to occur.[3,4]

In an attempt to decrease this nine- to 18-month healing time, protocols were developed that suggested the viability of implant placement immediately following tooth extraction. In this regard, there has been an increasing interest in implant insertion into a fresh extraction socket, because this procedure has been shown to be a predictable treatment modality.[5-8] The advantages of immediate versus delayed implant placement include a reduction in treatment time, fewer surgical interventions,[9,10] and a decrease in surgical trauma to the tissues at the implant site.[11-13]

Unpredictable gingival recession and crestal bone resorption are two disadvantages associated with immediate implant placement in the aesthetic zone. Continued bone and soft tissue loss may also cause the exposure of the implant surface, resulting in a compromised aesthetic outcome following implant placement.[14-16]

Immediate provisionalization of dental implants enables the patient to avoid the psychological and physical discomfort of wearing a removable interim prosthesis.[17] Critical factors for success of immediate restorations include: 1) initial implant stability; 2) elimination of macromovement of the implant during initial healing; and 3) complete removal of excess luting agents following provisional cementation.[18-20] With respect to soft tissue contours, the fixed provisional restoration facilitates contouring the gingival tissue from the narrow cylindrical implant to the gingival form of a tooth as the implant emerges from the sulcus. Thus, several authors have stated that it is easier to achieve optimal sulcular form with a fixed provisional prior to definitive restoration.[21]



Figure 1. Case 1. Preoperative radiograph of the hopeless maxillary right central incisor with external root resorption.



Figure 2. Preoperative appearance of tooth #8(11) with a buccal fistula at the apex of the tooth.

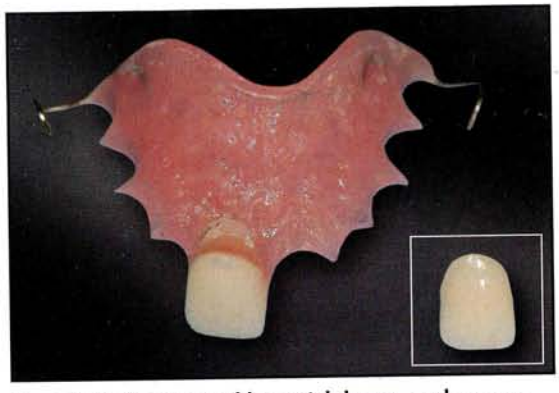

Figure 3. Both a removable partial denture and a crown form (inset) were prepared to provisionalize the area following tooth extraction.

The following case presentations demonstrate an immediate implant and provisionalization protocol that follows the biological parameters for three-dimensional implant placement, along with grafting of the gap between the buccal plate and the implant.[22] In both cases, implants with a laser micro-grooved gingival collar of 8 μm and 12 μm were used. These groove patterns have previously been shown in animal studies to selectively attach to soft and hard tissue, respectively.[23] The technique and implant design will be discussed, relative to implant success.

Case Presentations

Case 1

A 35-year-old non-smoking female patient in general good health and with no contraindications to treatment presented with a questionable maxillary right central incisor 10 years following traumatic injury. The discolored tooth exhibited external root resorption, Class II

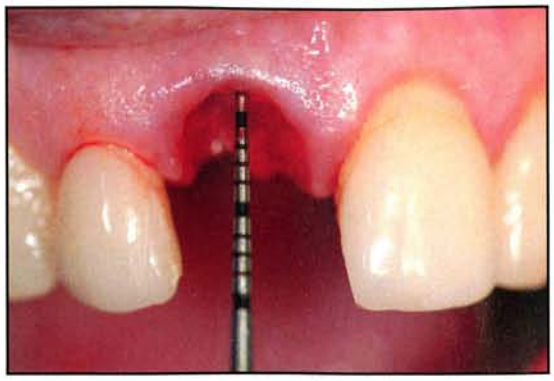

Figure 4. Atraumatic extraction of the right central incisor allowed the clinician to preserve the buccal plate and interdental papillae.

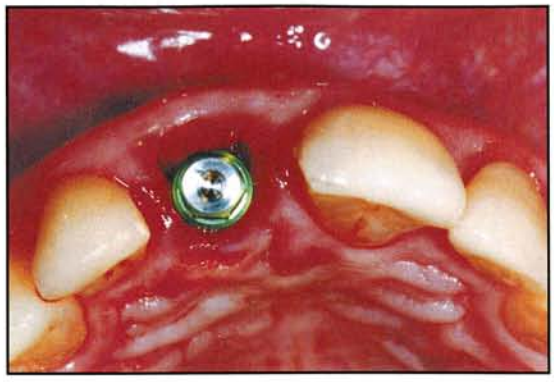

Figure 5. The implant was placed 3 mm from the buccal plate emerging toward the cingulum.

mobility, and was extruded (Figure 1). Clinical evaluation revealed a buccal fistula and exudate present at the apex of the tooth, and the tooth was diagnosed as hopeless (Figure 2). Treatment options were reviewed, and informed consent was obtained. Based on the patient's desire to reduce treatment time, it was decided to perform immediate implant placement with immediate provisionalization following tooth extraction.

A preliminary impression was made and diagnostic casts were fabricated with type IV dental stone (Die-keen, Heraeus Kulzer, Armonk, NY). A resin denture tooth with appropriate shape and shade was selected prior to tooth extraction. A removable partial denture was prepared in the event that the initial stability of the implant was insufficient to support a fixed provisional tooth (Figure 3).

Surgical Protocol

Following administration of local anesthesia (ie, lidocaine with epinephrine 1:100,000, Henry Schein Inc, Melville, NY), atraumatic tooth extraction was accomplished without flap reflection to preserve the interproximal papillae and the remaining buccal and lingual plates of bone (Figure 4). Following socket debridement, an implant (ei, 3.4 mm × 13 mm; Laser-Lok, BioHorizons, Birmingham, AL) was placed according to the manufacturer's protocol and with reference to three-dimensional positioning. The implant showed adequate initial stability when placed with a torque driver at 35 Ncm. It had a laser microgrooved collar, which was positioned with the 8-μm grooves in soft tissue and the 12-μm grooves in bone. The implant was placed 2 mm mesiodistally from the adjacent teeth, lingual to the buccal plate of the bone, toward the cingulum and with the implant abutment connection 3 mm apical to the anticipated gingival margin.[22] The latter was determined with a surgical template that denoted the apical extent of the anticipated buccal margin of the restoration. In this position, the implant had a distance of 3 mm between the implant and the buccal plate (Figure 5). A mineralized cancellous bone allograft (ie, Puros 0.25 g to 1 g, Zimmer Dental, Carlsbad, CA) was placed between the buccal plate of bone and the implant in order to fill the space and maintain the soft tissue contour. No attempt was made to advance the buccal flap to cover the graft material.

Immediate Provisionalization and Postoperative Care

A plastic cylinder was selected and prepared in order to receive the provisional restoration (Figure 6). The selected crown form (Bioform IPN, Dentsply Trubyte, York, PA) was relined intraorally with self-curing acrylic to ensure accurate fit and was cemented with temporary cement (Temp Bond, Kerr Corporation, Orange, CA). Centric and excursive contacts were eliminated and the patient was advised to avoid biting or chewing on the provisional crown. The patient was also instructed to rinse twice daily with 0.12% chlorhexidine and to avoid brushing the surgical area. The patient



Figure 6. A provisional abutment was prepared to facilitate placement of the provisional crown restoration.



Figure 7. Appearance of the provisional crown restoration in non-occlusion.

functioned with this provisional in non-occlusion for six months prior to delivery of the definitive implant restoration (Figure 7).

Restorative Phase and Follow-up Evaluation

Following six months of healing, the provisional crown was removed and the final ceramic abutment was torqued at 35 Ncm (Figure 8). An abutment-level impression was obtained, and the definitive all-ceramic restoration was delivered two weeks later. The definitive restoration was cemented with a provisional cement (ie, Temp Bond, Kerr Corporation, Orange, CA). The patient was examined at three, six, 12, 24, and 30 months post-cementation. The interproximal bone level showed no change from the time of implant insertion to 30 months post-loading (Figure 9). The buccogingival level also remained stable over this period of time. The gingival height on the implant restoration was more coronal than that on the original tooth prior to extraction and more coronal than the gingival buccal margin of central incisor adjacent to the implant restoration. Moreover, the height of the buccal gingival margin continued to remain at the same level more than 2.5 years post-loading (Figure 10).

Case 2

A 29-year-old non-smoking female patient in good general health presented with periodontal-involved maxillary central incisors and the absence of the right lateral incisor #7(12), which was removed 10 years previously. The patient had been functioning with a three-quarter chrome cobalt three-unit fixed partial denture (FPD) to replace the missing lateral incisor for seven years (Figure 11). Although no symptoms of active infection were evident during the clinical evaluation, the central incisors demonstrated advanced loss of osseous

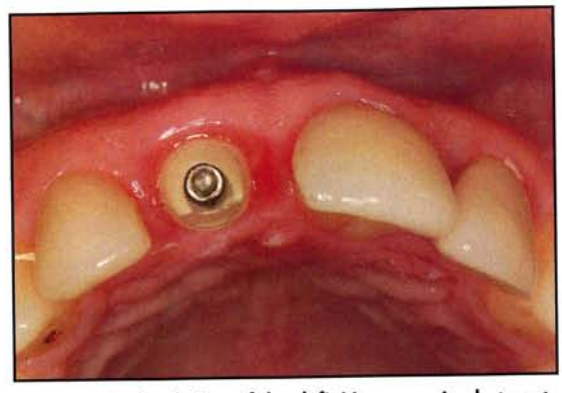

Figure 8. Occlusal view of the definitive ceramic abutment. Note the aesthetic contour of the buccal gingiva.

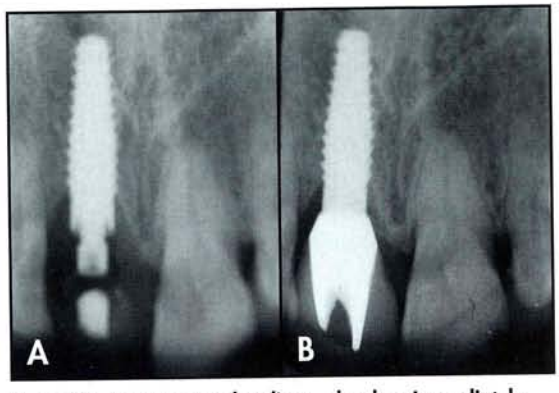

Figure 9A. Interproximal radiograph taken immediately following implant insertion. 9B. Radiographic appearance 2.5 years postoperatively. Note the maintenance of the interproximal bone levels.



Figure 10. Postoperative appearance 2.5 years following restoration. Note the gingival margin on the implant is more coronal than that on the adjacent natural incisor.

support, exhibited Class II and Class III mobility, and displayed external root resorption radiographically (Figure 12). The central incisors were diagnosed as hopeless and, with informed patient consent, were extracted (Figure 13). An immediate implant placement and immediate provisionalization technique was



Figure 11. Case 2. Preoperative appearance of the FPD from the right canine to the right central incisor.



Figure 12. Radiographic appearance of the three-unit FPD from the maxillary right canine to the right central incisor.



Figure 13. The FPD was removed to demonstrate Class II and Class III mobility of the central incisors.

selected. Ridge augmentation in the edentulous right lateral incisor area was also performed.

A preliminary impression was made, diagnostic casts were prepared, and a provisional restoration was fabricated for immediate provisionalization of implants #8(11) #9(21), and a cantilevered pontic on tooth #7.

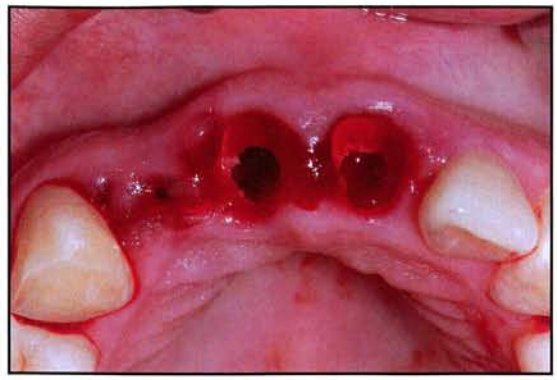

Figure 14. The central incisors were extracted without flap reflection to preserve the soft tissue around the socket.

Surgical Protocol

Local anesthesia (ie, lidocaine with epinephrine 1:100,000, Henry Schein Inc, Melville, NY) was administered and atraumatic extraction of the central incisor teeth was accomplished without flap reflection to preserve the interproximal papillae and the remaining buccal and lingual plates of bone (Figure 14). Following socket debridement, two implants (3.4 mm and 13 mm) with laser micro-grooved collars (ie, Laser-Lok, BioHorizons, Birmingham, AL) were placed at sites #8 and #9. No attempt was made for primary closure of the flap to cover the graft. All implants were guided by the surgical template into an ideal prosthetic position, and primary stability was achieved. The implants were placed 2 mm from the adjacent teeth, 3 mm between implants, and with the implant platform 2 mm to 3 mm apical to the anticipated gingival margin. The implants were also placed so that they emerged toward the cingulum of the anticipated restorations, leaving a distance of 3 mm to 4 mm between the implant and the buccal plate of bone. This space was filled with the mineralized cancellous bone allograft (MCBA) (Figure 15). During the surgical procedure, guided bone regeneration utilizing a graft of MCBA covered with an absorbable collagen membrane (ie, Bio-Gide, Geitstlich Biomaterials, Inc, Wolhusen, Switzerland) was performed to augment the edentulous #7 area adjacent to the #8 implant (Figure 16).

Immediate Provisionalization and Postoperative Care

The laboratory-fabricated provisional restorations were relined chairside with self-curing acrylic to ensure accurate fit and the three-unit splint was cemented with temporary cement (ie, Temp Bond, Kerr Corporation, Orange, CA). Centric and excursive contacts were removed, and the patient was advised to avoid biting or chewing on the crowns and to avoid brushing the surgical area.

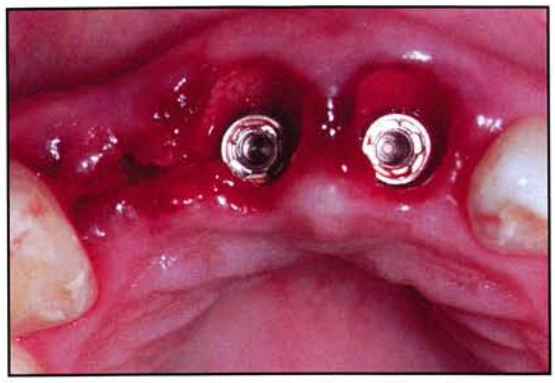

Figure 15. The implants were placed according to the concept of three-dimensional implant placement, leaving a distance of 3 mm between the implant and the buccal plate of bone.

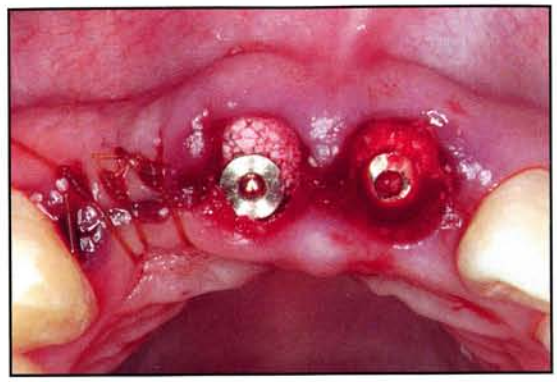

Figure 16. A mineralized cancellous bone allograft was placed buccal to the implants to fill the existing distance between the implants. A simultaneous ridge augmentation procedure was also performed.



Figure 17. Appearance of the provisional FPD was positioned with the cantilevered pontic to maintain papillary height for tooth #7(12), six months postoperatively.

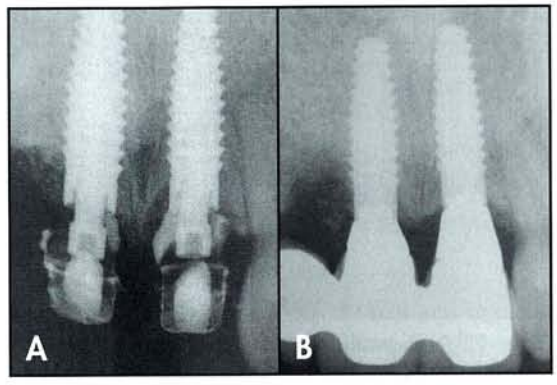

Figure 18A. Radiographic appearance of the implants immediately following placement. 18B. Postoperative appearance 2.5 years following implant loading.

The patient functioned with this provisional FPD in non-occlusion for six months prior to delivery of the definitive implant restoration (Figure 17).

Restorative Phase and Follow-Up Evaluation

Following six months of healing, the provisional FPD was removed and the final ceramic abutment torqued down with 35 Ncm. An abutment-level impression was performed and, two weeks later, the final all-ceramic crowns were delivered. For the purpose of achieving a natural aesthetic result, a cantilevered right lateral pontic was constructed instead of adding a third implant. The final restoration was cemented with temporary cement (ie, Temp Bond, Kerr Corporation, Orange, CA). The patient was re-examined at three, six, 12, 24 and 30 months post-cementation of the final prosthesis. During this period, the level of the interproximal bone and the buccal gingival level remained stable (Figures 18 and 19).

Discussion

The preservation of the hard and soft tissue complex in the aesthetic zone following the loss of one or more teeth presents a difficult challenge. Despite the high survival rates achieved with osseointegrated implants, the peri-implant soft and hard tissue response is the key to a successful aesthetic implant restoration.

Mid-facial gingival recession is the most common complication of anterior single-tooth implants. Small and Tarnow reported greater facial recession with wide-body implants.[24] It was speculated that this recession was caused by pressure against the buccal plate, causing resorption and consequent gingival recession. In the case reports presented in this article, the mid-buccal tissue remained undisturbed because the implant was placed 3 mm lingual to the buccal plate, and a graft was positioned to maintain the soft tissue contour. Placement of an immediate implant following extraction may or may not decrease the horizontal resorption of this buccal



Figure 19. Postoperative appearance 2.5 years following implant placement demonstrates aesthetic maintenance of the buccogingival marginal levels.

plate of bone.[25,26] Since the distance from the implant to the buccal plate of bone was greater than 2 mm in both cases presented, a decision was made to fill this void with MCBA. No controlled studies exist to determine what, if any, material is necessary to fill the space to achieve improved implant survival.[6] Histological evaluations in humans have, however, demonstrated that the horizontal component of the perio-implant defect around implants placed immediately following tooth extraction was "the most critical factor relating to the final amount of bone-to-implant contact."[27]

Moreover, it has been demonstrated in animals that the greater the distance, the more apical the formation of the bone-to-implant contact.[28] Therefore, with a distance greater than 2 mm present in the two cases reported, a graft material was indicated to support the buccal soft tissue complex during healing to achieve improved aesthetics. In both cases reported, there was no attempt to cover the graft with a membrane barrier and/or buccal flap. Bone augmentation techniques following immediate implant placement may not be required, if the distance between implant and bony wall is less than 2 mm, when implants with a rough surface are used.[29]

Very few studies have addressed the effect of using a graft or bone substitute alone to fill spaces greater than 2 mm without use of a barrier membrane. Various materials used to fill this gap have been described in reviews of the literature, but the authors concluded that they "could find no indication...as to the superiority of any of these components or their necessity with respect to immediate implantation."[5,6]

In this study, no attempt was made to advance the flap to cover the graft material. Advantages of this approach include the following: 1) the microgingival junction is not coronally displaced; 2) no sutures are needed; and 3) it serves to keep the epithelium of the flap away from the wound, allowing more time for connective tissue and bone to repopulate the space.

In the first case presentation, the interproximal papilla was not present one week postoperatively, but developed over a four-week period once the contact point was established. The papillae have remained intact 2.5 years post surgery. Following tooth removal, there is usually a collapse of the interproximal papilla due to loss of supracrestal gingival fibers. The papilla may be restored by restoration of the contact point of the implant-crown replacement, provided that distance of the bone crest on the adjacent tooth to contact point does not exceed 5 mm.[30,31] This response is, however, also affected by the peri-implant biotype because there is a greater peri-implant mucosal dimension in the presence of thick peri-implant biotypes compared to the thin biotype.[32]

Although the tooth in Case 1 had a thin scalloped biotype, proper implant placement and creation of a contact point within 5 mm of the crestal bone resulted in papillae maintenance. The buccal soft tissue level has been maintained even more coronal than on the tooth that was extracted. This buccal gingival level was also more coronal on the implant than the marginal gingival level on the natural left central incisor. The gingival margin on the implant has been stable for 2.5 years post crown placement. In Case 2, two adjacent implants were immediately placed and provisionalized. Because of the biological limitations of the papilla height between two adjacent implants (average 3.4 mm), aesthetics were even more challenging.[33]

In the cases presented, proper implant positioning was essential in achieving the desired aesthetic goals. In addition, the aim of the provisional restoration was to duplicate the natural tooth contour and mimic its contralateral natural tooth coronal to the free gingival margin. The shape of the provisional restoration with a reduced emergence profile allowed the soft tissue margin to remain in its coronal position. The final restoration was placed into a correctly contoured gingival sulcus. The use of implants with a laser microgrooved coronal design may have contributed to the maintenance of buccal soft tissue, providing attachment and preventing epithelial cell downgrowth, which often occurs with machined collar implants.[34] Maintenance of this supra crestal soft tissue often depends on its ability to establish an attachment supercrestally to the implant surface.

Conclusion

These two case reports describe a surgical technique that preserves anterior aesthetics by combining minimally invasive extraction, immediate three-dimensional implant placement, grafting of the buccal space with MCBA without primary coverage, immediate non-occluding provisionalization, and the use of implants with a laser micro-grooved coronal design.

In both cases presented, the gingival complex surrounding the implants has remained stable with no recession 2.5 years following crown placement. Additional prospective clinical and histological studies are, however, required to determine if this protocol using implants with different coronal designs and surface morphologies with and without grafting can maintain the soft and hard tissue levels over time.

Acknowledgment

The authors declare no financial interest in any of the products cited herein.

References

1. Adell R, Lekholm U, Rockler B, Brånemark PI. A 15-year study of osseointegrated implants in the treatment of the edentulous jaw. Int J Oral Surg 1981;10(6):387-416.
2. Adell R, Eriksson B, Lekholm U, et al. Long-term follow-up study of osseointegrated implants in the treatment of totally edentulous jaws. Int J Oral Maxillofac Impl 1990;5(4):347-359.
3. Albrektsson T, Brånemark P-I, Hansson HA, Lindstrom J. Osseointegrated titanium implants. Requirement for ensuring a long-lasting, direct bone-to-implant anchorage in man. Acta Orthop Scand 1981;52(2):155-170.
4. Brånemark PI, Zarb G, Albrektsson T. Tissue-integrated Prosthesis: Osseointegration in Clinical Dentistry. Chicago, IL: Quintessensce; 1985.
5. Schwartz-Arad D, Chaushu G. The ways and wherefores of immediate placement of implants into fresh extraction sites: A literature review. J Periodontol 1997;68(10):915-923.
6. Froum SJ. Immediate placement of implants into extraction sockets: Rationale, outcomes, technique. Alpha Omegan 2005;98(2):20-35.
7. Wagenberg B, Froum SJ. A retrospective study of 1925 consecutively placed immediate implants from 1988 to 2004. Int J Oral Maxillofac Impl 2006;21(1):71-80.
8. Grunder U, Polizzi G, Goene R, et al. A 3-year prospective multicenter follow-up report on the immediate and delayed-immediate placement of implants. Int J Oral Maxillofac Impl 1999;14(2):210-216.
9. Rosenquist B, Grenthe B. Immediate placement of implants into extraction sockets: Implant survival. Int J Oral Maxillofac Impl 1996;11(2):205–209.
10. Saadoun AP. Immediate implant placement and temporization in extraction and healing sites. Compend Contin Educ Dent 2002;23(4):309-326.
11. Lazzara RJ. Immediate implant placement into extraction sites: Surgical and restorative advantages. Int J Periodont Rest Dent 1989;9(5):332-343.
12. Parel SM, Triplett RG. Immediate fixture placement: A treatment planning alternative. Int J Oral Maxillofac Impl 1990;5(4):337-345.
13. Chen ST, Wilson TG Jr, Hämmerle CH. Immediate or early placement of implants following tooth extraction: Review of biologic basis, clinical procedures, and outcomes. Int J Oral Maxillofac Impl 2004;19(Suppl):12-25.
14. Schropp L, Isidor F, Kostopoulos L, Wenzel A. Patient experience of and satisfaction with, delayed-immediate vs. delayed single-tooth implant placement. Clin Oral Impl Res 2004;15(4):498-503.
15. Norton MR. A short-term clinical evaluation of immediately restored maxillary TiOblast single-tooth implants. Int J Oral Maxillofac Impl 2004;19(2):274-281.
16. Wöhrle PS. Single-tooth replacement in the aesthetic zone with immediate provisionalization: Fourteen consecutive case reports. Pract Periodont Aesthet Dent 1998;10(9):1107-1114.
17. Castellon P, Casadaban M, Block MS. Techniques to facilitate provisionalization of implant restorations. J Oral Maxillofac Surg 2005;63(9 Suppl 2):72-79.
18. Del Fabbro M, Testori T, Francetti L, et al. Systematic review of survival rates for immediately loaded dental implants. Int J Periodont Rest Dent 2006;26(3):249-263.
19. Gapski R, Wang HL, Mascarenhas P, Lang NP. Critical review of immediate implant loading. Clin Oral Impl Res 2003;14(5):515-527.
20. Ottoni JM, Oliveira ZF, Mansini R, Cabral AM. Correlation between placement torque and survival of single-tooth implants. Int J Oral Maxillofac Impl 2005;20(5):769-776.
21. De Kok IJ, Chang SS, Moriarty JD, Cooper LF. A retrospective analysis of peri-implant tissue responses at immediate load/provisionalized microthreaded implants. Int J Oral Maxillofac Impl 2006;21(3):405-412.
22. Grunder U, Gracis S, Capelli M. Influence of the 3-D bone-to-implant relationship on esthetics. Int J Periodont Rest Dent 2005;25(2):113-119.
23. Alexander H, Ricci JL, Hrico GJ. Mechanical basis for bone retention around dental implants. J Biomed Mater Res B Appl Biomater 2007 Apr 23;Epub ahead of print.
24. Small PN, Tarnow DP. Gingival recession around implants: A 1-year longitudinal prospective study. Int J Oral Maxillofac Impl 2000;15(4):527-532.
25. Covani U, Bontoraia C, Barone A, Shordone L. Bucco-lingual crestal bone changes after immediate and delayed implant placement. J Periodontol 2004;75(12):1605-1612.
26. Botticelli D, Berglundh T, Lindhe J. Hard-tissue alterations following immediate implant placement in extraction sites. J Clin Periodontol 2004;31(10):820-828.
27. Wilson Jr TG, Schenk R, Buser D, Cochrane D. Implants placed in immediate extraction sites: A report of histologic and histometric analysis of human biopsies. Int J Oral Maxillofac Impl 1998;13(3):333-341.
28. Akimoto K, Becker W, Persson R, et al. Evaluation of titanium implants placed into simulated extraction sockets: A study in dogs. Int J Oral Maxillofac Impl 1999;14(3):351-360.
29. Paoltonio M, Dolci M, Scarano A, et al. Immediate implantation in fresh extraction sockets. A controlled clinical and histological study in man. J Periodontol 2001;72(11):1560-1571.
30. Salama H, Salama MA, Garber D, Adar P. The interproximal height of bone: A guidepost to predictable aesthetic strategies and soft tissue contours in anterior tooth replacement. Pract Periodont Aesthet Dent 1998;10(9):1131-1141.
31. Grunder U. Stability of the Mucosal Topography Around Single-Tooth Implants and Adjacent Teeth: 1-Year Results. Int J Periodont Rest Dent 2000;20(1):11-17.
32. Kan JY, Rungcharassaeng K, Umezu K, Kois JC. Dimensions of peri-implant mucosa: An evaluation of maxillary anterior single implants in humans. J Periodontol 2003;74(4):557-562.
33. Tarnow D, Elian N, Fletcher P, et al. The vertical distance from the crest of bone to the height of the interproximal papilla between adjacent implants. J Periodontol 2003;74(12):1785-1788.
34. Simon JL, Heair J, Khanna Y, et al. The effects of laser microtextured collards upon crestal bone levels of dental implants. Presented at the 29th Meeting of The Society for Biomaterials, Apr.30 – May 3 2003, Reno NV. Submitted for Publication.