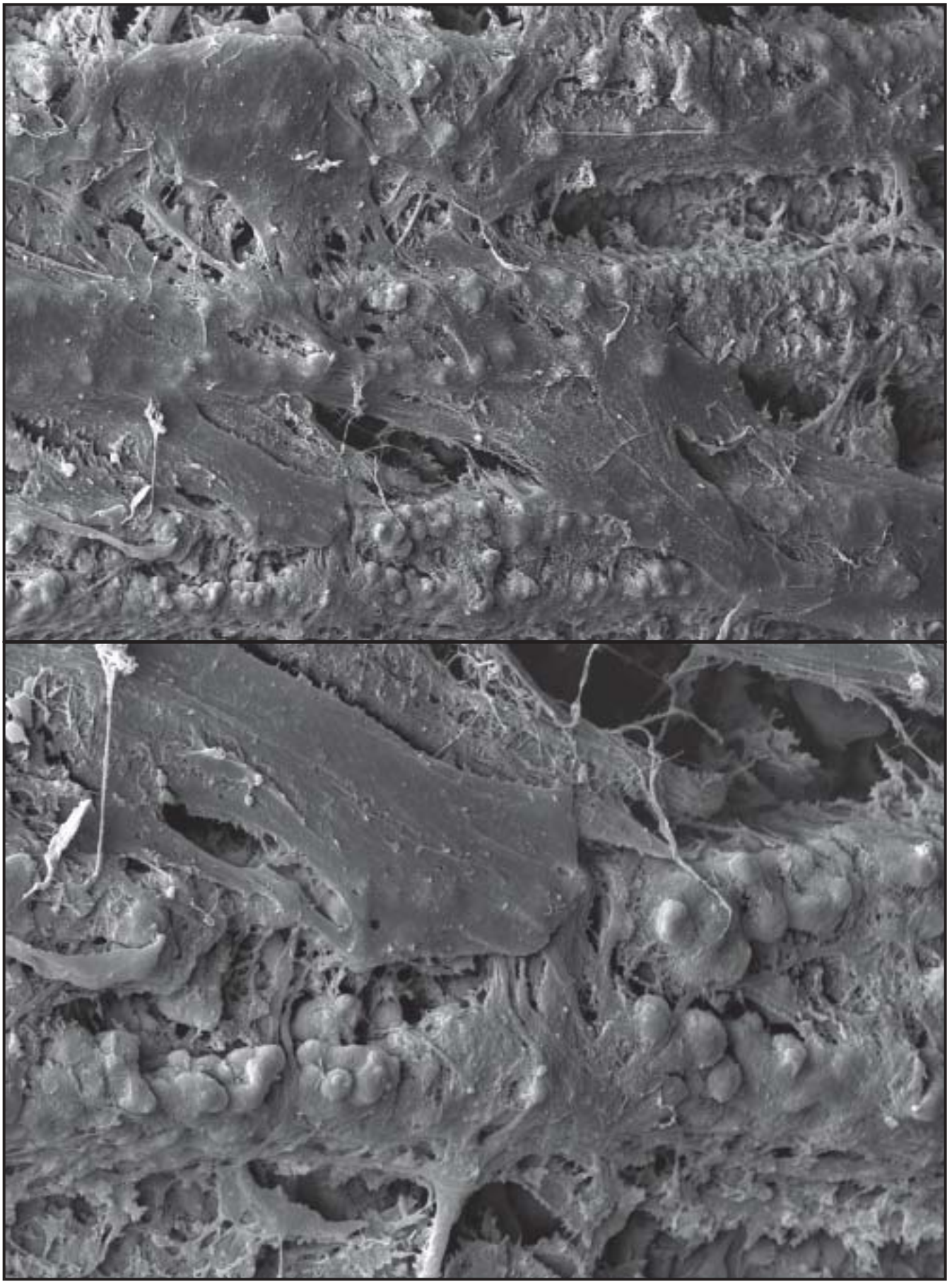

COPYRIGHT © 2008 BY QUINTESSENCE PUBLISHING CO, INC. PRINTING OF THIS DOCUMENT IS RESTRICTED TO PERSONAL USE ONLY. NO PART OF THIS ARTICLE MAY BE REPRODUCED OR TRANSMITTED IN ANY FORM WITHOUT WRITTEN PERMISSION FROM THE PUBLISHER

Human Histologic Evidence of a Connective Tissue Attachment to a Dental Implant



Myron Nevins, DDS[1]
Marc L. Nevins, DMD, MMSc[2]
Marcelo Camelo, DDS[3]
Janie Lee Boyesen, DDS, DMSc[4]
David M. Kim, DDS, DMSc[5]

This human proof-of-principle study was designed to investigate the possibility of achieving a physical connective tissue attachment to the Laser-Lok microchannel collar of a dental implant. Its 2-mm collar has been micromachined to encourage bone and connective tissue attachment while preventing apical migration of the epithelium. Implants were harvested with the surrounding implant soft and hard tissues after 6 months. The histologic investigation was conducted with light microscopy, polarized light, and scanning electron microscopy. (Int J Periodontics Restorative Dent 2008;28:111–121.)

[1]Clinical Associate Professor of Periodontics, Harvard School of Dental Medicine, Boston, Massachusetts.
[2]Clinical Assistant Professor of Periodontics, Harvard School of Dental Medicine, Boston, Massachusetts.
[3]Director, Brazil Institute for Dental Studies, Belo Horizonte, Brazil.
[4]Private Practice, Littleton, Colorado.
[5]Instructor, Department of Oral Medicine, Infection, and Immunity, Harvard School of Dental Medicine, Boston, Massachusetts.

Correspondence to: Dr Myron Nevins, Perio Implant Research Inc, 19970 Sawgrass Lane, Boca Raton, FL 33434; e-mail: Nevinsperimp@aol.com.

Postrestorative bone levels surrounding dental implants are used as one of the criteria for evaluating implant success.[1,2] Previous evidence demonstrates that proximal bone levels are influenced by the location of the implant-abutment junction (IAJ) in relation to the alveolar crest and that the crestal levels are located approximately 1.5 to 2.0 mm below the IAJ at 1 year after implant restoration. The components and dimensions of the implant soft tissue attachment correlate with those of the natural dentition, with the exception being the lack of attachment of connective tissue fibers to the implant surface.[3–6]

This study was designed to evaluate whether the roughened surface of an osseointegrated titanium implant can be mechanically altered to result in physical attachment of the supracrestal connective tissue to the implant, emulating the attachment apparatus of a tooth. This supracrestal connective tissue attachment to the implant would prevent apical migration of the junctional epithelium and preserve the coronal level of bone.

This study also evaluated the question of whether it is possible to

COPYRIGHT © 2008 BY QUINTESSENCE PUBLISHING CO, INC. PRINTING OF THIS DOCUMENT IS RESTRICTED TO PERSONAL USE ONLY. NO PART OF THIS ARTICLE MAY BE REPRODUCED OR TRANSMITTED IN ANY FORM WITHOUT WRITTEN PERMISSION FROM THE PUBLISHER



Fig 1 *The Laser-Lok collar of a dental implant. The* red arrow *distinguishes the upper zone, which consists of 8-µm microchannels that are 6 µm deep, from the lower zone, which consists of 12-µm microchannels that are 12 µm deep.*

have a physical connective tissue attachment to the collar of a dental implant. Laser-Lok microchannels (BioHorizons) are formed by a computer-controlled laser ablation technique that creates a series of microgrooved surfaces to optimally control the orientation of attached cells. An implant with this collar has the potential to achieve a connective tissue attachment. If attachment is possible, these microgrooved surfaces would inhibit apical migration of the epithelial attachment and prevent the loss of crestal bone.[7]

The soft tissue attachment at an implant differs from that of the periodontium of a tooth in the orientation of the connective tissue attachment. The tooth demonstrates an attachment apparatus with Sharpey fibers embedded into the cementum and covering the root surface at an oblique angle, whereas implants have shown firm bundles of connective tissue fibers that parallel the implant surface.[8] This component of the biologic width is associated with the crestal position of the alveolar supporting bone.[4,9–11]

The prevailing contemporary evidence suggests a "die-back effect," or loss of crestal bone when a two-piece dental implant is placed. Preclinical trials using a dog model confirmed a 3-mm dimension of soft tissues and a 1-mm loss of crestal bone to accommodate a position for the connective tissue of the biologic width.[1–3,12] There is evidence of an inflammatory infiltrate (inflammatory connective tissue [ICT]) associated with the IAJ that drives the connective tissue element apically, resulting in bone loss.[12]

This human histologic project investigates the potential of creating a connective tissue attachment to an implant surface that would emulate that of a tooth. Samples were examined using light microscopy, scanning electron microscopy (SEM), and microcomputerized tomography (µCT).

Method and materials

Four patients were selected to test the hypothesis that implants with Laser-Lok microchannels would create a connective tissue attachment that would prevent apical migration of the junctional epithelium and prevent the "die-back effect" of crestal bone. All were presented with informed consent and would receive enough implants so that one could be harvested and the remaining implants would allow restoration of their dental arch.

Implant placement surgeries were performed under local anesthesia with an oral sedative. Traditional surgical room preparation was accompanied by standardized sterile procedures. Full-thickness flaps were reflected and the osteotomy sites were prepared with a conventional sequence of rotary instruments. Laser-Lok microchannels have two laser dimensions to encourage bone and soft tissue attachment, and every effort was made to deliver the implant so that the portion to receive the soft tissue attachment would be supracrestal at the mesial and distal interproximal levels. A visible line allows discrimination of the two surfaces (Fig 1). Realistically, not all bone surfaces are flat, and thus an individualized approach may be required. The healing abutments were delivered at the time of implant placement, immediately before flap closure, so that the results could be compared to existing preclinical and clinical data.

The patients were monitored at 1, 2, 3, 4, 8, 12, and 24 weeks for supragingival plaque removal and oral hygiene instruction. At 6 months, the implants were harvested en bloc together with the adjacent soft and hard tissues so as to preserve the soft tissue attachment and the ability to identify the biologic width. The specimens were placed in an appropriate preservative and delivered for histologic preparation and analysis.

COPYRIGHT © 2008 BY QUINTESSENCE PUBLISHING CO, INC. PRINTING OF THIS DOCUMENT IS RESTRICTED TO PERSONAL USE ONLY. NO PART OF THIS ARTICLE MAY BE REPRODUCED OR TRANSMITTED IN ANY FORM WITHOUT WRITTEN PERMISSION FROM THE PUBLISHER



Fig 2 *SEM of the sulcular epithelium adjacent to the upper surface and the healing abutment. Note the desquamating cells at the level of the gingival margin* (red arrows). *Bar = 40 µm.*

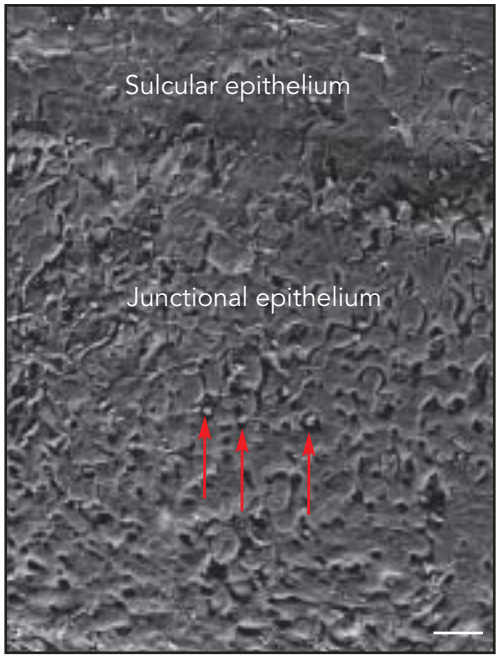

Fig 3 *SEM of the junctional epithelium. Note the neutrophils located between the cells* (red arrows). *Bar = 40 µm.*

Specimen preparation and analysis

Microcomputerized tomography

The specimens intended for µCT examination were fixed in 4% formaldehyde and scanned with a Scanco 40 µCT machine without dehydration or embedding. Approximately 600 horizontal scans per specimen were evaluated with Scanco software on the three-dimensional images and on images demonstrating bone-to-implant contact.

Light microscopy

The specimens were prepared for light microscopy as for nondemineralized ground sections.[13] Polymerized blocks were initially ground to bring the tissue components closer to the cutting surface. The final thickness of approximately 50 µm was achieved by grinding and final polishing according to methods described. Sections were stained with toluidine blue/Azur II.

Scanning electron microscopy

Specimens intended for SEM were dehydrated through a graded series of acetones and dried by the critical point method[14] using carbon dioxide as a transitory fluid. Specimens were examined in an SEM.

Results

The implants were osseointegrated with histologic evidence of direct bone contact. There was a connective tissue attachment to the Laser-Lok microchannels. There were no signs of inflammation. The peri-implant tissues consisted of a dense, collagenous lamina propria covered with a stratified, squamous, keratinizing oral epithelium. The latter was continuous with the parakeratinized sulcular epithelium that lined the lateral surface of the peri-implant sulcus (Fig 2). Apically, the sulcular epithelium overlapped the coronal border of the junctional epithelium (Fig 3). The sulcular epithelium was continuous with the junctional epithelium, which provided epithelial union between the implant and the surrounding peri-implant mucosa.[15–20] Between the apical termination of the junctional epithelium and the alveolar bone crest, connective tissue directly apposed the implant surface.

COPYRIGHT © 2008 BY QUINTESSENCE PUBLISHING CO, INC. PRINTING OF THIS DOCUMENT IS RESTRICTED TO PERSONAL USE ONLY. NO PART OF THIS ARTICLE MAY BE REPRODUCED OR TRANSMITTED IN ANY FORM WITHOUT WRITTEN PERMISSION FROM THE PUBLISHER



Fig 4 *Ground section of specimen stained with toluidine blue/Azur II.*

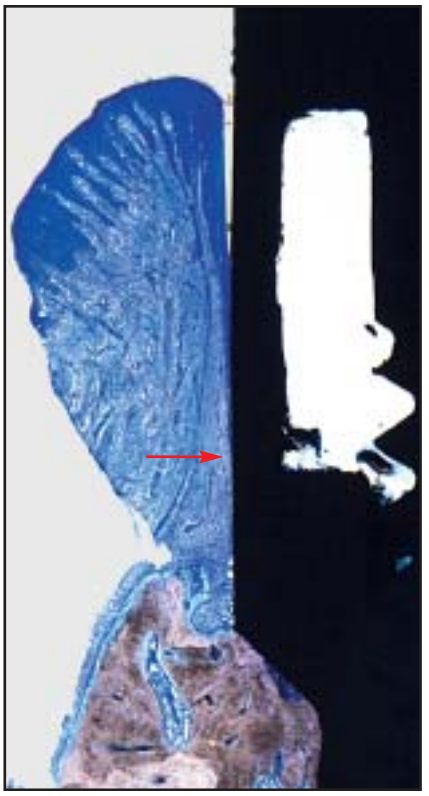



Figs 5a and 5b *Higher magnifications of Fig 4 showing the peri-implant tissues above the alveolar bone crest. Note the keratinized oral epithelium and the junctional epithelium tapering in the apical direction. The* red arrows *indicate the apical end of the junctional epithelium. The white gap between the junctional epithelium and the implant surface is an artifact created during histologic preparation. The implant surface between the apical extension of the functional epithelium and the alveolar bone is populated by a connective tissue attachment that can be oserved in Figs 8 to 10.*

Light microscopic evaluation of these specimens revealed intimate contact of the junctional epithelial cells with the implant surface (Figs 4 to 7). The microgrooved area of the implants was covered with connective tissue. Polarized light microscopy of this area revealed functionally oriented collagen fibers running toward the grooves of the implant surface (see Fig 7). SEM of a corresponding area of the specimen confirmed the presence of attached collagen fibers (Figs 8 to 10).

COPYRIGHT © 2008 BY QUINTESSENCE PUBLISHING CO, INC. PRINTING OF THIS DOCUMENT IS RESTRICTED TO PERSONAL USE ONLY. NO PART OF THIS ARTICLE MAY BE REPRODUCED OR TRANSMITTED IN ANY FORM WITHOUT WRITTEN PERMISSION FROM THE PUBLISHER

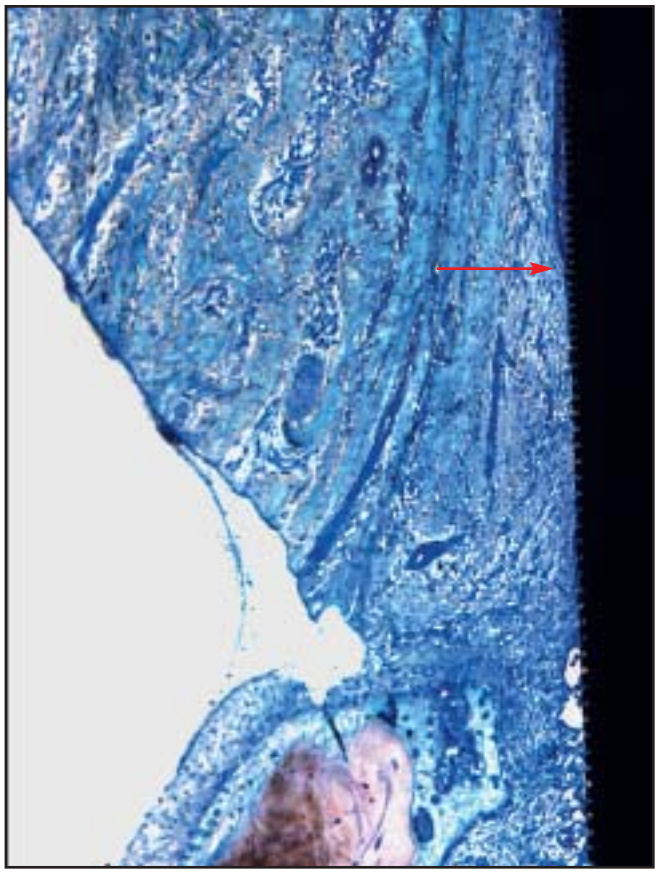

Fig 6 *Still higher magnification of Fig 4 identifies the apical extent of the junctional epithelium* (red arrow). *There is then a connective tissue attachment to the laser microchannel surface that extends to the point of bone attachment.*

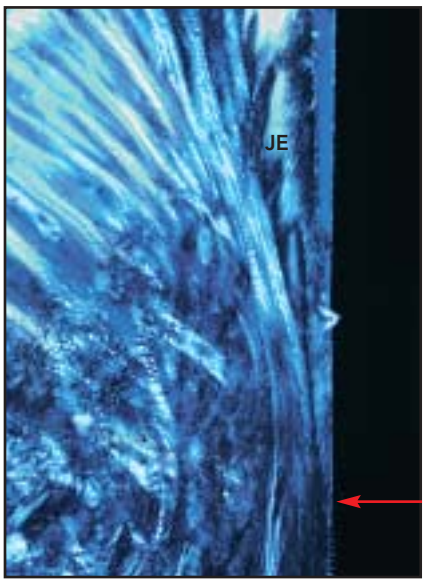

Fig 7a *Higher magnification of Fig 4 with polarized light showing the apical extent* (red arrow) *of the junctional epithelium (JE). Note the dense collagen fibers running apicocoronally.*

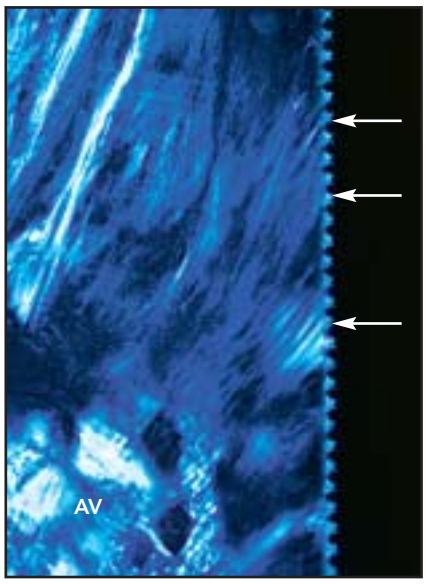

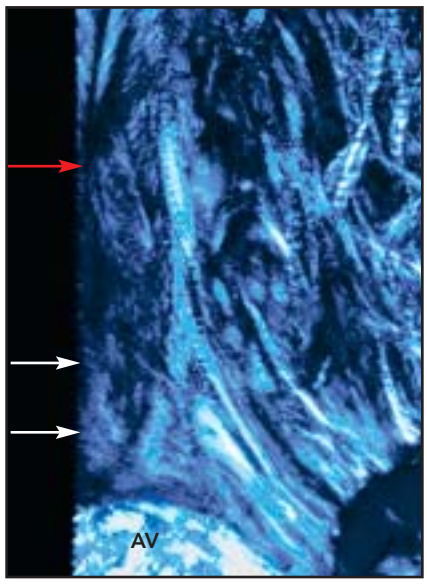

Figs 7b and 7c *View of the connective tissue in contact with the laser grooves (Fig 4 at higher magnification and with polarized light). Note the functional orientation of the collagen fibers toward the implant surface* (white arrows). *AV = alveolar bone crest;* red arrow = *apical extent of the junctional epithelium.*

COPYRIGHT © 2008 BY QUINTESSENCE PUBLISHING CO, INC. PRINTING OF THIS DOCUMENT IS RESTRICTED TO PERSONAL USE ONLY. NO PART OF THIS ARTICLE MAY BE REPRODUCED OR TRANSMITTED IN ANY FORM WITHOUT WRITTEN PERMISSION FROM THE PUBLISHER



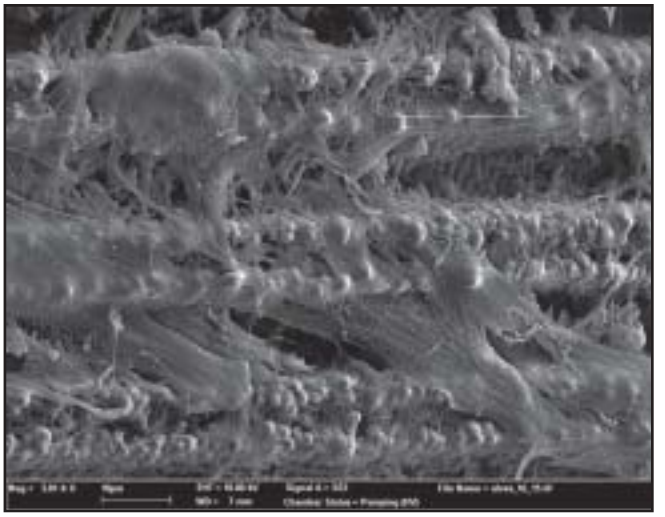

Figs 8a and 8b *SEMs showing collagen fibers attached to the rough implant surface (original magnification ×3.81).*



Fig 9 *Higher magnification of area shown in Figs 8a and 8b (original magnification ×9.51).*



Fig 10 *Area shown in Fig 9 at still higher magnification (original magnification ×22.77).*

All specimens demonstrated a high degree of bone-to-implant contact (Fig 11) and intense remodeling activity (Fig 12). In specimens that showed collagen fibers functionally oriented toward the grooves on the implant surface, remodeling of new bone in the coronal direction was observed (see Fig 12). SEM revealed sulcular epithelium with the desquamating activity of the cells and the junctional epithelium (see Figs 2 and 3). It appears that the connective tissue attachment is instrumental in preserving the alveolar bone crest and inhibiting apical migration of the epithelium.

COPYRIGHT © 2008 BY QUINTESSENCE PUBLISHING CO, INC. PRINTING OF THIS DOCUMENT IS RESTRICTED TO PERSONAL USE ONLY. NO PART OF THIS ARTICLE MAY BE REPRODUCED OR TRANSMITTED IN ANY FORM WITHOUT WRITTEN PERMISSION FROM THE PUBLISHER



Fig 11 (left) *μCT image showing an overview of osseointegration and the bone-to-implant contact (in red). Note that the level of bone contact extends to cover all threads of the implant and corresponds to the histologic observations. This supports the value of the connective tissue attachment to prevent loss of crestal bone.*

Fig 12 (right) *Ground section showing intimate osseointegration of this implant. Note the intense remodeling activity in the area of newly formed bone (NB). OB = local old bone.*

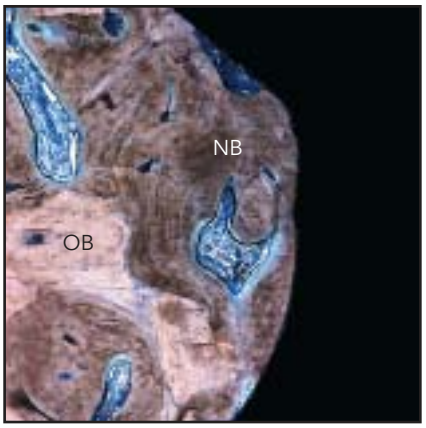

Discussion

This report presents human evidence via SEM and histology of a supracrestal connective tissue attachment to the Laser-Lok microchannels. This discussion focuses on two-piece dental implants, since that is descriptive of the implant system that was investigated. The question to be answered is whether a connective tissue attachment to the collar of the implant would prevent apical migration of the epithelial attachment and thereby inhibit the loss of crestal bone.

The soft tissue attachment around a natural tooth demonstrates supracrestal attachment of collagen fibers inserting into the surface of cementum (Sharpey fibers), with the junctional epithelium immediately occlusal to these fibers adhering to the tooth via hemidesmosomes. Goldman described the Sharpey fiber attachment to cementum as the physiologic factor that prevents the apical downgrowth of epithelium.[7] Observations of the biologic width in necroscopy samples[1] and the healing phenomenon after surgery challenge earlier thoughts of bone loss to accommodate a more apical location to populate new fibrous attachment to cementum.[8–10]

The supracrestal soft tissues adjacent to an osseointegrated dental implant include connective tissue and epithelium that is similar to that around a tooth, but the connective tissue differs in its orientation and attachment because of a lack of cementum to provide Sharpey fiber attachment. Because implants are exogenously introduced rather than developed along with the periodontal tissues, it is expected that the oral mucosal tissues adapt to the implant surface. Listgarten et al have illustrated that, because of the absence of the cementum layer, most fibers in the region of the supracrestal connective tissue–implant interface run in a direction parallel to the implant surface rather than being perpendicular and embedded.[4]

A mucosal barrier, or biologic width, exists around implants. Berglundh and Lindhe excised the connective tissue portion of the inside aspect of the flap during abutment connection.[12] The dimensions of the components of the soft tissue attachment from the microgap to the crestal bone correlated with the formation of the biologic width around the natural dentition, as established by Gargiulo et al, and the biologic width around implants is thought to be a physiologically formed structural unit.[8,12]

Hermann et al used a canine model to examine the influence of the location of the IAJ on the alveolar crest.[3] Two one-part and four two-part implants were used to examine both the effect of surgical technique (ie, one-stage versus two-stage) and the location of the rough/smooth interface. By placing the IAJ (microgap) of two-part implants in various apicocoronal positions relative to the bone crest, the authors found that the bone will remodel at the time of exposure to the oral environment so that the IAJ will be located approximately 2 mm below the bone crest. This demonstrated that the location of the IAJ in

COPYRIGHT © 2008 BY QUINTESSENCE PUBLISHING CO, INC. PRINTING OF THIS DOCUMENT IS RESTRICTED TO PERSONAL USE ONLY. NO PART OF THIS ARTICLE MAY BE REPRODUCED OR TRANSMITTED IN ANY FORM WITHOUT WRITTEN PERMISSION FROM THE PUBLISHER

relation to the alveolar crest has a direct effect on bone remodeling around implants and that remodeling is dependent on the time of exposure to the oral environment rather than on surgical technique (ie, one-stage versus two-stage). In one-part implants, the crestal bone followed the rough/smooth interface.

Ericsson et al demonstrated the presence of two distinct types of inflammatory infiltrates using a dog model that allowed plaque accumulation.[5] One type, the abutment ICT, was associated with the IAJ, where the area of the connective tissue that faced the IAJ consistently harbored an inflammatory cell infiltrate. This was about 1.5 mm high and 0.5 mm wide, and its apical border was about 1 mm from the alveolar bone crest. This resulted in the perceived need to create a mucosal seal around implants to protect the crestal bone from the oral environment.

The peri-implant mucosa surrounding implants is in many ways analogous to that surrounding the natural dentition.[3,12,21–28] A lamina propria extends from the alveolar bone coronally and is covered by keratinized oral epithelium. In healthy periodontium, a shallow sulcus forms that is lined by sulcular epithelium (see Fig 2). The junctional epithelium most closely matches the structures around a tooth (see Fig 3). A direct biologic attachment to the implant or abutment surfaces via a basal lamina and the formation of hemidesmosomes has been described for several implant materials.[29–31]

A clinical study conducted by Glauser et al[32] evaluated the peri-implant soft tissue barrier around experimental one-piece mini-implants in humans. The barrier was similar to that described in animal studies. A follow-up study[33] used combined light and transmission electron microscopy to show that the surface texture of implants may affect the orientation of collagen fibers of the connective tissue at the implant surface.

The Laser-Lok microchannels consist of precise, three-dimensional microstructures that are formed by a computer-controlled laser ablation technique. The explanation of this approach to soft and hard tissue around dental implants lies in the previous in vitro and in vivo studies that were used to develop laser-microgrooved surfaces. In a previous series of in vitro experiments, the effects of microgrooved substrates with features in the range of 2 to 12 μm were examined with respect to the attachment, spreading, orientation, and growth of fibroblast and osteoblast cell types.[14,34,35] The most important result to arise from these studies was the identification of an optimal series of microgrooved surfaces with groove widths and depths in the range of 6 to 12 μm. These surfaces were found to optimally control orientation of attached cells, prevent cell migration perpendicular to the microgrooves, and substantially inhibit fibroblast growth by inhibiting cell spreading. Specifically, 12-μm grooves showed the best potential for inhibition of fibrous tissue growth relative to bone cell growth, and 8-μm grooves showed the most effective inhibition of cell migration across the grooves, in effect acting as a migration barrier.

COPYRIGHT © 2008 BY QUINTESSENCE PUBLISHING CO, INC. PRINTING OF THIS DOCUMENT IS RESTRICTED TO PERSONAL USE ONLY. NO PART OF THIS ARTICLE MAY BE REPRODUCED OR TRANSMITTED IN ANY FORM WITHOUT WRITTEN PERMISSION FROM THE PUBLISHER

Other studies examined bone and soft tissue responses to these experimental surfaces as well as to blast-roughened surfaces of the same metal composition in a canine implantable chamber model.[13,36] The laser-microgrooved surfaces exhibited less fibrous encapsulation and more extensive bone integration than their blast-roughened counterparts, along with bone attachments that were oriented parallel to the microchannels. The surface microgrooves exhibited interdigitation with bone, resulting in a mechanical interlock, with strong resistance to tensile testing.

These in vitro and in vivo studies provide strong evidence that surface microtexturing can be used to control bone and soft tissue responses to implant surfaces. In the case of smooth implant surfaces, fibroblasts attach, spread, and proliferate readily, resulting in the establishment of a fibrous capsule that restricts bone formation.[20,21] Ridge-groove widths on the order of magnitude of the cells themselves guide cell migration and orientation. On dental implants, the microgrooved surfaces act to significantly restrict apical migration of gingival epithelial cells and fibroblasts, allowing the slower-growing osteoblasts and new bone tissue to reach the surface and establish attachment to the microtextured surface.

Conclusion

This paper addresses the topic of soft tissue attachment to osseointegrated implants. Contemporary evidence from preclinical trials has identified that the loss of 1.5 to 2 mm of the alveolar crest of bone is caused by the presence of an inflammatory infiltrate at the IAJ. This drives the connective tissue element of the biologic width apically, and bone loss occurs to accommodate its position as the supracrestal portion of the attachment apparatus.

One hypothesis as to how to interfere with this process would be to design the coronal portion of the implant to attract a physical connective tissue attachment that would inhibit epithelial downgrowth, establish a predetermined site for the connective tissue, and thus preserve the coronal level of bone.

This proof-of-principle investigation demonstrates that Laser-Lok microchannels can accomplish this goal with evidence of human histology. The supracrestal connective tissue attachment is evident when viewing ground sections stained with toluidine blue/AZUR II via light microscopy and when viewing sections through polarized light to confirm the oblique orientation of the fibers and is further confirmed with SEM examination.

Acknowledgment

This study was sponsored by a grant from BioHorizons Implant Systems, Inc.

COPYRIGHT © 2008 BY QUINTESSENCE PUBLISHING CO, INC. PRINTING OF THIS DOCUMENT IS RESTRICTED TO PERSONAL USE ONLY. NO PART OF THIS ARTICLE MAY BE REPRODUCED OR TRANSMITTED IN ANY FORM WITHOUT WRITTEN PERMISSION FROM THE PUBLISHER

References

1. Hermann JS, Cochran DL, Nummikoski PV, Buser D. Crestal bone changes around titanium implants. A radiographic evaluation of uploaded nonsubmerged and submerged implants in the canine mandible. J Periodontol 1997;68:1117–1130.
2. Hermann JS, Schoolfield JD, Nummikoski PV, Buser D, Schenk RK, Cochran DL. Crestal bone changes around titanium implants: A methodologic study comparing linear radiographic with histometric measurements. Int J Oral Maxillofac Implants 2001;16:475–485.
3. Hermann JS, Buser D, Schenk RK, Higginbottom FL, Cochran DL. Biologic width around titanium implants. A physiologically formed and stable dimension over time. Clin Oral Implants Res 2000; 11:1–11.
4. Listgarten MA, Lang NP, Schroeder HE, Schroeder A. Periodontal tissues and their counterparts around endosseous implants. Clin Oral Implants Res 1991 Jan–Mar; 2:1–19 [corrected and republished with original paging 1991;2(3):1–19].
5. Ericcson I, Persson LG, Berglundh T, Marinello CP, Lindhe J, Klinge B. Different types of inflammatory reactions in periimplant soft tissues. J Clin Periodontol 1995;22:255–261.
6. Abrahamsson I, Berglundh T, Lindhe J. Soft tissue response to plaque formation at different systems. A comparative study in the dog. Clin Oral Implants Res 1998;9: 73–79.
7. Goldman HM. The behavior of transseptal fibers in periodontal disease. J Dent Res 1957;36:249–254.
8. Gargiulo AW, Wentz FM, Orban B. Dimensions of the dentogingival junction in humans. J Periodontol 1969;32:261–267.
9. Oakley E, Rhyu IC, Karatzas S, Gandini-Santiago L, Nevins M, Caton J. Formation of the biologic width following crown lengthening in nonhuman primates. Int J Periodontics Restorative Dent 1999;19: 529–541.
10. Vercellotti T, Nevins ML, Kim DM, et al. Osseous response following resective therapy with Piezosurgery. Int J Periodontics Restorative Dent 2005;25:543–549.
11. Hartman GA, Cochran DL. Initial implant position determines the magnitude of crestal bone remodeling. J Periodontol 2004;75:572–577.
12. Berglundh T, Lindhe J. Dimension of the periimplant mucosa. Biological width revisited. J Clin Periodontol 1996;23:971–973.
13. Ricci JL, Charvet J, Frenkel SR, et al. Bone response to laser microtextured surfaces. In: Davies JE (ed). Bone Engineering. Toronto: Em Squared, 2000:282–294.
14. Soboyejo WO, Nemetski B, Allameh S, Marcantonio N, Mercer C, Ricci J. Interactions between MC3T3-El cells and textured Ti6A14V surfaces. J Biomed Mater Res 2002;62:57–52.
15. Luke D. The structure and functions of the dentogingival junction and periodontal ligament. Br Dent J 1992;172:187–190.
16. Schroeder HE, Listgarten MA. The gingival tissues: The architecture of periodontal protection. Periodontol 2000 1997;13: 91–120.
17. Ten Cate AR. The role of epithelium in the development, structure and function of the tissues of tooth support. Oral Dis 1996; 2:55–62.
18. Pollanen MT, Salonen JI, Uitto VJ. Structure and function of the tooth-epithelial interface in health and disease. Periodontol 2000 2003;31:12–31.
19. Bosshart DD, Lang NP. The junctional epithelium: From health to disease. J Dent Res 2005;84:9–20.
20. Salonen JI, Kautsky MB, Dale BA. Changes in cell phenotype during regeneration of junctional epithelium of human gingival in vitro. J Periodontal Res 1989;24:370–377.
21. Buser D, Weber HP, Donath K, Fiorellini JP, Paquette DW, Williams RC. Soft tissue reactions to non-submerged unloaded titanium implants in beagle dogs. J Periodontol 1992;63:225–235.

COPYRIGHT © 2008 BY QUINTESSENCE PUBLISHING CO, INC. PRINTING OF THIS DOCUMENT IS RESTRICTED TO PERSONAL USE ONLY. NO PART OF THIS ARTICLE MAY BE REPRODUCED OR TRANSMITTED IN ANY FORM WITHOUT WRITTEN PERMISSION FROM THE PUBLISHER

22. Abrahamsson I, Berglundh T, Lindhe J. Soft tissue response to plaque formation at different implant systems. A comparative study in the dog. Clin Oral Implants Res 1998;9:73–79 [erratum 1998;9:281].

23. Abrahmsson I, Berglundh T, Wennstrom J, Lindhe J. The periimplant hard and soft tissues at different implant systems. A comparative study in the dog. Clin Oral Implants Res 1996;7:212–219.

24. Berglundh T, Lindhe J, Ericsson I, Marinello CP, Liljenberg B, Thomsen P. The soft tissue barrier at implants and teeth. Clin Oral Implants Res 1991;2:81–90.

25. Jovanovic SA. Periimplant tissue response to pathological insults. Adv Dent Res 1999; 13:82–86.

26. Schierano G, Ramieri G, Cortese M, Aimetti M, Preti G. Organization of the connective tissue barrier around long-term loaded implant abutments in man. Clin Oral Implants Res 2002;13:460–464.

27. Siar CH, Toh CG, Romanos G, et al. Periimplant soft tissue integration of immediately loaded implants in the posterior macaque mandible: A histomorphometric study. J. Periodontol 2003;74:571–578.

28. James RA, Schultz RL. Hemidesmosomes and the adhesion of junctional epithelial cells to metal implants—A preliminary report. Oral Implantol 1974;4:294–302.

29. McKinney RV, Steflik DE, Koth DL. The epithelium–dental implant interface. J Oral Implantol 1988;8:622–637.

30. Listgarten MA, Lai CH. Ultrastructure of the intact interface between an endosseous epoxy resin dental implant and the host tissues. J Biol Buccale 1975;3:13–28.

31. Schupbach P, Hurzeler M, Grunder, U. Implant-tissue interfaces following treatment of periimplantitis using guided tissue regeneration: A light and electron microscopic study. Clin Oral Implants Res 1994; 5:55–65.

32. Glauser R, Schupbach P, Gottlow J, Hammerle CH. Periimplant soft tissue barrier at experimental one-piece mini-implants with different surface topography in humans: A light microscopic overview and histometric analysis. Clin Implant Dent Relat Res 2005;7(suppl 1): 44–51.

33. Schupbach P, Glauser R. The defense of the human periimplant mucosa: A histological study. J Prosthet Dent 2007;97: S15–S25.

34. Ricci JL, Grew JC, Alexander H. Connective-tissue response to defined biomaterial surfaces: Part I. Growth of rat fibroblast and bone marrow cell colonies on microgrooved substrates. J Biomed Mater Res A [epub ahead of print, 9 Aug 2007; DOI:10, 1002/jbm.a.31379].

35. Grew JC, Ricci JL, Alexander H. Connective-tissue responses to defined biomaterial surfaces. Part II. Behavior or rat and mouse fibroblasts cultured on microgrooved substrates. J Biomed Mater Res A [epub ahead of print, 9 Aug 2007; DOI: 10.1002/jbm.a.31378].

36. Frenkel SR, Simon J, Alexander H, Dennis M, Ricci JL. Osseointegration on metallic implant surfaces: Effects of microgeometry and growth factor treatment. J Biomed Mater Res Appl Biomater 2002;63: 706–713.

COPYRIGHT © 2008 BY QUINTESSENCE PUBLISHING CO, INC. PRINTING OF THIS DOCUMENT IS RESTRICTED TO PERSONAL USE ONLY. NO PART OF THIS ARTICLE MAY BE REPRODUCED OR TRANSMITTED IN ANY FORM WITHOUT WRITTEN PERMISSION FROM THE PUBLISHER